



Comparative Study Among Single Incision Laparoscopic Cholecystectomy and Conventional Laparoscopic Cholecystectomy

PARESH DESAI

3rd year resident, V.S. General hospital, SMT NHL MUNICIPAL MEDICAL COLLEGE, Ahmedabad

PRATIK PARKER

3rd year resident, V.S. General hospital, SMT NHL MUNICIPAL MEDICAL COLLEGE, Ahmedabad

DR.R.C.SHAH

Professor and head of department of general surgery, SMT NHL MUNICIPAL MEDICAL COLLEGE, Ahmedabad

ABSTRACT

BACKGROUND: To study and compare between single incision laparoscopic cholecystectomy and conventional laparoscopic cholecystectomy. **MATERIALS AND METHODS:** 50 patients of gall bladder disease in whom Single Incision Laparoscopic Cholecystectomy (SILC) and conventional laparoscopic cholecystectomy was conducted in the department of General Surgery at smt NHL municipal Medical College ahmedabad from November 2014 to October 2015. And all patients were divided in two groups. In Group 'A', 20 patients were included which were operated by Single Incision Laparoscopic Cholecystectomy (SILC) and in Group 'B', 30 patients were included which were operated by conventional laparoscopic cholecystectomy. And all the patients were assessed with Intra operative difficulties, Operative Time, Conversion rate from SILC to either Conventional laparoscopic surgery or Open surgery, Post operative pain, Post operative complications, Cosmetic outcome. **RESULTS:** Average operative time in Conventional laparoscopic cholecystectomy is 85 ± 9.733 SD minutes and in single incision laparoscopic cholecystectomy is 111.83 ± 20.53 SD minutes. Conversion rate is 20% in SILC and 3.33% in conventional cholecystectomy. Early post operative pain is more in conventional laparoscopic cholecystectomy than single incision laparoscopic cholecystectomy. 16 out of 20 (80%) patients was satisfy with single incision laparoscopic cholecystectomy according to likert scale and 4 patients of SILC were not satisfy due to wound infections. 3 out of 30 (10%) patients were satisfy with conventional laparoscopic cholecystectomy. Surgeon was satisfy with 18 out of 20 (90%) in SILC and 21 out of 30 (70%) in conventional surgery. Post operative wound related complications are more in single incision procedure than conventional surgery. **CONCLUSION:** Comparison between two procedures in my study concludes that single incision laparoscopic cholecystectomy is better with respect to post operative pain, cosmetic outcome than conventional laparoscopic cholecystectomy. But complication rate is more in single incision procedures due to incision length as well as Operative time and conversion rate is more in single incision procedures due to long learning curve and intra operative technical difficulties. But this learning curve difficulty will be overcome in nearby future with widely acceptance of minimally access surgery concept.

KEYWORDS : Single port laparoscopic cholecystectomy, Single incision laparoscopic surgery, Conventional cholecystectomy, Patient satisfaction score.

INTRODUCTION:

Minimally Invasive Surgery (MIS) is now established world over. From multi port laparoscopic surgery, the technique has progress to Single Incision Laparoscopic Surgery (SILS) or Single Port access. This novel technique or approach may be placed between the pure NOTES surgery, the hybrid NOTES surgery and the standard laparoscopic surgery, Laparoscopic Cholecystectomy is advantageous to the patients in terms of small wound size, lesser pain, better cosmesis, diminished wound infections and a more rapid recovery and return to work.

The new transumbilical approach seems to reduce the trauma of surgical access with its improvement of the postoperative pain and patient cosmesis compared to standard laparoscopic approach. However, other perform this novel technique. This new technique has been introduced to the surgical community and we have concentrated on

MATERIALS AND METHODS

50 patients of gall bladder disease in whom Single Incision Laparoscopic Cholecystectomy (SILC) and conventional laparoscopic cholecystectomy was conducted. In all cases a detail history, physical examination and investigations were done as per profoma.

After taking informed and written consent, patients were divided in two groups. In Group 'A', 20 patients were included which were operated by Single Incision Laparoscopic Cholecystectomy (SILC) and in Group 'B', 30 patients were included which were operated by conventional laparoscopic cholecystectomy.

Exclusion criteria

ASA (American Society of Anesthesiologist) GRADE MORE THAN II, Patients not giving consent for operation, Attacks of acute pancreatitis, Previous upper abdominal surgery.

Surgical procedure

All patients coming to the Surgical Out-Patient-Department (OPD) with benign Gall Bladder disease were admitted to surgical ward. For all patients undergoing laparoscopic cholecystectomy routine preoperative investigations and preparation were done. Patient was placed in supine position. Induction was achieved with General Anaesthesia. A transverse sub umbilical incision of around 1.5 - 2cm long was made extending through the subcutaneous fat up to the rectus sheath. Veress needle was inserted into the abdomen at 45° angle pointed towards the pelvis and the needle was swung from side to side to ensure that its movement was free and not restricted by adhesion. The 'saline drop test' and injection- aspiration of saline was done to confirm the needle tip in the peritoneal cavity. The gas insufflation tube was then attached to the needle hub and insufflation started at 1-2L/min. The gas pressure was allowed to build up to 12-14mmHg before introducing first blind 5mm trocar. It was inserted at 45° angle pointed towards pelvis and with a rotatory movement till the tip enters the peritoneum. A loss of resistance indicates entry into gas filled peritoneal cavity. The telescope of 30° degree was now inserted to view the peritoneal cavity and the CO₂ gas tube from the insufflator was connected to the gas inlet cork. Insertion of another 10mm port and 5mm port through same skin incision but different fascial incision. The fundus of the gall bladder was held and retracted cranially and adhesions separated from the gall bladder working against the counter traction of the left hand instrument. Starting at the area closest to the fundus the adhesions were gradually separated. This was proceeded till the entire body of gall bladder was freed of all adhesions. Further dissection was commenced by division of the peritoneal fold between Hartman's pouch and liver like conventional laparoscopic cholecystectomy. A posterior window was created at the GB - cystic duct junction and continued medially clearing cystic duct. Next anterior dissection was started and the cystic duct cleared. The cystic artery was identified and both the structures were skeletonised.

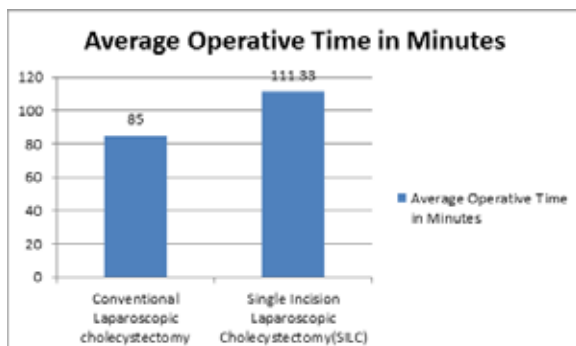
from the common hepatic duct and the branch of cystic artery to the cystic duct was identified and divided. The dissected cystic duct and cystic artery were clip occluded – two on the body side and one at the neck of the gall bladder and duct divided close to the clip on the specimen side. The artery was similarly divided. With the cystic duct and cystic artery divided, traction was applied at the left hand at the neck of the gall bladder and GB was dissected off the liver bed. The dissection was started at the neck and worked towards the fundus using either sharp division or with hook. The final fundus connection was undivided and gall bladder was used for traction to examine the liver bed for any bleeding which was then coagulated. Once the gall bladder was completely freed, a grasping forceps was introduced through the 10mm port and neck of the GB was grasped and was drawn to the port sheath. The GB neck was drawn into port and was gradually extracted from the abdominal cavity with the gall bladder. The GB neck was grasped on its coming out, stone extracted with forceps and GB was extracted using firm rotatory movement. Any prolapsing bowel or omentum was carefully reduced and the sheath and skin were sutured.

RESULTS

A Comparative study of 50 patients of gall bladder disease in whom Single Incision Laparoscopic Cholecystectomy (SILC) and conventional laparoscopic cholecystectomy was conducted in the department of General Surgery at SMT NHL municipal Medical College ahmedabad from November 2014 to October 2015. Continuous data between the two groups were recorded as

Mean \pm Standard deviation. P value <0.05 was considered statistically significant.

Fig 1: average operative time



It denotes that time in conventional procedure is less than newer single incision procedure. The operative time shows long curve and it shows that long practice needs to perform this procedure in less time. So learning curve is long in this procedure and large patients require to comment learning curve with this procedure. To compare the mean difference between two groups, independent t-test was used and its p-value was obtained. P-value was less than 0.01 concludes that there is significant difference in mean operative time between two groups of patients.

2. Conversion rate

Type of Procedure	Conversion rate (%)
Conventional Laparoscopic cholecystectomy	3.33
Single Incision Laparoscopic Cholecystectomy (SILC)	20

In conventional lap.cholecystectomy out of 30 cases, 1 case was converted to open cholecystectomy due to severe adhesions at Calot's triangle found intra operatively. In SILC out of 20 cases, 4 cases require conventional laparoscopic cholecystectomy due to severe adhesions at Calot's triangle found intra operatively and intra operative technical difficulties. Conversion rate is 20% in SILC and 3.33% in conventional cholecystectomy. So this finding suggests that learning of newer procedure needs practice and familiarity of newer instrument. Post operative pain (VAS) over the period of time (post ope.). Mean VAS with SD for each time period is given in below table. There is significant difference in VAS scores between two groups (p-value < 0.001).

3. Post operative pain

VAS	Group	Mean	Standard Deviation	Number of patients
Post Ope.	Group-A	5.2000	1.00525	20
	Group-B	6.9333	.90719	30
06 hrs	Group-A	2.7500	.71635	20
	Group-B	4.4333	.77385	30
12 hrs	Group-A	2.0000	.64889	20
	Group-B	3.1667	.74664	30
24 hrs	Group-A	1.3000	.65695	20
	Group-B	2.0667	.69149	30
48 hrs	Group-A	.4000	.50262	20
	Group-B	.6333	.61495	30

4. Cosmetic outcome :

In present study, after 1 month follow up patients underwent single incision laparoscopic cholecystectomy are satisfied cosmetically except those developed complications like wound seroma and wound infection. 16 out of 20 (80%) patients were satisfied with single incision laparoscopic cholecystectomy according to Likert scale and 4 patients of SILC were not satisfied due to wound infections. 3 out of 30 (10%) patients were satisfied with conventional laparoscopic cholecystectomy. Surgeon was satisfied with 18 out of 20 (90%) in SILC and 21 out of 30 (70%) in conventional surgery according to Modified Hollander cosmesis scale.

5. Complication rate:

Type of Procedure	Complication Rate			
	Wound infection	Wound seroma	Deep space infection	Intraoperative complication
Conventional Laparoscopic cholecystectomy (n=30)	1	1	0	0
Single Incision Laparoscopic cholecystectomy (n=20)	3	0	0	0

This study includes immediate complications like wound infection, wound seroma formation, etc. The umbilical incision length of single incision procedure is more than that of conventional procedure. So wound complications are more in single incision procedure than conventional surgery. I have taken one month follow up of all patients after operation.

DISCUSSION

(1) Conversion Rate

- **Jose Erbella Jr et al (2009)** performed in USA. SILS was performed for 100 consecutive outpatients needing cholecystectomy and were followed postoperatively for at least 6 months. Out of the 100 patients, 98 underwent SIMPL cholecystectomy and 2 required conversion to the standard laparoscopic technique because of bleeding from the cystic artery. No major postoperative complications occurred. It is an excellent alternative to traditional three- or four-port cholecystectomy for the ideal candidate with a lower body mass index (BMI), early disease, and no previous abdominal surgery.
- **In Present Study**, total 50 patients are included from November 2014 to October 2015 and follow up for 1 month, out of 50 patients 20 undergo SILC in which 4 require conversion to conventional surgery due to severe adhesions and instrumental difficulties. No major post operative complications except wound seroma in 2 patients of SILC.

(2) Operative Time

- **K. Thompson et al (2009)** performed at USA in 2009. A 39-year-old woman was enrolled to undergo SILS. Substitution of the flexible endoscope for the standard laparoscope allows many greater degrees of visualization in SILS. This allows clear identification of the biliary ductal anatomy, allowing cholecystectomy to proceed safely. The operative time was 58 min, with minimal blood loss recorded. The patient was discharged home on the day of the procedure and did not experience any postoperative complications.

- **In Present Study**, total 50 patients are include from November 2014 to October 2015. Out of 20 patients of SILC. The average operative time in SILC is 111.83 ± 20.53 SD mins without any intra operative complications and all patients are discharge on 1st or 2nd post operative day . During 1 month follow up, 3 patients have wound infections postoperatively.

(3) Post Operative Pain:

- **Evangelos C. Tsimoyiannis et al (2009)** performed at greece in 2009. Forty patients were randomly assigned to two groups. In group A (n =20) four-port classic laparoscopic cholecystectomy was performed. Patients in group B (n = 20) underwent SILS cholecystectomy. In all patients, the results were significantly lower pain scores were observed in the SILS group versus the classic laparoscopic cholecystectomy group after the first 12 h for abdominal pain, and after the first 6 h for shoulder pain. Total pain after the first 24 h was nonexistent in the SILS group. Also, requests for analgesics were significantly less in the SILS group, while no difference was observed in incidence of nausea and vomiting between the two groups. SILS cholecystectomy has significantly lower abdominal and shoulder pain scores, especially after the first 24 h postoperatively when this pain is nonexistent as well as the invisible scar.
- **In Present Study**, fifty patients (33 women and 17 men) are divide into two groups. In group A(n = 30) four-port classic laparoscopic cholecystectomy is perform. Patients in group B (n = 20) undergo SILC. No pre incisional local infiltration to any of the study patient. Significantly lower pain scores are observe in the SILC group than the classic laparoscopic cholecystectomy group with 3 patients have wound infections postoperatively.

(4) Cosmetic Outcome

- **Marks J, Tacchino R, et al (2011)** performed at Cleveland and the results were cosmetic scores at 1, 2, 4, and 12 weeks were significantly higher for SILC. Satisfaction scores were similar although both groups reported a significantly higher preference towards SILC.
- **In Present Study**, Patient and surgeon Satisfaction scores are higher preference towards SILC (80%) with 3 patients of SILC have wound infections postoperatively.

REFERENCES

- Erbella J, Gary MB (2010) 'Single-incision laparoscopic cholecystectomy: the first 100 outpatients', *Surg. Endosc* 24:1958-1961. 2) Thompson K, Spivack A, Fischer L, Wong B, Jacobsen G, Talamini M, Horgan S (2011) 'Single-incision laparoscopic cholecystectomy', *Surg Endosc* 25:1664. 3) Evangelos CT, Konstantinos ET, George PG, Charalampos F, Nikolaos B, Paraskevi MA(2010) 'Different pain scores in single transumbilical incision laparoscopic cholecystectomy versus classic laparoscopic cholecystectomy: a randomized controlled trial' *Surg. Endosc* 24: 1842-1848. 4) Mehmood Z, Subhan A, Nasir A, Rasul S, Mazhar I, Khan R, Muhammad TK, Muhammad S, Mirza SB(July - September 2010) 'Four port versus single incision laparoscopic cholecystectomy', *Journal of Surgery Pakistan (International)* 15 (3). 5) Wong JS, Cheung YS, Chan KW, Charing CN, Chong KF, Wong J, Paul BS (2011) 'Single Incision Laparoscopic Cholecystectomy', *Hong Kong Med J*, 17, 465-8. 6) Marks J, Tacchino R, Roberts K, Onders R, Denoto G, Paraskeva P, Rivas H, Soper N, Rosemurgy A, Shah S(2011) 'Prospective randomized controlled trial of traditional laparoscopic cholecystectomy versus single-incision laparoscopic cholecystectomy: report of preliminary data', *Am J Surg.*(3):369-72. 7) Sharma A, Soni V, Bajjal M, Khullar R, Najma K, Chowbey PK(March- April 2013) 'Single ort versus multiple port laproscopic cholecystectomy: A comparative study', *Indian J Surg* 75(2): 115-122. 8) Muhammad AM, Jamil K, Moustafa M, Abdulmajid A(2012) 'Single incision vs. conventional multiport laparoscopic cholecystectomy: A comparison of two approache', *International Journal of Surgery*; 10(7):368. 9) Norman SW, Christopher JK, Bulstrode & P.Ronan O'connell (2013) *Bailey & Love's Short Practice of Surgery*, 26 edn., : 67:1097-98 & 1104. 10) Prasad A, Mukherjee KA, Kaul S, Kaur M, Minim J(Jan-Mar 2011) 'Postoperative pain after cholecystectomy: Conventional laparoscopy versus single-incision laparoscopic surgery', *Access Surg.* ; 7(1): 24-27. 11) Antonios V, George P(2010) 'A Randomised Comparison Between Single Incision Laparoscopic Cholecystectomy and Standard Laparoscopic Cholecystectomy', *University of Athens*. 12) Kevin K, Kay Y(2011) 'Single incision laparoscopic cholecystectomy', *Surgical Practice College of Surgeons of Hong Kong* 15, 64-65. 13) Yasumitsu H, Watanabe T, Uchida T, Yoshida S, Hideaki K(2010 January 14) 'Single-incision laparoscopic cholecystectomy: Single institution experience and literature review', *World J Gastroenterology*; 16(2): 270-274. 14) Eun JK, Soon HY, Yang HB, Young HR, Hong JC, Young HK, Ghap JJ(2012 March) 'The "invisible cholecystectomy": a transumbilical laparoscopic operation without a scar', *J Korean Surg Soc.* ; 82(3): 179-184. 15) Gangl O, Hofer W, Tomaselli F, Sautner T, Függer R(2011 Aug) 'Single incision laparoscopic cholecystectomy (SILC) versus laparoscopic cholecystectomy (LC)-a matched pair analysis', *Arch Surg.*;396(6):819-24.