

## A Case Report of Fournier's Gangrene.

Dr. Sachin Y.  
Sardeshpande

Assistant Professor in the Dept. of Surgery, GMC, Chandrapur.

Dr. Pranay Gandhi medical officer, civil hospital, Chandrapur.

**ABSTRACT**

*Fournier's gangrene is a condition marked by fulminant polymicrobial necrotizing fasciitis of the urogenital and perineal areas. We present a patient with Fournier's gangrene and describe the physical examination and bedside sonographic findings. These findings can assist in the evaluation of patients with concerning symptoms so there can be timely administration of antibiotics and specialist consultation when necessary.*

**KEYWORDS :** Fournier's gangrene, emergency department, ultrasonography

**Introduction:**

Fournier's gangrene is a condition marked by fulminant polymicrobial necrotizing fasciitis of the urogenital and perineal areas. A patient presented to the emergency department with symptoms concerning for this disease entity. We describe the physical examination and sonographic findings that ultimately led to the diagnosis and timely administration of antibiotics and specialist consultation.

**Case report:**

A 51-year-old male with a past medical history significant for hypertension and poorly controlled diabetes mellitus presented to the emergency department with a complaint of scrotal pain and swelling. His symptoms had started five days prior to presentation, but had progressed rapidly in the preceding twenty-four hours. The patient complained of associated fever, nausea and diaphoresis. Vital signs included a blood pressure of 87/53 mmHg, a heart rate of 118 beats per minute and a rectal temperature of 99.4°F. On physical examination, the patient had diffuse edema of the scrotum and penis with areas of skin discoloration (fig 1). Laboratory analysis revealed a blood glucose of 447 mg/dL (74-106 mg/dL), serum creatinine of 3.3 mg/dL (0.66 – 1.25 mg/dL), lactic acid of 3.8 mmol/L (0.7 – 2.1 mmol/L), and white blood cell count of 27.8 K/ $\mu$ L (3.8 – 9.8 K/ $\mu$ L). A bedside scrotal ultrasound was performed (fig 2). Based on the history, physical examination and these findings, a diagnosis of Fournier's gangrene was made. An emergent urology consultation was obtained and after evaluation, the patient was taken to the operating room for debridement of the scrotal and penile skin and soft tissues (fig 3). The patient underwent extensive debridement of the scrotum, testicles and degloving of the penis. The patient returned to the operating room three subsequent times for further debridement prior to reconstruction. He was discharged approximately one month after presentation with an excellent prognosis. Wound cultures and surgical specimens revealed acute inflammation and liquefactive necrosis associated with mixed bacterial flora, consistent with the diagnosis of Fournier's gangrene

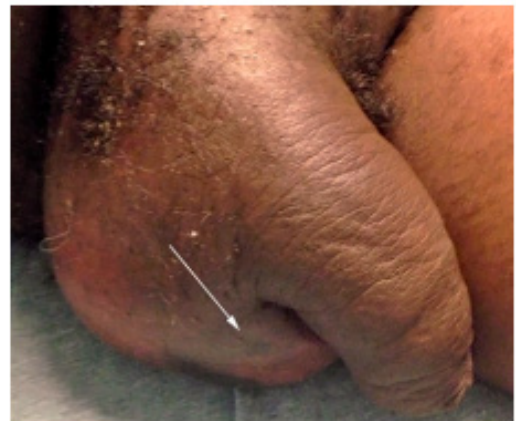**Discussions**

Fournier's gangrene is a condition marked by fulminant polymicrobial necrotizing fasciitis of the urogenital and perineal areas. The early administration of antibiotics and emergency operative treatment are essential; however, despite advancements in diagnostic modalities and intensive care management, mortality can still approach 67%. [1] On presentation, patients may complain of scrotal discomfort, pruritis, and/or swelling with systemic complaints such as fever, chills, and myalgias. Physical examination can include extreme pain to palpation, skin discoloration, edema, blistering, and crepitus [2]. Bedside ultrasonography may demonstrate findings suggestive of cellulitis or abscess. There may be diffuse thickening of the subcutaneous tissue with a layer of fluid accumulation at least 4 mm in depth along the deep facial layer [3]. Ultrasound has demonstrated a sensitivity of 88.2% and a specificity of 93.3% for diagnosing clinically suspected necrotizing fasciitis using these criteria, and 100% sensitivity in the detection of soft tissue air in cadaveric studies [4,5]. With gas-forming organisms, there may be a loss of tissue planes from subcutaneous air

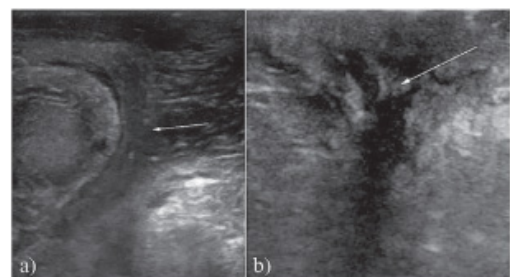
[6].

**Conclusion:**

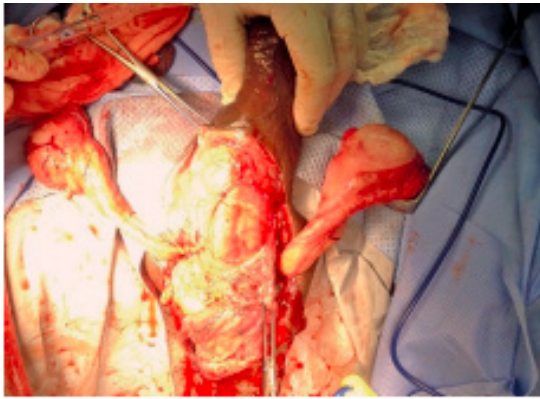
These physical examination and sonographic findings can assist in the evaluation of patients with concerning symptoms for Fournier's gangrene so there can be timely administration of antibiotics and specialist consultation when necessary.

**Figures:**

**Fig 1.** Image of the patient's penis and scrotum demonstrating significant soft tissue swelling and an area of skin discoloration (arrow) of the inferior left scrotum.



**Fig 2.** a) 2-D Ultrasound of the testicles in the transverse plane. Edematous scrotal skin is evident (arrow) by hypoechoic tissue overlying the testicle; b) 2-D Ultrasound image of the left scrotum in the sagittal plane. A heterogeneous hypoechoic area with irregular borders (arrow) suggests tissue edema, fluid and gas.



**Fig 3.** Intraoperative photograph after extensive debridement of the scrotum, pelvic fascia, and penis

## REFERENCES

1. Corman JM, Moody JA, Aronson WJ. Fournier's gangrene in a modern surgical setting: improved survival with aggressive management. *BJU Int* 1999; 84: 85-88. | 2. Kim IY. Gangrene: the prognostic factors and validation of the severity index in Fournier's Gangrene. *Gangrene – Current Concepts and Management Options*, Dr. | Alexander Vitin (Ed.). InTech. 2011. | 3. Tsai CC, Lai CS, Yu ML, Chou CK, Lin SD. Early diagnosis of necrotizing fasciitis by utilization of ultrasonography. *Kaohsiung J Med Sci* 1996; 12: 235-240. | 4. Yen ZS, Wang HP, Ma HM, Chen SC, Chen WJ. Ultrasonographic screening of clinically suspected necrotizing fasciitis. *Acad Emerg Med* 2002; 9: 1448-1451. | 5. Butcher CH, Dooley RW, Levitov AB. Detection of subcutaneous and intramuscular air with sonography. *J Ultrasound Med* 2011; 30: 791-795. | 6. Oelze L, Wu S, Carnell J. Emergency ultrasonography for the early diagnosis of necrotizing fasciitis: a case series from the ED. *Am J Emerg Med* 2013; 31: 632.e5- | 632.e7. |