



A Clinical Study of Upper Aero Digestive Tract Foreign Bodies and Its Management in A District Level Hospital

A.Rajesh Kumar

Assistant professor, E.N.T. department, Govt. Medical college, Anantapuram, A.P.

K.Sampath Kumar Singh

Associate professor, E.N.T. department, Govt. Medical college, Anantapuram, A.P.

Niharika B

Asst.Prof, Dept. of Community Medicine, Viswabharathi Medical College, Kurnool, A.P.

ABSTRACT

Background: Aspiration and ingestion of foreign bodies in to the upper aero digestive tract is not uncommon. They enter the aero digestive tract either accidentally or deliberately and often leads to oto-laryngological emergencies. These cases present with a wide spectrum of clinical problems from the minimal disturbance of function to severe morbidity or even sudden death. The severity of clinical symptoms depends on size of foreign body, site of impaction, duration and nature of foreign body. Young children under 3 years of age are particularly prone to such accidents; close supervision is needed to avoid these accidents. The aim of present study was to identify the patients with foreign body ingestion and aspiration, and management of such cases at district level hospital and the complications following their removal. **Methodology:** The study was done in E.N.T. department government medical college hospital, Anantapuram, A.P. from 2014 to 2016. Total 72 patients diagnosed as case of upper aero digestive tract foreign body on the basis of history, examination and investigations. **Results:** Foreign bodies in upper aero digestive tract were seen mostly in children less than 10 years of age (55%). The youngest was 8 months old and oldest 75 years, and there is no much difference between males and females (54%, 46%). In our study 93% cases had clear history of foreign body ingestion/inhalation. Most common site of foreign body lodgment is cricopharynx (66.7%), right main bronchus was the most common site in air way. Only 3% cases showed complications following rigid oesophagoscopy. Trachea – bronchial foreign bodies removed by rigid bronchoscopy and complications were not encountered in our study. **Conclusion:** upper aero digestive tract foreign body is an emergency situation. Proper management and favorable outcome depends on early diagnosis by meticulous history & imaging modality.

KEYWORDS : Foreign body ingestion/ inhalation, Aero-digestive tract, Cricopharynx, Oesophagoscopy, Bronchoscopy

Introduction:

foreign materials, such as food toys and other small objects can get lodged in the airway or oesophagus as a result of inhalation or swallowing. These objects can end up anywhere in the upper airway or the upper digestive tract including the nose, throat, oesophagus, the trachea or the smaller air passages in the lungs called bronchi. These cases present with a wide spectrum of clinical problems from the minimal disturbance of function to severe morbidity or even sudden death. Young children under 3 years of age are particularly prone to such accidents; close supervision is needed to avoid these accidents.

The type of foreign body and the site of obstruction depend on various factors. Clinically foreign bodies swallowed in to oesophagus present with dysphagia, on the other hand foreign body aspiration into tracheo-bronchial tree presents with dyspnea and stridor. They enter the aero digestive tract because of haste during eating, disturbances in physical function, impairments due to extreme youth or age, or contamination of food with foreign bodies. Its diagnosis is based on three diagnostic tools; clinical history, physical examination and radiography. Early diagnosis is the key to successful and uncomplicated management of these accidents. Delay in presentation to clinician, diagnosis and management can lead to life threatening complications. This article provides how to approach the aero digestive tract foreign body patient in emergency and its diagnosis, surgical removal & management of various complications in district level hospital.

Materials and methods:

The study was done in E.N.T. department government medical college hospital from 2014 to 2016. Total 72 patients of all ages & both sexes are included in this study.

Inclusion criteria:

1. All the patients with the history of accidental foreign body ingestion were included.

2. All the patients with suspicious foreign body aspiration and attend to op with cough & clinically wheeze especially one side of the chest is affected.
3. The children's from pediatrics ward with pneumonia which is unresponsive to regular antibiotic therapy and the history of foreign body aspiration is mysterious.
4. The children's / adults attended to emergency with sudden dysphagia and / or stridor were included in this study.

Exclusion criteria:

1. Radiologically the metal foreign bodies are below the diaphragm (stomach, small intestine and large intestine).
2. Foreign bodies in the nose.
3. The patients with foreign body sensation in throat and dysphagia due to chronic disease.
4. Patients with the history of foreign body ingestion / aspiration for more than 2 weeks and no evidence in clinically as well as radiologically were excluded from this study.

Diagnosis:

The diagnosis of aero digestive tract foreign body is confirmed by any one of these three diagnostic tools 1. Relevant history 2. Physical examination 3. Radiography.

Majority of these cases presented with history of aspiration or ingestion.

On physical examination they show the symptoms/ signs like breathing difficulty, trouble speaking, drooling of saliva, vomiting, difficulty in taking feeds, pain in throat and neck, coughing, wheezing or diminished breath sounds especially one side of the chest, pneumonia which is unresponsive to antibiotics.

All the subjects in this study are undergone plain x ray neck & chest postero-anterior view and lateral view, plain x ray abdomen poste-

ro-anterior view also taken in subjects where radio opaque foreign body is not present in upper aero digestive tract. Radio opaque foreign bodies like coin are present in the upper oesophagus as coronal plane, and in airway as in sagittal plane. Non radio opaque foreign bodies are appear in X ray neck lateral view as pre vertebral soft tissue shadow enhancement. Foreign body bronchus appears in X ray chest postero anterior view as lung/ lobe collapse. In two cases we had done MRI chest scan for suspected foreign body bronchus and report confirmed that foreign body in bronchus.

Surgical approach:

Successful retrieval of foreign bodies in aero digestive tract requires excellent team work between the surgeon, anesthetist and nursing staff; because the airway of the patient is manipulated by the surgeon and anesthetist.

Digestive tract:

An impacted foreign body in oesophagus is removed by rigid oesophagocopy as soon as the diagnosis is confirmed, because

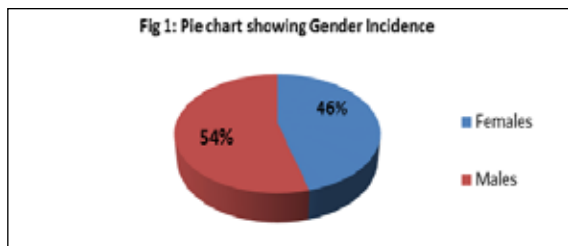
1. The chance of spontaneous passage in to stomach (less common for an impacted object).
2. Edema of the impacted site due to local trauma, this causes grip the object more firmly and later manipulation is more difficult.
3. Impacted sharp objects cause local infection and abscess.
4. Perforation of the oesophagus is much more serious and dangerous complication.

Airway:

To remove the foreign bodies in the air way the authors used rigid bronchoscope with tele endoscope of various sizes depends on the age of the child. Rigid bronchoscopy using jet ventilation offers good visualization and successful outcome.

Results:

Total 72 subjects were studied during the 2 years period. Among these 33 patients are females (46%) and 39 patients are males (54%) [Fig.1], there is no much difference between males and females in the incidence of foreign body impaction in this study.



Majority of aero digestive tract foreign bodies are noticed in their first decade and second highest possibility seen in their 6th decade of their life. In our study 39patients (55%) are below 10 years of age, and 15% patients are above 50 years of age [Fig.2]. In our study digestive tract foreign body impaction is more common comparing to respiratory tract [Table 1] and foreign bodies in air way seen in children's only but foreign bodies in digestive tract seen in all ages.

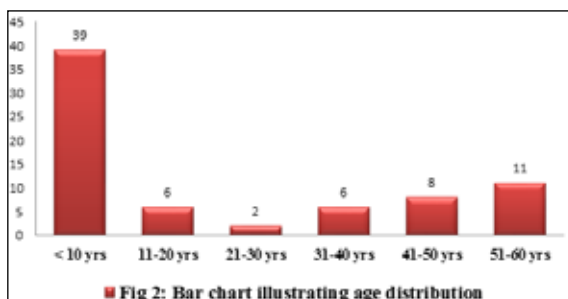


Table 1: Table showing the location of foreign bodies and ages of patients

Age in years	Location of foreign body		No. of patients
	Airway	Digestive tract	
Less than 1 yr	3	3	6
1-10	5	28	33
11-20	0	6	6
21-30	0	2	2
31-40	0	6	6
41-50	0	8	8
51 and above	0	11	11
Total	8	64	72

In our study 93% (67 cases) had clear history of foreign body ingestion / inhalation and only 7% (5 cases) does not have the history of foreign body ingestion / inhalation. Most common site of foreign body lodgment is cricopharynx [Table 2]. In our study cricopharyngeal foreign body 66.7%, oropharynx 11.1%, mid oesophagus 5.6%, and nasopharynx 2.78%. right main bronchus was the most common site of foreign body lodgment in the air way , this constitutes 6.9%, left bronchus 1.39%, trachea 2.78%.

Table 2: Table showing the site of impaction of foreign body

S.No.	Site of impaction of foreign body	No. of patients	Percentage
1	Nasopharynx	2	2.78%
2	Oropharynx	8	11.1%
3	Cricopharynx	48	66.7%
4	Mid oesophagus	4	5.6%
5	Trachea	2	2.78%
6	Right bronchus	5	6.9%
7	Left bronchus	1	1.39%
8	None (diagnostic)	2	2.78%
	Total	72	100%

In the present study various types of foreign bodies removed from upper aero digestive tract [Table 3], coins were the most common foreign body impacted in the upper aero digestive tract; this constitutes 46% of total aero digestive tract foreign bodies. In our set up we removed 52% of coins and 25% of chicken / mutton bone foreign bodies from digestive tract. Ground nuts was the most common foreign body of the respiratory tract, this constitutes 75% of total respiratory tract foreign bodies.

Table 3: Table showing different types of foreign bodies

Airway		Digestive tract	
Type of foreign body	Total number	Type of foreign body	Total number
Ground nut	5	Fish bone	6
Sitaphal seed	1	Stapler pin	1
Green pea	1	Sharp wood piece	1
Plastic whistle	1	Plastic bottle cap	1
		Metal disc battery large	1
		coins	33
		Artificial dentures	3
		Chicken / mutton piece with bone	16

Out of 72 cases, one patient presented with impacted foreign body at cricopharynx and retro pharyngeal abscess. Wesuccessfully drained the abscess and removed the impacted foreign body, immediate post-operative period he developed pulmonary edema and recovered after 24 hours by the effort of anesthetist, physician and surgeon. In other case due to delayed presentation to clinician impacted chicken bone foreign body at mid oesophagus developed mediastinitis and

oesophageal perforation after removal, this case had been shifted to surgical gastro-enterology department and treated conservatively for 10 days and discharged. In our study death was not recorded by rigid oesophagoscopy and rigid bronchoscopy.

Discussion:

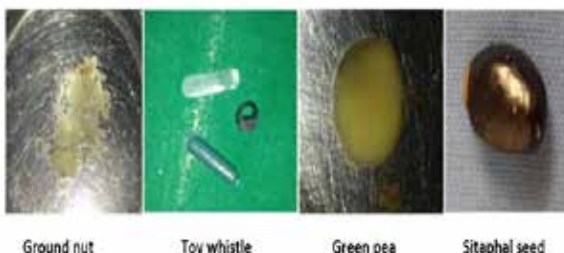
Aspiration and ingestion of foreign bodies in to the upper aero digestive tract is common. They enter the aero digestive tract either accidentally or deliberately and often constitute oto-laryngological emergencies. Foreign body impaction in the upper air way & digestive tract has been a problem since the earliest of reported history. The foreign body spectrum was defined by Jackson as an object or substance foreign to the location where it is found. A wide variety of foreign bodies may be inhaled or swallowed. Ground nuts, sitaphal seed, pins, and whistles are some of the common foreign bodies aspirated, whilst coins, fish bone, chickenbone, mutton bone are the common foreign bodies swallowed in to the food passage.

Various factors can be responsible for the aspiration or swallowing of foreign bodies. The increased incidence in small children could be due to their natural propensity to gain knowledge by putting things in the mouth, inability to masticate well and inadequate control of deglutition, as well as the tendency to cry, shout, laugh or play during eating. Psychological factors like mental retardation, behavioral disorders, anxiety neurosis and hyper kinetic syndrome also can compound the problem [1]. The maturity of an adult larynx may account for the relatively lower incidence of trachea-bronchial foreign bodies, but possibly increases their chance of slipping in to the oesophagus. The severity of the symptoms depends upon the site, size, composition and duration of foreign body presenting to hospital. It can be life threatening thus need prompt management.

In a case of oesophageal foreign body the clinical presentation is usually with acute dysphagia, coughing, gagging, drooling of saliva and regurgitation, on the other hand bronchial foreign bodies lead to respiratory embarrassment, dyspnea, tachypnea, stridor, cough, change in voice and cyanosis.

Respiratory tract: Aspiration of foreign bodies is much more common in children and high incidence of aspiration occurs between 1to 3 years [2,3,4,5].Our review confirmed the earlier findings of Banerjee et al. and Rohan et al. that the highest incidences of foreign body aspiration were in children below three years. Small and smooth walled objects tend to pass in to trachea and bronchi whereas larger ones can cause acute laryngeal obstruction [3]. Most foreign bodies are found on the right side since the right main bronchus is wider, shorter and straighter than the left, and also because the interbronchial septum projects to the left [6]. Hassan et al. opined that anatomical and aerodynamic considerations determine the site of final impaction [6]. The authors removed a range of foreign bodies from the air way such as ground nut seeds, sitaphal seed, green pea seed and whistle [Fig 3]. In the study of Murty PSN [7], the common site of impaction of foreign body in the air way is the right bronchus, whereas cricopharynx was the common site in food passage. It was observed in our study that majority of foreign bodies in trachea-bronchial tree were found in the right bronchus (62.5%), which is comparable to the series of Zerrella et al[8]. Rigid bronchoscopy with telescope using jet ventilation is the preferred mode of treatment. As reported flexible fiber-optic bronchoscopes also have good rate of success [9]. The authors however, have not used these. Good anesthetic support is a must for success [10]. In this study we removed 8 foreign bodies from the air way without any complications.

Fig 3: Showing respiratory tract foreign bodies removed by bronchoscopy



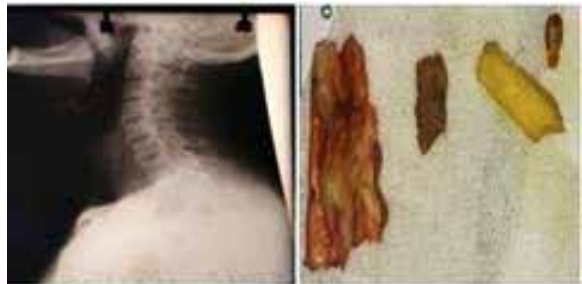
Food passage: oesophageal foreign bodies are more likely in adults, both males and females are equally affected [11]. Khan MA found that coin was the most common foreign body in aero digestive tract[12]. our study also confirmed that and impacted coins in upper oesophagus seen in children below 5 years of age and ingestion of dentures, chicken bone, mutton bone foreign bodies [Fig 4,5] are common in their 6th decade of life. Foreign bodies can be impacted in the pharynx and oesophagus mainly because of their size, shape and anatomical narrow segments. The oesophagus is passive and unadoptable organ and its peristalsis is not strong enough to prevent its retaining certain types of swallowed objects [13]. The pharyngeal constrictors are usually strong enough to propel an object through the sphincter, and the oesophageal muscles are relatively weaker at pushing it downwards, foreign bodies usually impact below the cricopharyngeal sphincter. Predisposing factors such as stricture, neuromuscular disturbance [14], hiatus hernia, and achalasia cardia or carcinoma oesophagus can often present with foreign body impaction as their first symptom.

Fig 4: Showing removed oesophageal foreign bodies & coin at cricopharynx in X-ray



Oesophageal foreign body in neonates can present with paradoxical respiratory obstruction. This is because the oesophageal foreign body presses the posterior tracheal wall causing irritation of respiratory tract or inhalation of food contents [15]. Peri-oesophageal reaction and edema of laryngeal inlet have also been postulated to play a role. Chaturvedi et al. postulated that the oesophageal foreign body led to pushing forward of the soft cricoid lamina of the neonate leading to respiratory obstruction. There is usually no dysphagia reported for fluids which form the neonatal diet and easily bypass the obstruction [16,17, 18, 19]

Fig 5: Showing appearance of chicken bone in X-ray & after removed



Complications in a case of foreign bodies of the oesophagus are due to delayed presentation type location and radiolucency of foreign body. Mediastinitis, interstitial emphysema, retropharyngeal abscess and oesophageal abscess are some of the noted complications. In older people these complications are more common with radiolucent foreign bodies as noted by Singh et al. [20]. In our study one patient had retropharyngeal abscess due to delayed presentation of chicken bone impaction, 3 cases of chicken/ mutton impacted at mid oesophagus are pushed in to stomach. This avoids the risk of perforation & tears the oesophageal wall. Nature can then be allowed to take its course. In our study we encountered only 3% of complications in removal of upper aero digestive tract foreign bodies, this was comparable in a study by Black et al and study by Murty PSN[21].

We had removed two nasopharyngeal foreign bodies; in one case accidentally it enters the nasopharynx by trying to remove the foreign body in the oral cavity by mother with her fingers, in other case after ingestion of foreign body due to severe cough it pushed in to nasopharynx instead of coming out of mouth.

Conclusion:

1. Upper aero digestive tract foreign body is an emergency condition for patient as well as to ENT surgeon.
2. The surgeon must come to diagnosis that the location and nature of foreign body by proper history, clinical symptoms with proper investigations.
3. In our study foreign body are found more commonly in digestive tract than respiratory tract.
4. To avoid complications proper size of rigid scope with telescopes helps much better than blind removal.
5. Early presentation to clinician and removal always minimize the complication of the procedure.
6. Improve the health education to parents and socio economic status of the society can reduce the risk of foreign body aspiration/ ingestion. A successful example is that Israel, where foreign body aspiration / ingestion reduced 35% by health education by media and community pediatric care[22].

References:

1. Banerjee S. Concept of the foreign body—its past and present. *Indian Journal of Otolaryngology and Head and Neck Surgery*. :23–30. Spl No. on foreign bodies; Retrieved from <https://www.ncbi.nlm.nih.gov/pmc/articles/PMC3451020/>
2. Brown DA, Clark CM. Inhaled foreign bodies in children. *Med J Aust*. 1983; 2:322–6. [Pub Med]
3. Banerjee A, Rao KS, Khanna SK, Narayanan PS, Gupta BK, Sekar JC, et al. Laryngo-tracheo-bronchial foreign bodies in children. *J Laryngol Otol*. 1988;102:1029–32.
4. Rothman BE, Boeckmann CR. Foreign bodies in the larynx and tracheo-bronchial tree in children: a review of 225 cases. *Ann OtolRhinolLaryngol*. 1980;89:434-6.
5. Stevens C, Ardagh M, Abbott GD. Aerodigestive tract foreign bodies in children. One year's experience at Christchurch hospital emergency department. *N Z Med J*. 1996;109(1024):232-3.
6. Hassan AM, Ghosh P, Menon PSN, Kaul HL, Mukhopadhyaya S. Changes in tracheo-bronchial angles as a function of age. *Indian Journal of Otolaryngology and Head and Neck Surgery*. 1993;2:1–6.
7. Murty PSN, Vijendra S. Ingle, Ramakrishna S, Fahim A. Shah, Varghese Philip. Foreign bodies in the upper aerodigestive tract. *SQU J scient Res Med Sci*. 2001;3(2):117-20.
8. Zerella JT, Dimler M, McGill LC, Pippus KJ. Foreign body aspiration in children: value of radiology and complications of bronchoscopy. *Paediatr surg*. 1998;33:1651-4.
9. Cunanan OS. The flexible fiberoptic bronchoscope in foreign body removal. Experience in 300 cases. *Chest*. 1978;73:725–6. [PubMed]
10. Swanson KL, Edell ES. Tracheobronchial foreign bodies. *Chest SurgClin N Am* 2001; 11(4):861–872.
11. Biswas B, Datta R. Retained oesophageal foreign bodies—Report of three cases. *Indian Journal of Otolaryngology and Head and Neck Surgery*. 1999;15–8. Spl No. on foreign bodies, Retrieved from <https://www.ncbi.nlm.nih.gov/pmc/articles/PMC3451028/>
12. Khan MA, Hameed A, Choudhary AJ. Management of foreign bodies in the oesophagus. *J Coll Physicians Surg Pak*. 2004 Apr;14(4):213-20.
13. Wilson RT, Dean PJ, Lewis M. Aorto-esophageal fistula due to a foreign body. *Gastrointest Endosc*. 1987;33:448–50. [PubMed]
14. Bakara A, Bikhazi G. Oesophageal foreign bodies. *BMJ*. 1975;1:561–3. Retrieved from <https://www.ncbi.nlm.nih.gov/pmc/articles/PMC1672660/>. [PubMed]
15. Ellis PDM and Ardran GM - Oesophageal foreign body in an infant - *Journal of Laryngology and Otology* — 1973 - 87 -pg691-698.
16. Chaturvedi VN, Raizada RM, Jain SKT, Lochab JD, Nagpure P - Foreign bodies in aerodigestive tract - *Indian J of Otorhinolaryngology* - Dec 1988 - Vol 40 - 4 - pg 152-5.
17. Lt. Col. Chowdhury CR, Capt Bricknell M.C.M, Major MacIver D - Oesophageal Foreign body - an unusual cause of respiratory symptoms in a three week old baby - *Journal of Laryngology and Otology* - June 1992 Vol 106 - Pg 5567.
18. Halit V, Gunaydin S - An unusual Foreign body swallowed by a newborn causing respiratory distress - *Acta Gastro-Enterol Belg* 1993 - Sep - Dec 56 (5-6) - 359-60.
19. Hirsch M & Newbegin CJR - Oesophageal Foreign body presenting with paradoxical respiratory symptoms — *British Journal of Clinical Practice* - July / Aug 1994 - Vol 48 - 4 - pg 212-3.
20. Singh B, Manj K, Eucente FE - Complications associated with 327 Foreign body of the pharynx, larynx and oesophagus — *Ann OtolRhinol Laryngeal* 1997 - 106 - 301-4.
21. Black RE, Johnson DG, Matlak ME. Bronchoscopic removal of aspirated foreign bodies in children. *J Paediat Surg*. 1994;29:682-4.
22. Sadan N, Ras A, Wolach B. Impact of community educational programmes on foreign body aspiration in Israel. *Eur J Pediatr*. 1995;154:859–62. [PubMed]