



Sigmoid Volvulus : Role of Imaging

Dr. Priti Kapoor

Associate Professor, DEPARTMENT OF RADIODIAGNOSIS, MGM MEDICAL COLLEGE & HOSPITAL, KAMOTHE, NAVI MUMBAI - 410 209.

Dr. Shishir Kumar

Senior Resident, DEPARTMENT OF RADIODIAGNOSIS, MGM MEDICAL COLLEGE & HOSPITAL, KAMOTHE, NAVI MUMBAI - 410 209.

Dr. Shreyansh S.Kothari

Resident, DEPARTMENT OF RADIODIAGNOSIS, MGM MEDICAL COLLEGE & HOSPITAL, KAMOTHE, NAVI MUMBAI - 410 209.

ABSTRACT

Sigmoid volvulus is not only the most common site of colonic volvulus but also the commonest volvulus in the Gastrointestinal tract. It accounts for 60%–75% of all cases of colonic volvulus with male to female ratio around 2:1. Sigmoid Volvulus is a common cause of lower bowel obstruction in elderly individuals but can also be seen in childhood. Imaging plays an important role in diagnosis and evaluation of Sigmoid Volvulus. It also helps in evaluating the predisposing factors if present and also assessing the degree of obstruction and complications like Bowel Ischaemia and Perforation.

KEYWORDS : Sigmoid volvulus, P. Kapoor, S. Kumar, S. Kothari.**Introduction :**

The term volvulus, derived from a Latin word, means "to twist". A colonic volvulus occurs when a part of the colon twists on its mesentery, resulting in acute, subacute, or chronic colonic obstruction. The sigmoid is the most common site of colonic volvulus. Sigmoid volvulus was first described by Rokitsky in 1836^{1,2} as torsion of the Sigmoid Colon around itself and its mesentery (mesocolon) causing closed loop obstruction³. Sigmoid volvulus is the most prevalent cause of colonic obstruction in eastern countries^{4,5}. More common in elderly patients, mostly in 4th – 8th decade of life⁶, there is male predominance. (M:F – 2:1)^{7,8}

The etiology of Sigmoid volvulus is multi factorial^{9,10}. The anatomic constitution of the sigmoid colon makes it vulnerable for formation of volvulus. The redundancy of sigmoid colon¹¹, dolichomesentery which denotes a mesentery that is wider than long^{12,13}, narrowing of the base of the sigmoid mesentery are some important factors which makes sigmoid colon susceptible to formation of volvulus.

Much of literature shows a positive correlation between age and sigmoid colon redundancy and dolichomesentery¹⁴ which explains the relation between age and sigmoid volvulus. Dolichomesentery and smaller pelvic inlet are common in males which predisposes to torsion which also explains the male predominance. In females, Sigmoid volvulus is commonly seen in pregnancy when the enlarged uterus displaces the redundant sigmoid colon out of the pelvis and predisposes it to torsion¹⁵. High altitude causes high colonic pressure leading to redundant sigmoid colon could be one of the reasons behind this geographic preponderance¹⁶. Habitual constipation may cause elongation of sigmoid colon which is common in elderly. Patients with neurologic deficit or metabolic disorder have high risk of developing Sigmoid volvulus.

There can be other predisposing factors for Sigmoid volvulus like postoperative adhesions, internal herniations, omphalo-mesenteric abnormalities, malrotations, intussusception, congenital megacolon, appendicitis, and carcinomas.

Classification –

Based on etiological factors, Sigmoid volvulus can be classified as either primary or secondary. Sigmoid volvulus that is the result of diseases such as postoperative adhesions or internal herniation is regarded as secondary.

Recently based on preoperative and operative criteria that are correlated with mortality, a classification was developed for

surgically treated Sigmoid volvulus¹⁷. In this classification, patients are classified as follows –

- Class 1 : Patients with no risk factor as advanced age, associated disease.
- Class 2 : Patients with no shock or bowel gangrene but with other risk factors mentioned above.
- Class 3 : Patients with shock.
- Class 4 : Patients with bowel gangrene
- Class 5 : Patients with both shock and bowel gangrene.

There are two important complications of Sigmoid volvulus: luminal obstruction and vascular occlusion¹⁸. Mechanical obstruction and bacterial fermentation cause the distension of the twisted-loop and the proximal colon¹⁹. Increase in intracolonic pressure decreases capillary perfusion. Both mechanical occlusion and thrombosis of the vessels contribute to ischemia²⁰. Mucosal ischemic injury causes bacterial translocation and toxemia, resulting in colonic gangrene. Increased intra-abdominal pressure causes abdominal compartment syndrome.

Hypertrophied colonic wall, thickened mesentery, prominent vessels, splayed out teniae, and loss of haustrations are the morphological changes seen in Sigmoid Volvulus²¹.

Aims and Objectives :

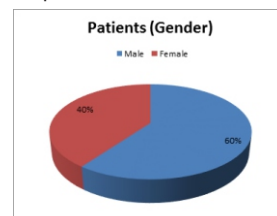
- To assess the diagnostic value of Imaging in cases of Sigmoid volvulus
- To study Radiological features of Sigmoid volvulus.

Materials and Methods :

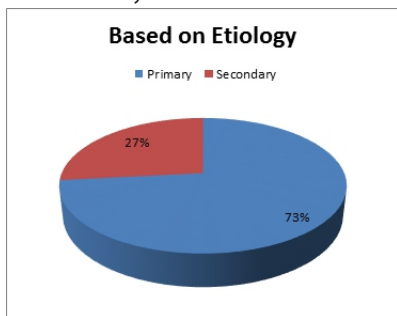
Source of Data : 15 patients were included in our study who were clinically and Radiologically diagnosed as cases of sigmoid volvulus. A retrospective and observational review was done. Study was conducted from May 2015 to December 2016.

Results :

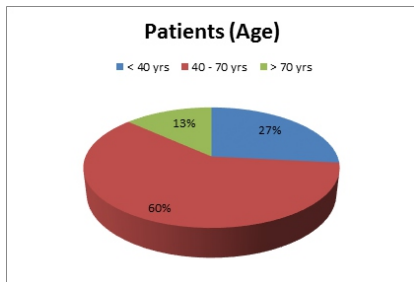
In our study, out of 15 patients 9 were males and 6 were females.



In our study 11 patients were primary cases of sigmoid volvulus and 4 patients were secondary cases.



In our study 4 patients were less than 40 yrs of age, 9 patients were between age 40 – 70 yrs of age and 2 patients were above 70 yrs.



Our study also inferred that Imaging plays an important role as the reliable diagnostic tool in cases of Sigmoid volvulus. Abdominal plain X-ray, can diagnose it with high accuracy. It also helps in detecting associated complications like bowel ischaemia and perforation.

Discussion :

Routine laboratory findings for Sigmoid volvulus are not pathognomonic, and the findings are related to intestinal obstruction and/or bowel ischemia or gangrene²².

The key Radiologic features of sigmoid volvulus are those of a double-loop obstruction, which has been reported in approximately 50% of patients. Plain abdominal X- Plain abdominal radiography has been found diagnostic in 57%–90% of patients. rays usually show a dilated sigmoid colon and multiple small or large intestinal air-fluid levels. The described diagnostic X-ray signs are an 'omega' or 'horseshoe' sign^{23,24} , 'bird beak' sign²⁵, 'inverted V' sign²⁶, 'Y' sign, 'coffee bean' sign²⁷, 'bent inner tube' or 'ace of spades' sign, 'left pelvic overlap' or 'left flank overlap' sign, 'liver overlap' sign, and 'empty left iliac fossa' sign.(Figure 1)

A barium or water-soluble contrast enema generally shows the obstructive lumen as a beak-like termination.

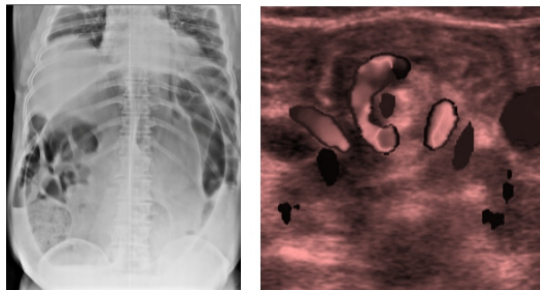
Ultrasonography is usually inconclusive due to air artifact due to obstruction, in some cases dilated bowel loops and features of bowel obstruction can be identified. Rarely on Colour Doppler, twisted mesentery with vessels ('whirlpool sign') can be identified. (Figure 2)

Computed tomography scan findings of sigmoid volvulus include the 'whirl sign', which represents tension on the tightly twisted mesocolon by the afferent and efferent limbs of the dilated colon^{28,29,30,31,32} (Figure 3,4 & 5). CT scanning may be useful in identifying the etiology and site of the obstruction that result from other pathologies, as well as in demonstrating ischemia that results from strangulation. CT scan signs of ischemia include a serrated beak at the site of the obstruction, mesenteric edema or engrossment, and moderate to severe thickening of the bowel wall. Intramural gas or portal venous gas may be seen (grave prognostic indicators), and in patients in whom a perforation has occurred, a

large amount of free intraperitoneal gas or fluid may be noted. Patients with Sigmoid volvulus have a tendency to be in hypovolemic and in toxic shock; effective resuscitation is needed. Flexible endoscopic detorsion is primary treatment of choice for sigmoid volvulus with good success rate. However laparotomy is required for patients with peritonitis, bowel gangrene or perforation^{33,34} (Figure 6)

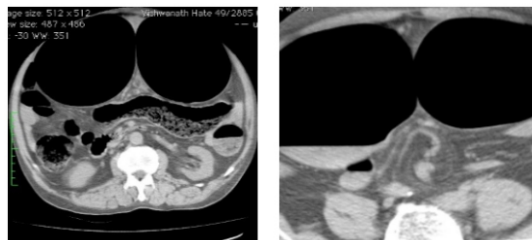
Conclusion:

Imaging plays an important indispensable role in the diagnosis of Sigmoid Volvulus as otherwise, the clinical findings are non-specific and overlap with features of acute abdomen due to other causes, making it very challenging to diagnose without Imaging as Laboratory investigations also are hardly specific. Imaging also helps in evaluating the etiological factors, in assessing the degree of obstruction and detecting its complications like Bowel Ischaemia and Perforation, thereby helping in better management of cases.



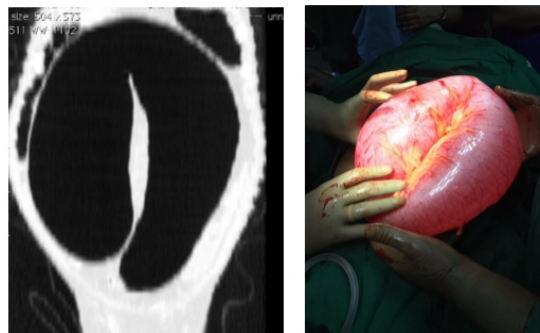
• **Figure 1 :** 40 years male patient with c/o constipation and abdominal distension . Abdominal AP reveal a large ahaustral C-shaped distended bowel loop converging into right iliac fossa. (Coffee bean Sign)

• **Figure 2 :** Colour Doppler of same patient reveales “Whirlpool sign” due to twisting of mesentery with vessels.



• **Figure 3 :** 60 years male patient with c/o constipation and abdominal distension . CT Abdomen plain reveal large gas-filled loop without haustral markings, forming a closed-loop obstruction.

• **Figure 4 :** Focused axial images of abdomen reveals twisting of vessels around mesentery. (“Whirl Sign”)



• **Figure 5 :** Coronal reconstructed images of same patient shows classic coffee bean appearance with central hyperdense apposed bowel wall.

• **Figure 6 :** Intra operative picture of a case of Sigmoid volvulus

showing a distended "U" shaped configuration of colon.

References :-

1. Raveenthiran R, Madiba TE, Atamanalp SS, De U. Volvulus of the sigmoid colon. *Colorectal Dis.* 2010;12:1-17.
2. Arnold GJ, Nance FC. Volvulus of the sigmoid colon. *Ann Surg.* 1973;177:527-37.
3. Atamanalp SS, Yildirman MI, Basoglu M, Kantarci M, Yilmaz I. Sigmoid colon volvulus in children: review of 19 cases. *Pediatr Surg Int.* 2004;20:492-5.
4. Lal SK, Morgenstern R, Vinjirayer EP, Matin A. Sigmoid volvulus an update. *Gastrointest Endoscopy Clin N Am.* 2006;16:175-87.
5. Madiba TE, Thomson SR, Corr P. Volvulus of the sigmoid colon. *Gastroenterol Forum.* 1997;8:28-33.
6. Ballantyne GH, Brandner MD, Beart RW, Ilstrup DM. Volvulus of the colon. Incidence and mortality. *Ann Surg.* 1985;202:83-92.
7. Avots-Avotins KV, Waugh DE. Colon volvulus and geriatric patient. *Surg Clin North Am.* 1982;62:249-60.
8. Pahlman L, Enblad P, Rudberg C, Krog M. Volvulus of the colon. *Acta Chir Scand.* 1989;155:53-6.
9. Bhatnagar BN, Sharma CL, Gupta SN, Mathur MM, Reddy DCS. Study on the anatomical dimensions of the human sigmoid colon. *Clin Anat.* 2004;17:236-43.
10. Madiba TE, Haffajee MR, Sikhosana MH. Radiological anatomy of the sigmoid colon. *Surg Radiol Anat.* 2008;30:409-15.
11. String ST, DeCosse JJ. Sigmoid volvulus: An examination of the mortality. *Am J Surg.* 1971;121:293-7.
12. Tubes MN. Volvulus of the sigmoid colon in relation to the anatomy of the pelvic colon. *South Afr Med J.* 1963;37:1151-5.
13. Katsarski M, Singh U. Anatomical characteristics of the sigmoid intestine and their relationship to sigmoid volvulus among the population of Uganda and the city of Plovdiv, Bulgaria. *Khirurgija Sofia.* 1977;30:159-63.
14. Sadahiro S, Ohmura T, Yamada Y, Saito T, Taki Y. Analysis of the length and surface area of each segment of the large intestine according to age, sex and physique. *Surg Radiol Anat.* 1992;14:251-7.
15. Lord SA, Boswell WC, Hungerpiller JC. Sigmoid volvulus in pregnancy. *Am Surg.* 1996;62:380-2.
16. Anand AC, Sashindran VK, Mohan L. Gastrointestinal problems at high altitude. *Trop Gastroenterol.* 2006;27:147-53.
17. Atamanalp SS, Aydinli B, Öztürk G, et al. Classification of sigmoid volvulus. *Turk J Med Sci.* 2008;38:425-9.
18. Arigbabu AO, Badejo OA, Akinola DO. Colonoscopy in the emergency treatment of colonic volvulus in Nigeria. *Dis Colon Rectum.* 1985;28:795-8.
19. Sinha RS. A clinical appraisal of volvulus of the pelvic colon with special reference to aetiology and treatment. *Br J Surg.* 1969;56:838-40.
20. Gibney EJ. Volvulus of the sigmoid colon. *Surg Gynecol Obstet.* 1991;173:243-55.
21. Madiba TE, Ramdial PK, Dada MA, Mokoena TR. Histological evidence of hypertrophy and ischemia in sigmoid volvulus among Africans. *East Afr Med J.* 1999;76:381-4.
22. Atamanalp SS, Keleş MS, Öztürk G, Özöğül B, Kısaoğlu A, Akbaş A. Serum sodium levels in sigmoid volvulus. *EAJM.* 2009;41:1-3.
23. Wai CT, Lau G, Khor CJL. Clinics in diagnostic imaging. *Singapore Med J.* 2005;46:483-7.
24. Tsang TK, Siu KW, Lai A, Kwok PC, Chan S. Images of interest: Sigmoid volvulus. *J Gastroenterol Hepatol.* 2005;20:790.
25. Slidell M, Samir SA, Feller ER. Sigmoid volvulus in three college-age teenagers. *J Clin Gastroenterol.* 2004;38:910-1.
26. Chen SY, Liu CT, Tsai YC, Yu JC, Lin CH. Sigmoid volvulus associated Chilaiditi's syndrome. *Rev Esp Enferm Dig.* 2007;99:476-83.
27. Feldman D. The coffee bean sign. *Radiology.* 2000;216:178-9.
28. Bernard C, Lubrano J, Moulin V, Manton G, Kastler B, Delabrousse E. [Value of multidetector-row CT in the management of sigmoid volvulus]. *J Radiol.* 2010 Feb. 91 (2):213-20.
29. Macari M, Spieler B, Babb J, Pachter HL. Can the location of the CT whirl sign assist in differentiating sigmoid from caecal volvulus?. *Clin Radiol.* 2011 Feb. 66 (2):112-7.
30. Hirao K, Kikawada M, Hanyu H, Iwamoto T. Sigmoid volvulus showing "a whirl sign" on CT. *Intern Med.* 2006. 45(5):331-2.
31. Shaff MI, Himmelfarb E, Sacks GA, Burks DD, Kulkarni MV. The whirl sign: a CT finding in volvulus of the large bowel. *J Comput Assist Tomogr.* 1985 Mar-Apr. 9(2):410.
32. Lee SH, Park YH, Won YS. The ileosigmoid knot: CT findings. *AJR Am J Roentgenol.* 2000 Mar. 174(3):685-7.
33. Oren D, Atamanalp SS, Aydinli B, et al. An algorithm for the management of sigmoid colon volvulus and the safety of primary resection: experience with 827 cases. *Dis Colon Rectum.* 2007;50:489-97.
34. Madiba TE, Thomson SR. The management of sigmoid volvulus. *J R Coll Surg Edinb.* 2000;45:74-80.