



## ANALYTICAL STUDY OF FUNCTIONAL OUTCOME IN EXTENSION TYPE DISPLACED SUPRACONDYLAR HUMERAL FRACTURES IN CHILDREN TREATED WITH K-WIRE FIXATION BY LATERAL AND CROSS PINNING

**DR.R.RAMARAJ  
RATHNASAMY**

M.S.ORTHO, SENIOR ASST.PROFESSOR, DEPT.OF ORTHOPAEDICS, GOVT.STANLEY MEDICAL COLLEGE,CHENNAI

**DR.AROKIAMARY**

M.B.B.S

### ABSTRACT

**BACKGROUND:** Fractures of the supracondylar humerus are common in children. All the children age group- 2 years to 13 years [both sex] with displaced supracondylar fractures of the humerus who presented to the orthopaedic outpatient or casualty were included for the study.

**METHODOLOGY:** Patients were reassessed in the ward for neurovascular injuries and any other associated injuries. Surgery was planned on the same day or the next day after obtaining written informed consent. Patients were randomly selected by drawing lots with even number included in group A (Lateral entry) and odd number in group B (medial and lateral entry).

**RESULTS:** The k-wires exit is done after a relatively shorter duration [3 weeks]. All patients were followed up regularly and evaluated clinically and radiologically for fracture union and other complications. Primary bony union: 24 cases. varus Angulation: nil. Malrotation: nil. Elbow Stiffness: 4 cases. Duration of follow up: 3 weeks post op to 6 months (average 3 months). In 20 patients with excellent results there was no shortening, malalignment, no pain or swelling in the fracture site. near normal range of elbow movements.

**CONCLUSION:** Pinning with k-wires for displaced supracondylar humerus fractures has been established world wide as the gold standard treatment. This is because of its minimal invasiveness, less intra operative and post operative complications. The k-wires exit is done after a relatively shorter duration [3 weeks]. Early mobility, a low rate of complications and high incidence of union obtained in this study in both the techniques compared.

**KEYWORDS :** SUPRACONDYLAR HUMERUS FRACTURES, CROSS PINNING, LATERAL PINNING

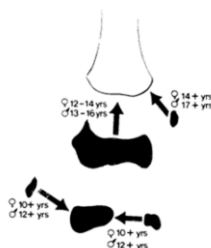
### INTRODUCTION

Supracondylar fracture of humerus fracture forms two third of all elbow injuries in children. The incidence is maximum between the age group of 3 and 10 yrs. it is more common in boys than girls in the ratio of 3:2. The incidence is maximum in the first 5 yrs of life. The average age of fracture to occur is 6.7 years. Non dominant limb was injured upto 60% of cases than dominant side. More than 97% have extension type of fractures. The common complications associated with this fracture are Nerve and vascular injuries both forming 7% and 1% respectively. In older studies the radial nerve is said to be the most frequently injured nerve. Now the anterior interosseous nerve (AIN), branch of the median nerve is the most commonly injured nerve. The ulnar nerve may be injured iatrogenically or in a flexion-type of supracondylar fracture.

Most common cause of supracondylar fractures of humerus is accidental fall from height. In children less than 3 years of age, domestic injuries and in children over 3 years of age, play ground injuries account for the fracture generally. In children younger than 15 months of age a non accidental cause should be suspected. Supracondylar fracture of humerus is also called as Malgaigne's fracture. The Fracture line normally passes proximal to the trochlea and capitellum through the apices of coronoid and olecranon fossae. The fracture line is generally transverse.

### OBJECTIVE OF THE STUDY

The aim of our study is to analyse the functional outcomes and complications resulting from displaced extension type supracondylar fractures of humerus in children treated by k-wires in our institution.



### MECHANISM OF INJURY

<sup>1</sup>Supracondylar fractures of the humerus generally occur due to an extension or flexion force on the distal humerus. Fall on the outstretched hand with fully extended elbow is the most common mechanism of injury.

### CLINICAL EVALUATION

An elbow fracture should be suspected in a child with pain or inability to use the upper limb after a fall injury. The initial radiological assessment should include the entire upper limb. The differential diagnosis should also include occult fracture, nursemaid's elbow, and infection.

<sup>1</sup>**Posterior fat pad sign** can be seen in some cases. In type III fractures, gross displacement of the elbow is evident. An **anterior pucker sign** may be present if the proximal fragment has penetrated the brachialis and the anterior fascia of the elbow. This is known as the **Dimple sign**. There may be **S-shaped deformity**<sup>1</sup> of distal arm. Careful motor, sensory, and vascular examinations should be performed in all patients.

### COMPLICATIONS AND ASSOCIATED INJURIES

#### Early complications:

1. neurological injuries
2. vascular injuries
3. compartment syndrome
4. Physeal damage

#### Delayed complications:

1. Loss of mobility or Elbow stiffness
2. Myositis ossificans
3. Cubitus varus
4. Avascular necrosis of trochlea

### RADIOGRAPHIC EVALUATION

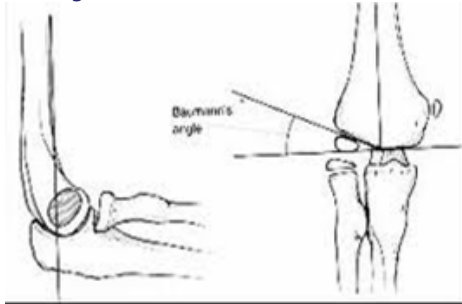
A thorough radiologic evaluation is indicated in patients with a history of a fall, pain elbow and inability to use the extremity. This may include obtaining AP and lateral views of the entire upper extremity and **jones view** of the elbow. Comparison views occasionally may be needed to evaluate an ossifying epiphysis. The AP x-ray should always be taken as an AP of the distal humerus. This allows more accurate evaluation of the distal humerus and

decreases the error in determining angular malalignment in the distal humerus. It also allows better evaluation of the olecranon fossa as an indication of injury in the distal humerus. The lateral film should be taken as a true lateral with the humerus held in the anatomic position and not externally rotated. In the absence of a clear osseous injury, always look for a **posterior fat pad sign or an elevated anterior fat pad**. This is an important indicator of an occult intraarticular elbow injury or more frequently a type I supracondylar fracture.

AP view X-Rays done for measuring

1. **Baumann's angle**
2. **Humero-Ulnar angle**

**Baumann's angle:**



normal value is 15-20 degrees

**Significance of Baumann's angle:**

It is used for assessing the fracture reduction. This is correlated with the final carrying angle. It does not disappear by elbow flexion or pronation.

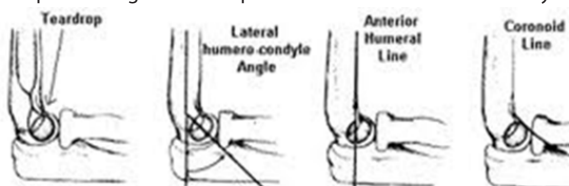
A change in 5 degrees of Bauman's angle will change 2 degrees of clinical carrying angle.

**Humero-Ulnar angle:**

This forms the carrying angle. The normal value is 10 to 15 degrees

**Lateral view X-Rays:**

**Tear drop**: It is formed by the posterior margin of the coronoid fossa anteriorly, anterior margin of the olecranon fossa posteriorly and the superior margin of the capitellar ossification center inferiorly.



The anterior humeral line is used to assess the displacement and the adequacy of reduction of supracondylar humeral fractures in children. It is said to pass through the middle third of the capitellum in the elbow of a normal child.

**Coronoid line:**

Proximally directed line along the anterior border of the coronoid process should be tangent to the anterior aspect of lateral condyle

**Shaft-condylar angle:**

The normal value is 30 to 45 degrees

**Other important signs**

**Fat pad sign:** Anterior, posterior and supinator fat pads are seen with prominence in significant trauma

**Fish tail sign.** This is associated with avascular necrosis of the trochlea.

**Crescent sign:** This is associated with the rotation deformity of the distal fragment. This normally results in cubitus varus

**CLASSIFICATION**

The simple classification used is

- Extension type
- and
- Flexion type

**GARTLAND'S CLASSIFICATION(1859)**

**Type-I** -Undisplaced or minimally displaced

**Type-II** -Displaced (angulation of the distal fragment with one cortex intact-ant/post)

**Type-III** -Displaced (both cortices are fractured. No cortical contact)

**WILKIN'S CLASSIFICATION:**

Wilkin's subdivided type III injuries according to the **coronal plane** displacement of the distal fragment- Posteromedial and Posterolateral

**TREATMENT**

Initial management of all patients suspected of having an elbow injury is splinting in 20 to 30 degrees of elbow flexion. The initial examiner should assess the neurovascular status and other injuries, including head injury and general cardiorespiratory status. Bandaging or splinting should not be tight. Excessive flexion or forced extension should be avoided, as they may compromise vascularity. A flexion reduction method is performed with thumb pressing over the olecranon and the distal condyles of the humerus. The elbow is then held in hyperflexion and pronation to achieve a stable reduction. The pulse is usually obliterated in this position, and the hand is pale. Circulation will be restored once the fracture is stabilized, and the elbow will be extended in nearly all cases. AP and lateral views are obtained using the image intensifier. With the elbow flexed, the actual AP view is taken by rotating the arm slightly medially and laterally to view the columns of the distal humerus. The arm is then externally rotated to obtain a lateral view of the distal humerus. The surgeon rotates the entire arm by placing one hand on the proximal humerus while the other holds the wrist pronated with the elbow hyperflexed. This is generally a stable position that will allow rotation of a reduced supracondylar fracture. The lateral image is then evaluated for distal humerus' cortical contour, fracture gap reduction, and presence of the anterior humeral line. Rotating the arm with the fracture reduced and held in a stable position is possible in nearly all posteromedially displaced supracondylar fractures. In posterolaterally displaced supracondylar fractures, however, the reduction is frequently unstable in hyperflexion and in pronation. If the fracture reduction is unstable, the C-arm should be rotated to obtain AP and lateral views rather than attempting to rotate the arm. An anatomic or nearly anatomic reduction is a prerequisite for skeletal stabilization. If this type of stabilization cannot be achieved by closed reduction or traction, open reduction can be used. Failure to achieve accurate alignment with closed means is an indication for open reduction. In patients in whom a closed reduction cannot be obtained, there is risk that entrapment of neurovascular structures prevents realignment and open reduction is indicated

**Percutaneous pinning:**

Before the advent of the fluoroscopy, blind pinning was done. Modern imaging techniques and improved power equipment have made percutaneous pinning the standard treatment. 2 types of pinning are used commonly. cross pinning is more stable than 2 lateral pins

**Crossed pinning technique**

Initially closed reduction of the fracture is done. Then the reduction is maintained and is confirmed with image intensifier before pinning. Always the lateral pin is inserted initially. The Position for inserting the pin is checked by c-arm on AP and lateral views. A small incision is made in the skin and pin is kept using power drill.

The pin should pass through the lateral portion of the ossified capitellum, cross the physis and engage the opposite medial cortex proximally. The 2nd pin is placed medially. Care should be taken so that the ulnar nerve is not injured. Incision is made over the skin of medial epicondyle. Then a blunt dissection is done, ulnar nerve identified, protected and the pin is inserted. The Pin which is placed through the medial epicondyle is more horizontal than the lateral pin.

**DORGAN'S LATERAL PINNING TECHNIQUE.**

The risk of injury to the ulnar nerve is less. It is less stable compared to crossed pin. Two pins are placed in a divergent manner in both AP and lateral views. Sometimes a third pin may be inserted on lateral or medial side if the fracture is found to be unstable. Good results can be obtained by separating the pins to a maximum at the fracture site. The medial and lateral columns should be engaged sufficiently. Bone in both the proximal and distal fragments also should be engaged. The goal is to have two pins that are divergent on the AP and lateral views. Two pins crossing at the fracture will produce a rotational deformity because torque will not be satisfactorily resisted. First pin is generally placed through the center of the ossified capitellum, cross the olecranon fossa and then penetrate the medial cortex. A second pin is placed through the distal humeral epiphysis lateral to the capitellum within the epiphysis. The pin passes up the lateral column and engages the opposite cortex. After stabilization of the fracture, the upper limb should be kept immobilised with forearm in neutral and elbow flexed at 60 to 90 degrees. Maximal pin separation increases the stability with this technique.

**6. MATERIALS AND METHODS:**

A prospective study was conducted at the orthopaedic department of Stanley medical college Hospital from June 2010 to June 2012. All the children with displaced supracondylar fractures of the humerus who presented to the orthopaedic outpatient or casualty were included for the study.

**INCLUSION CRITERIA:**

1. children of age group-2years to 13 years[both sex]
2. those who presented within 0-4days after injury
3. no previous fracture within the same elbow
4. no associated fracture within the same bone

**EXCLUSION CRITERIA:**

1. age group <2years and >13years [both sex]
2. open fractures
3. fractures presenting >4days after injury.

All the children with suspected supracondylar fractures of elbow were seen either at casualty or orthopaedic outpatient department by the orthopaedic surgeon. They were assessed for vascular and neurological complications. Anteroposterior and lateral radiographs were done. All displaced extension type supracondylar fractures were admitted. The injured elbow was immobilized in 30 to 45 degree of flexion with plaster of paris Pulseless viable limb and nerve injuries were also included for the study. Patients were reassessed in the ward for neurovascular injuries and any other associated injuries. Surgery was planned on the same day or the next day after obtaining written informed consent. Patients were randomly selected for the type of fixation. Surgical techniques were standardized in terms of pin location, the pin size (weight less than 20.kg size 1.5mm; more than 20 kg 2mm.), stability on table, position of elbow for medial and lateral pin placement and the postoperative course.

General anaesthesia was used for all the patients with injured upper limb at the side of the table. The injured elbow was placed on the plate of image intensifier which was adequate for the surgery due to the small size of the elbow. Closed reduction was done and confirmed by image intensifier. If acceptable, assistant would clean and drape the limb along with image intensifier and surgeon goes

for scrub. Fracture would be reduced again and fixed under image intensifier according to the selected configuration.

For the lateral fixation technique two or three pins were inserted from lateral aspect of elbow across the lateral cortex to engage the medial cortex. The elbow should be kept in hyperflexion. For the pin construct to be acceptable and biomechanically stable one pin had to be placed in lateral column and another in central column. Pins were placed either in parallel or divergent configuration with the adequate separation at fracture site.

**Clinical evaluation** was done by senior orthopaedic surgeon. This includes the following

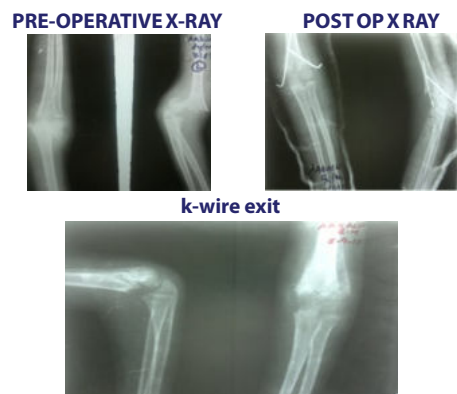
1. passive range of motion
2. measurement of carrying angle
3. Neurovascular status

**FLYNN CRITERIA FOR REDUCTION ASSESSMENT**

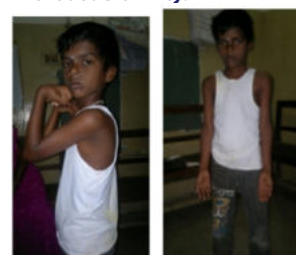RESULTS	Cosmetic factor-loss of carrying angle (degree)	Functional factor - loss of motion (degree)
Excellent	0 – 5	0 – 5
Good	6 – 10	6 – 10
Fair	11 – 15	11 – 15
Poor	> 15	> 15

Clinical evaluation was graded according to carrying angle and elbow range of motion using the criteria of Flynn et al.

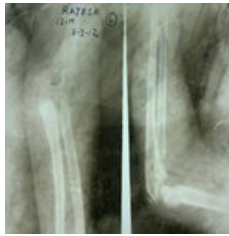
Radiographic evaluation was performed by anteroposterior and lateral radiographs of the elbow. Satisfactory fixation was confirmed intraoperatively under image intensifier and radiograph taken. Follow up radiographs were taken at one week, two weeks, four weeks, six weeks, three months and six months. Baumann angle and humero-ulnar angle were calculated on the immediate radiographs and after three months for any loss of Baumann angle and humero-ulnar angle. At the three months and six months follow up child were evaluated for full function, minor limitation of function and major loss of function. Iatrogenic ulnar nerve injury was evaluated immediately postoperatively who had normal ulnar nerve function on the preoperative examination. Any patients with immediate post operative ulnar nerve deficit was explored again and the pin was placed in other location. All data were compiled and calculated.



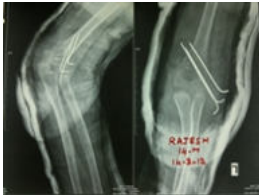**Clinical follow up done in 3 months showed excellent elbow range of motion without deformity.**



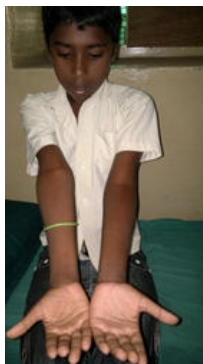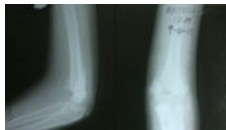
## Case-2 preop photo



## post op photo



## k-wire exit



In our study male children are predominantly involved.  
In our study the non-dominant limb is predominantly involved.

## ANALYSIS OF RESULTS

All patients were followed up regularly and evaluated clinically And radiologically for fracture union and other complications.

1. Primary bony union : 24cases
2. Delayed union : nil
3. Non Union : nil
4. varus Angulation : nil
5. Malrotation : nil
6. Elbow Stiffness : 4 cases
7. Infection : 1 case
8. Implant failure : nil
9. Duration of follow up : 3weeks post op to 6 months (average

3months)

10. Average operating time 30 minutes
11. Average time for fracture union radiologically 3.5 weeks.
12. Average elbow flexion 135\*
13. Average valgus angle 14\*
14. Average Baumann's angle is 16\*
15. In 20 patients with excellent results there was no shortening, malalignment, no pain or swelling in the fracture site. The range of movements of the elbow are near normal.
16. In 4 patients with open reduction and pinning , decreased elbow flexion of <125\* was present due to postoperative elbow stiffness.

## DISCUSSION

Fractures of the supracondylar humerus is usually as a result of the fall injury .It is accompanied by complications like neurovascular injury, compartment syndrome , myositis ossificans and varus deformity . The **therapeutic goals** in the treatment of this fracture are avoidance of elbow deformity, prevention of neuro vascular injury,early mobilization and functional rehabilitation of the limb.Complex supracondylar fractures are Uncommon in children and usually caused by high energy violence. We considered fracture to be united clinically when there is no tenderness or pain during elbow movement . Radiological union is said to occur when there is radiographically bridging callus with cortical density connecting both the columns in both the views of x-rays.Closed pinning with k-wires has proved to be the effective method in the treatment of the fracture of supracondylar humerus in children..The k-wires act as an internal splint and provide rigidity and rotational stability. The child who sustain this type of fracture frequently may have associated neurovascular injuries .Hence stabilization of the patient is the first objective in treatment .Bone union and restoration of function are the important goals. In some improperly stabilised fractures union of the distal segment is delayed In our study all the patients had good fracture union. There were also no significant differences ( $p > 0.05$ ) between groups with respect to the Baumann angle, humerocapitellar angle, Flynn grade, carrying angle, elbow flexion, elbow extension, total elbow range of motion, return to function, or complications. The use of cross pinning to achieve fracture union requires meticulous technique. The risk of iatrogenic ulnar nerve injury is increased but the fixation is better and more rigid when compared to lateral pinning. Due to high rate of complications associated with this type of fixation, most of the traumatologists have advocated lateral pinning as safer in closed pinning. Early mobilization is thought to reduce the post operative complications, to maintain joint motion and to decrease the hospital stay.In our study of 24 patients ,for 17 patients cross pinning was done.The remaining 7 patients were fixed with lateral pinning.The study revealed shorter surgical time[mean 25 minutes vs 35 minutes mean for cross pinning],less skill needed,less complication in lateral pinning compared to cross pinning.

## CONCLUSION

Our study consists mostly of children in the age group of 3 to 13 with the mean age of 7years.There is a need for early and emergency fixation as it is the growing age of bone. This becomes necessary to prevent any future deformities and complications. Pinning with k-wires for displaced supracondylar humerus fractures has been established world wide as the gold standard treatment .The k-wires exit is done after a relatively shorter duration [3 weeks].This is advantageous. These contribute to the stable osteosynthesis and rapid union . Early mobility, a low rate of complications and high incidence of union obtained in this study in majority of patients using both the techniques makes them more reliable.

## References:

1. Wilkins KE: Supracondylar Fracture of the Distal Humerus. In: ROCKWOOD CA, Wilkins KE, Beaty JH. (editors) Fractures in Children.4th ed. Vol. 3. Philadelphia, Lippincott - Raven; 1996.669-752.
2. Herring JA, editor. Fracture about the elbow. In: TACHDJIAN'S Pediatric Orthopaedics.3rd ed. Vol. 3. Philadelphia:W.B. Saunders; 2002. 2139- 221
3. JBJS- Volume 89, Issue 4 Lateral Entry vs cross Pin Fixation for Completely Displaced Supracondylar Humeral Fractures in Children-Mininder S. Kocher et al

4. September 01, 2001 The Posterior Fat Pad Sign and Use of Comparison Radiographs in the Diagnosis of Occult Fractures Leonard E et al
5. The Journal of Bone & Joint Surgery, Volume 86, Issue 4 Scientific Articles | April 01, 2004 Lateral-Entry Pin Fixation in the Management of Supracondylar Fractures in Children David L. Skaggs et al
6. The Journal of Bone & Joint Surgery, Volume 90, Issue 5 Current Concepts Review | May 01, 2008 Supracondylar Humeral Fractures in Children Reza Omid et al
7. The Journal of Bone & Joint Surgery, Volume 89, Issue 4 Scientific Articles | April 01, 2007 Loss of Pin Fixation in Displaced Supracondylar Humeral Fractures in Children: Causes and Prevention Wudbhav N. Sankar et al
8. Arino et al. Percutaneous fixation of supracondylar fractures of the humerus in children. *J Bone Joint Surg Am* 1977;59:914-6.
9. Dogde HS. Displaced Supracondylar Fractures of Humerus in Children: Treatment by Dunlop's Traction. *J Bone Joint Surg [Am]*. 1972;54-A:1408-18.
10. Worlock et al Severely Displaced Supracondylar Fractures of Humerus in Children: A Simple Method of Treatment. *J Pediatr Orthop*. 1987;7:49-53.
11. Smith FM. Kirschner's Wire Traction in Elbow and Upper Arm Injuries. *Am J Surg*. 1947;74A:700-87.
12. Mazda et al Systemic pinning of displaced extension type supracondylar fractures of the humerus in children. *J Bone Joint Surg [Br]*. 2001;83-B:888-93.
13. Shannon and Mohan P: "Dorgan's" Percutaneous lateral cross-wiring of supracondylar fractures of humerus in children. *J Pediatr Orthop*. 2004;24:376-9.
14. Gordon JE et al Fracture stability after pinning of displaced supracondylar distal humerus fractures in children. *J Pediatr Orthop*. 2001;21:313-8.
15. Skaggs DL et al. Lateral-entry pin fixation in the management of supracondylar fractures in children. *J Bone Joint Surg Am*. 2004;86:702-7.
16. Skaggs DL et al Operative treatment of supracondylar fractures of the humerus in children. The consequences of pin placement. *J Bone Joint Surg Am*. 2001;83:735-40.
17. Fowles JV et al. Displaced supracondylar fractures of the elbow in children. A report on the fixation of extension and flexion fractures by two lateral percutaneous pins. *J Bone Joint Surg Br*. 1974;56:490-500
18. Belhan et al Dynamics of the ulnar nerve after percutaneous pinning of supracondylar humeral fractures in children. *J Pediatr Orthop B* 2009 Jan; 18(1):29-33.
19. Brown et al Traumatic and iatrogenic neurological complications after supracondylar humerus fractures in children. *J Pediatr Orthop*. 1995;15:440-3
20. Lyons JP et al Ulnar nerve palsies after percutaneous cross-pinning of supracondylar fractures in children's elbows. *J Pediatr Orthop*. 1998;18:43-5.