IF : 4.547 | IC Value 80.26

VOLUME-6, ISSUE-6, JUNE-2017 • ISSN No 2277 - 8160

Original Research Paper

Radiology

ULTRASOUND DIAGNOSIS CRITERIA FOR TYPHOID FEVER

Dr. Sushil J. Sikchi

Department of Radiology, Punjabrao Deshmukh Memorial Medical College, Amravati India

ABSTRACT

The diagnosis of typhoid fever is usually obvious, but it can be difficult when the clinical findings are not typical. The disease is curable, but the mortality rate from typhoid fever in the Western world is still about 2%. In many developing countries Typhoid fever is a major health problem. In India it is the fifth most common infectious disease, and its clinical features are similar to other types of bacterial enterocolitis.

This is at least partly due to a delay in diagnosis, which occurs either because the disease is initially not considered or because definitive blood cultures require at least 18-36 hr and in widal test patients take over a week to show positive results . Imaging techniques have not been used in the diagnostic approach to typhoid fever. This study aims at establishing the efficacy of ultrasound in early diagnosis of typhoid fever and access the correlation with Widal test & blood culture study.

KEYWORDS : typhoid fever, ultrasound, widal test.

INTRODUCTION

In many developing countries Typhoid fever is a major health problem . In India it is the fifth most common infectious disease, and its clinical features are similar to other types of bacterial entero colitis. Enteric fever is caused by Salmonella typhi and paratyphi Bacilli. Atypical clinical findings make clinical diagnosis difficult. Definative diagnosis of typhoid fever is made by hemoculture & serological tests , namely Widal test. Both require some days to over a week to show positive results. Improper & inadequate use of antibiotics leads to sterile cultures adds to the difficulty in diagnosis. Imaging techniques have not been used in the diagnostic approach to typhoid fever. This study aims at the efficacy of ultrasound in early diagnosis of typhoid fever and access the correlation with Widal test & blood culture Study.

Widal test is the most commonly used method of detecting Typhoid fever, but does not provide results until a week after onset of fever due to the need for enough antibodies to develop to render a positive result. Abdominal Ultrasound was performed within three days of the onset of fever in selected group of patients. Follow-up scans were performed at five days, ten days and fifteen days. Subsequently, Widal positive and Salmonella culture was positive in 42 cases. We present our findings in 24 patients in the age group between 5 to 25 years in whom both Widal test and Salmonella culture positive.The Ultrasonography findings were as follows: splenomegaly (n-24, 100%); Bowel wall thickening (n-13, 54%); Mesenteric Lymphadenopathy(n-11,46%); thickened gall bladder (n-11, 46%); biliary sludge (n-6, 18%); positive Ultrasound Murphy's sign (n-7, 0.29%); pericholecystic edema with increased vascularity (n-3, 12%). In endemic areas like India, ultrasound findings of splenomegaly, ileal and cecal wall thickening, mesenteric lymphadenopathy and thick-walled gallbladder are diagnostic features of typhoid. Ultrasound can be a non-invasive, economical and a reasonably sensitive tool for diagnosing typhoid when serology is equivocal and cultures are negative, was subsequently positive.

MATERIALS AND METHODS

This study was conducted between June 2013 to July 2015 on hundred and five patients. Hundred and five patients have been clinically suspected with typhoid fever in central hospital. All the hundred and five found to be widal positive. Salmonella culture was positive in 42 patients.

The 42 of these patients formed the study group, Ranged from 5 years to 50 years. The 24 patients are less than 25 yrs. This form the study group of 24 patients (m-15; f-9).

Abdominal Ultrasonograph examination was performed within one to five days of hospital admission. We used a convex transducer with frequency of 3.5 to 5 Mhz and a linear transducer of a frequency of 7 to 9 Mhz on Japanese Toshiba / GE machine.

Whole of the abdomen was scanned by ultrasound for any abnormalities in all the clinically suspected patient . Each of the quadrant of abdomen was meticulously scanned by Ultrasound. All ultrasound examinations were started with the examination of the liver wherein size & echotexture were noted. The gall bladder was next examined, concentrating on its size, luminal contents ,and wall-thickness. Wall thickness more than 4mm considered abnormal in our study

More attention is given to the changes in small bowel and presence of mesenteric lymphadenopathy. Specifically, the terminal ileum and cecal wall thickness. Wall thickness is measured by putting the cursor from inner hyperechoic layer to outer hyperechoic layer. The wall thickness at ileum more than 3mm is considered abnormal in this study. Color Doppler scan was also used specifically for inflammatory response (increased vascularity) in gall bladder wall . We also look for pleural spaces, pelvic region for any fluid. Follow up scan was performed to assess the response of drug therapy.

RESULTS

All 24 patients study group was scanned by Ultrasonography and findings were noted. Following are the observations we got during the ultrasonography of this group.

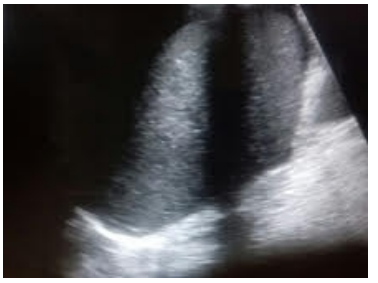

Figure 1: Splenomegaly with free fluid in abdomen.

Figure 2:Ascites in lower abdomen

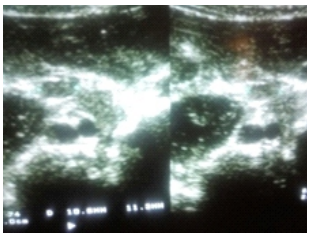

Figure 3:Enlarged mesenteric nodes

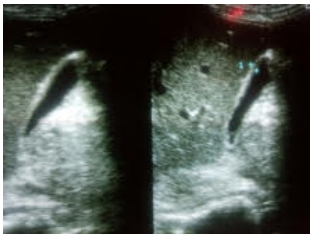

Figure 4: Increased gall bladder wall thickening

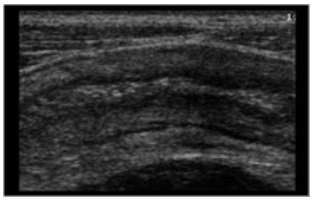

Figure 5. High frequency sonography shows smallBowel wall thickening

Figure 6. Right Sided Pleural effusion

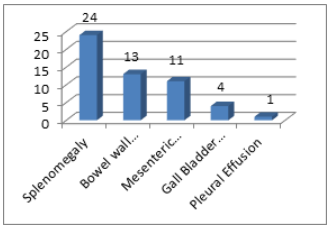

Figure 7 : Major positive findings on US in cases of typhoid fever major positive findings

OBSERVATIONS:

1. Mild splenomegaly-24(100%).
2. Gall bladder wall thickening (Acalculus cholcystitis)
3. Small Bowel wall thickening
4. Enlarged mesenteric lymphnode are noted.
5. Minimal free fluid seen in lower abdomen.
6. Pleural fluid is also seen

FINDINGS

1. Mild splenomegaly is the consisitent feature found in all the patients who has widal positive and Salmonella culture positive group. Spleen is normal in texture. No focal lesion is seen in spleen. No evidence of any hypochoic lesion is seen (Figure 1).
2. Gall bladder changes- Most commonly gall bladder wall thickening is seen in 4 cases out of 24 cases. Four patient show acalulus cholesystetitis . No Significant findings are seen in color flow imaging. All cases are called for followup. To observe the response of treatment . They all showed reslolution of gall bladder wall thickening And acalculus cholesystetitis after 15 days (Figure 4).
3. Small bowel wall thickening - 11 patient show ileal wall thickening and two patient show cecal wall thickening (Figure 5).
4. Ascitis is seen in 4 cases. It resolved after 15 days with adequate medical line of treatment (Figure 2).
5. Right sided pleural effusion is seen in one patient which well responded with the treatment (Figure 6).
6. Mesenteric lymphodepathy. Lymph nodes seen 10 to 18 mm in diameter. They are oval in shape and they become inconspicuous after the treatment after 15 days (Figure 3).

DISCUSSION

Typhoid fever is caused by Salmonella typhii ingested oraly and multiplied in the lymphoid tissue in the illeocecal region. The disease is endemic in various parts of india. Usually the diagnosis of typhoid fever is difficult to establish in early week. Rising widal titres and blood culture are positive after 10-15 days. At the same time there are other reasons for the fever which mimic clinically like typhoid fever. It is come to the fact that sonography can establish a definitive diagnosis of typhoid fever in early phase and assess the response of the therapy in affected patients by the follow up study. The common Ultrasonography findings in typhoid are Spleenomegally, thickening of the wall of the terminal ileum and cecum. Mesentric lymphadenopathy and Gall Bladder wall thickening.

We found the similar Ultrasonography findings of Spleenomegally, thickening of the wall of the terminal ileum and cecum. Mesentric lymphadenopathy and Gall Bladder wall thickeing.

The findings like Splsenomegaly, Mesentric lymphadenopathy and terminal bowel wall thickening with clinical picture is highly suggestive to establish the diagnosis of typhoid fever if there are other minor features like gall bladder wall thickening and ascitis are present then the specificity and sensitivity of Ultrasonography in the diagnosis of Typhoid fever increases manifold.

Even the Bowell wall thickening is typical for typhoid fever is typical at terminal ileum. In tuberculous entritis the bowel wall texture is not maintained. Whereas in typhoid fever bowel wall texture is maintained.

Clinically suspected typhoid fever patients came with a complaint of pain in abdomen in which Ultrasonography is the effective tool in differentiating other pain causing conditions like appendicitis, abscess & diverticulitis.

In short, clinical picture and Ultrasonography findings are almost diagnostic for typhoid fever even when the Widal test is negative in early phase of disease, not only the diagnosis follow up Ultrasonography also assess the progression of the disease and response to the medical line of therapy.

The advent of high resolution, high frequency transducers has helped in measuring the bowel wall thickness in healthy subjects and in intestinal disorders . Increase in thickness of the terminal ileum and enlargement of the regional nodes in Typhoid fever was reported by Puyleart in 1984. In 1997 Terantino et. al reported similar findings in 95 patients of confirmed Typhoid (5). These findings were also reported in Yerciniaand Campylobactor jejuni enterocolities by Puyleart in 1988 (6). In tuberculosis enteritis by Lee et al in 1993 (7). And in inflammatory bowel diseases. The sensitivity and specificity for diagnosis of Typhoid patients admitted with fever was described by Tarantino was 64.8% and 81.4% respectively and accuracy of 77.4%.

CONCLUSION

In endemic areas ultrasound findings of Splenomegaly, thickening of the ileum and cecum and multiple enlarged mesenteric nodes,

with or without dilated thick walled Gall bladder is diagnostic of typhoid fever particularly when serology is equivocal and cultures are negative and not available. Ultrasound is a nonevasive, easily available , economical , well acceptable and fairly sensitive investigation for the early diagnosis of the typhoid fever.

REFERENCES:

[1] Gerald T. Keush. Salmonellosis . In Fauci AS. Braunwald E, Isselbacher KJ et al eds.Harrisons Principles of Internal Medicine, 14 th ed. New York: McGraw Hill, 1998;950-956

[2] Hook EW. Guerrant RL. Salmonella infections. In Braunwald E, Isselbacher KH et al, eds Harrisons Principles of Internal Medicine, 11 th ed. New York: McGraw Hill, 1987;592-596

[3] Puyleart JBMC, Mesentric adenti and acute terminal ileitis:US evaluation using graded compression.Radiology 1986;161:691-695.

[4] Puyleart JBMC,Kristjansdottir S,Golterman KL, Gerald MJ, Nelly MK. Typhoid fever:Diagnosis by using Sonography. Am J. Radiol 1989; 153:745-746.

[5] Tarantino L,Giorgio A. Value of bowel ultrasonography in the diagnosis of Typhoid fever . Eur J lltrasound 1997;5:77-83.

[6] Puyleart JBMC , Lalisang RI, Van der werf SDJ et al. Campylobacter ileocolitis mimicking acute appendicitis: differentiation with graded compression US. Radiology 1988; 166:737-740.

[7] Lee DH. Sonographic findings of intestinal tuberculosis.J Ultrasound Med 1993;12:537-540.

[8] Lim JH, Ku YT,Lee DH et al. Sonography of inflammatory bowel diseases. Am J Radiol 1994; 163: 343-347.

[9] M.A.Mateen et al. , Ultrasound in The Diagnosis of Typhoid Fever

[10] P. Balakrshna Shetty et al. , Sonograp[hic Analysis of GallBladder Findings in Salmonell;a Fever.