VOLUME-6, ISSUE-5, MAY-2017 • ISSN No 2277 - 8160

Original Research Paper

Gynaecology

OVERCOMING PROXIMAL TUBAL BLOCK ON O.P.D BASIS: A Study of 61 cases.

DR. SANDEEP S. POPHALE

M.B.B.S., M.S. (OBST & GYNAEC.) Ex Assistant Professor of Obstetrics & Gynaecology, Lokmanya Tilak Municipal Medical College & Lokmanya Tilak Municipal General Hospital

ABSTRACT

Modern treatment of infertility derives its foundation from the division of causes of infertility into various 'factors'. Our study concerns the tubal factor of infertility.

Tubal factor causing infertility is not just a simple entity; it comprises several factors which include:

1. Whether it is a proximal , midsegment, or a distal block
2. The pathology causing the block.
3. Whether there is an exosalpingitis or endosalpingitis.
4. What is the condition of the milieu interior of the fallopian tube?

This is a study of 61 cases over a 3 year period of proximal tubal block which have undergone fallopian tube catheterization under image intensifier vision using Jansen-Andersen tuboplasty set on O.P.D basis.

KEYWORDS : INFERTILITY, NON-INVASIVE, TUBAL BLOCK, ECONOMICAL, PATENCY

BACKGROUND

The fallopian tube is not a simple passage for the passive movement of sperms and oocytes ; neither is it the mistletoe under which the sperm and ova unite to form a zygote.

In fact, the fallopian tube is a dynamic organ composed of an internal mucosa formed by ciliated epithelium which undergoes cyclical changes in accordance with hormonal changes of menstrual cycle, just like the endometrium.

The tubal fluid has its own immunological, electrolyte and neuro logical dynamics which facilitates the spermatozoa to be propelled towards the ovum.

Tubal IgA levels are extremely important in prevention of tubal block in pelvic inflammatory diseases.

AIMS AND OBJECTIVES

Our study concerns only proximal tubal block. Proximal tubal block can be dealt with primarily by 3 modalities:

1: Surgical: Open or laparoscopic implantation of the tube.
2: Hysteroscopic cannulation
3: On O.P.D. basis with the help of Jansen-Andersen tuboplasty set under image intensifier.

INCLUSION CRITERIA

Number of Patients: 61

1: Patients with proximal tubal block.
2: Reproductive and child bearing age group complaining of infertility.
3: No active P.I.D. or local genital tract infection.
4: Desirous of treatment on O.P.D. basis with minimal hospital stay and expenses.
5: No other compounding factor.

MATERIAL AND METHODS

The Jansen –Andersen tuboplasty set consists of the following parts.
1: A 5.5 Fr 2mm cornual catheter.
2: A highly malleable, very thin and almost friction free Teflon guide wire.
3: A thin tubal canola which slides over the tungsten guide wire.

The patient is started on oral antibiotics one day prior to the procedure. She is advised a light meal on previous night and a good laxative to ensure minimal gas shadows. Half an hour Number of Patients: 61r before the procedure the patient is given a dose of atropine to minimize the risk of vasovagal attack. A diclofenac rectal pesary and an injection of hyoscine bromide to minimize the chances of tubal spasm are also given.



Fallopian Tube Catheterization Set

TECHNIQUE

Under all aseptic precautions the patient is first made to undergo a pilot HSG so that the cornual tubal block can be demonstrated.

This is the pilot HSG plate of a patient whose proximal tubal block can be demonstrated.

Now the 5.5 fr catheter is steered into the concerned cornua and there is a Luer lock that helps it retain its position.

An attempt is then made to pass the dye through this catheter. In occasional cases of severe tubal scarring or if the patient is in pain the tubes go into a spasm, the tubes appear blocked even if they are not.

This procedure helps to overcome the same.

Now, the highly malleable Teflon guide wire is advanced slowly into the fallopian tube and following this the tubal cannula is advanced over the guide wire.

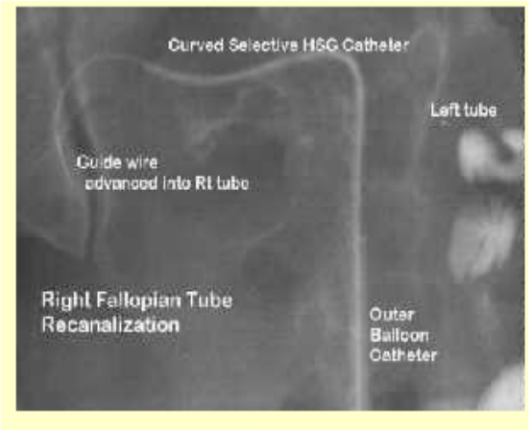

Representative image of tubal cannulation.

The guide wire is now pulled out and the dye is re-instilled. The spillage of the dye will be demonstrated.

The tubal cannula and the cornual catheter are both removed and an HSG is done thereafter to demonstrate if the tube has finally become patent or not.

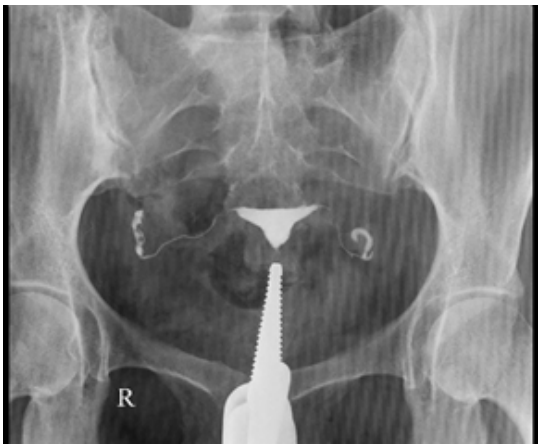

The dye now flowing through the left tube.

RESULTS

Of these 61 cases over a three year period,
44 cases resumed patency of the proximal tube which can be demonstrated at the end of the procedure.

In 3 cases, the procedure the procedure had to be abandoned due to excessive tubal scarring.

12 patients conceived an intrauterine pregnancy.

There were 3 ectopic pregnancies.

COMPLICATIONS

We had no complications during our procedure but the possible complications include:

1: Anaphylaxis to the dye
2: Vasovagal shock
3: Perforation of the uterus.
4: Infections.

DISCUSSION

Uterine insufflations with gas or iodinated contrast agent were used at the time of ovulation in the period as early as 1940 (3). Thurmond et al had used co-axial catheter in 1988 for selective cannulation of uterine cornua with success rate of 94%.(4)

High recanalization rate in our series is also reported by other studies (2,3) indicates, that the abnormality in most of the tubes is probably occlusion of tubes due to amorphous debris and mild adhesions (1). Such obstruction may very well be resistant to hydrostatic pressures that can be exerted during conventional hysterosalpingography but can be overcome by fallopian tubal canalization procedures.

Since organic occlusions are for less common than tubal spasms some authors believe that at least two attempts of diagnostic hysterosalpingography should be made before resorting to alternative of selective connulation (5).

We believe that this fallopian tube recanalization tech ique is relatively inexpensive and has very low morbidity, above study also conclude that the procedure could be performed during hysterosalpingography itself with significant saving in terms of time and cost and thus the necessity of more invasive Laproscopic procedures can be avoided.

CONCLUSION

Following are the advantages of this procedure:
1: Patient friendly.
2: Economical.
3: Negligible complications.
4: No anesthesia required and hence, can be done on an O.P.D. basis.

However this is still not a very popular procedure and the radiologist and the gynecologist should work in unison to make available this option for suitable patients.

REFERENCES

1. M.C. Comb, Gomel, Cornual occlusion and its microsurgical reconstruction, clinical obstetrics gynecology 1980; 23:1229-1241
2. Rosch J, Thurmond AS, Uchida BT. Fallopian tube cathete rizati on technique update. Radiology 1988;168;1
3. Verell M. Mudltiple uterotubal insufflations in cases of sterility due to tubal occlusion AM. J Obstet Gynecol 1954;68;810-814
4. Thurmond AS, Rosch J, Fallopian tubes improved technique for catheterization Radiology 990;174;572- 573.
5. Thurmond AS, Rosch J, Novy, terbutaline in diagnosis of interstitial Fallopian tube obstruction. Invest Radiol 1988; 23; 209-210.