VOLUME-7, ISSUE-12, DECEMBER-2018 • PRINT ISSN No 2277 - 8160

Original Research Paper

Pathology

CLINICOPATHOLOGICAL STUDY OF SALIVARY GLAND TUMORS: A THREE YEARS PROSPECTIVE OBSERVATIONAL STUDY

Dr.G.vandana	Associate Professor,
Dr.Khushboo Ghanshyani*	Post graduate, *Corresponding Author
Dr. Mohd anwar miya	Associate Professor,
Dr. S.Sandhya	Head of department

ABSTRACT

Background: The salivary glands are one of the few tissues in the body that are subjected to diverse and heterogeneous range of tumors and tumor like conditions. The relative infrequency of these tumors makes their diagnosis and management quite complicated. Fine needle aspiration cytology (FNAC) is a useful diagnostic procedure which has a recognized role in the evaluation of salivary gland lesions. A pre-operative diagnosis about nature of lesion, whether benign or malignant, will help in making decision about proper management of patient.

Aim and Objective: Aim of this study was to know the epidemiology of salivary gland tumors in our region and to evaluate sensitivity, specificity and diagnostic accuracy of fine needle aspiration cytology taking histopathology as the gold standard.

Material and Method: It was 3yrs prospective observational study conducted from oct 2015 to oct 2018 in department of pathology KMC/MGM Hospital. Total 59 cases were studied with particular reference to age, sex, site, cytologic details & histological types as per WHO classification. FNAC & histopathological examination was done in all cases came to pathology laboratory . Correlation between cytological & histopathological diagnoses was assessed. Diagnostic accuracy of FNAC was evaluated by comparing cytological & histopathological diagnoses.

Results and Discussion : Parotid gland was the most common site of involvement (70% cases). Maximum number of patients was in age range of 41-50 years & male to female ratio was 0.8:1. Most common benign & malignant tumors were pleomorphic adenoma (69.89% cases) & mucoepidermoid carcinoma (8.60% cases) respectively. On cytology, 54 cases while on histopathology 57 cases were diagnosed as neoplastic. Cytological diagnoses correlated with histopathological diagnoses in 94% cases. Sensitivity, specificity & diagnostic accuracy of FNAC were found to be 96.87%, 100% & 96% respectively.

Conclusion: FNAC in salivary gland masses is fairly reliable for correct preoperative diagnosis. Multiple sampling and special attention to cytologic features should help to minimize errors.

KEYWORDS : Salivary gland tumors, FNAC, WHO classification

INTRODUCTION;

The salivary gland tumors constitute less than three percent of all head and neck tumors (Ahmed et al.)1 and this relative infrequency makes their diagnosis and management quite complicated. Identifying malignancy pre-operatively is crucial as it can have significant impact on management

Fine needle aspiration cytology is a useful diagnostic procedure which has recognized role in the evaluation of these lesions. Histopathology is the gold standard as it avoids diagnostic pitfalls of FNAC. Aim of study was to know the epidemiology of salivary gland tumors according to WHO classification & diagnostic accuracy of FNAC taking histopathology as the gold standard

METHODS:

It was a single institute, 3yrs prospective study done from oct 2015 to oct 2018. Prior written consent was taken from all patients and permission from ethical committee was taken. All patients with salivary gland masses presented in ENT OPD of MGM Hospital,Warangal were included in the study. Patients with salivary gland lesions who were diagnosed as inflammatory lesions on FNAC and didn't go for surgery were excluded from the study, since no histopathological material was available for follow up study. Total 59 cases were studied. All patients went for FNAC examination using Hematoxylin and Eosin (H&E) staining. Data was recorded as number of aspiration attempts, adequacy of smears, and cytomorphologic details. All included patients underwent histopathological examination of the specimen. Grossly, size, surface, encapsulation, cut surface- color, consistency, contents of cystic spaces, hemorrhagic and necrotic areas were examined. Microscopic examination was done with H&E staining. Salivary gland tumors were classified as per WHO classification and comparison was done between FNAC and histopathological diagnosis. Associated pathology if any was also recorded

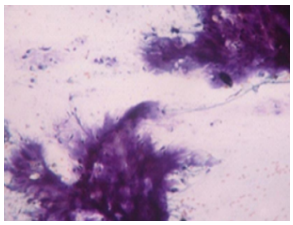

Condromyxoid with loosely cell – pleomorphic adenoma

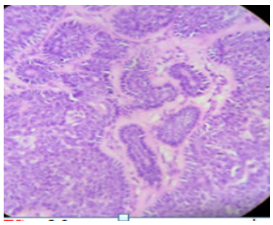

basal cell adenoma

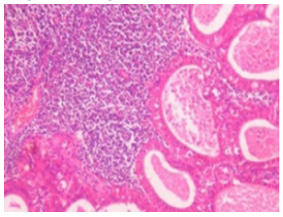

Warthins tumor

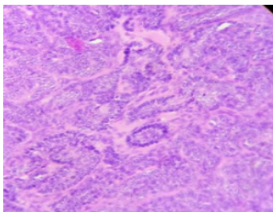

Monomorphic adenoma

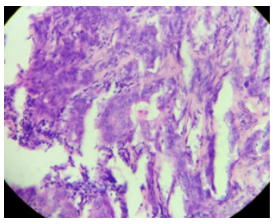

Salivary duct cell carcinoma

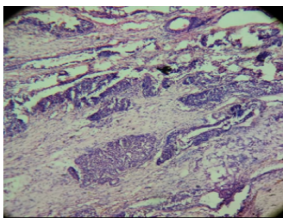

pleomorphic adenoma ex

carcinoma

RESULTS : Most common presenting complaint was painless swelling. We recorded cases in between 40 to 80 yrs age group. Maximum number of patients 19 cases was seen in the age range of 41-50 years, as shown in Figure 1. Mean age for benign tumors was 40.36 years while mean age for malignant tumors was 40.76 years.

Figure 1 : AGE AND SEX WISE DISTRIBUTION OF SALIVARY MASSES

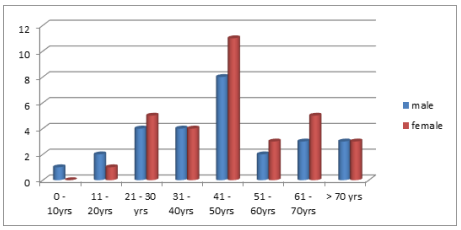

Twenty seven were male patients and thirty two were female patients with the male to female ratio of 0.8:1. Parotid gland was the most common site of involvement in 70% cases followed by submandibular gland in 24% cases out of 59 salivary gland masses, as shown in Figure 2

Figure 2 : SITE DISTRIBUTION OF SALIVARY GLAND MASSES

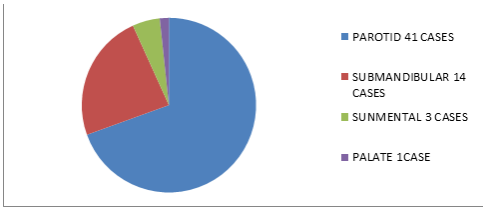

Out of 100 aspirates, 55 were diagnostic on first attempt & four cases required repeat aspiration. On cytology, four cases were non-neoplastic and 55 cases were neoplastic. Among 55 neoplastic masses, 44 cases were benign and 11 cases were malignant on cytology. Pleomorphic adenoma 38 CASES was most common benign tumor and mucoepidermoid carcinoma 5 cases was most common malignant tumor followed by adenoid cystic carcinoma 3 cases , as shown in Table 1. Facial nerve paralysis was seen in three cases of malignant tumors.

TABLE 1 : CATEGORISATION OF NEOPLASTIC SALIVARY LESION

BENIGN	No. OF CASES	MALIGNANT	No. OF CASES
PLEOMORPHIC ADENOMA	38	MUCOEPIDERMOID CARCINOMA	05
WARTHIN TUMOR	02	ADENOID CYSTIC CARCINOMA	03
BASAL CELL ADENOMA	03	SALVARY DUCT CELL CARCINOMA	02
MONOMORPHIC ADENOMA	01	CARCINOMA ex PLEOMORPHIC ADENOMA	01
TOTAL	44	TOTAL	11

In the present study, salivary gland lesions were studied as per the classification given in second edition of the World Health Organization's Histological Classification of Salivary Gland Tumor. On histopathology, four cases of pleomorphic adenoma were associated with acute sialadenitis and one case of mucoepidermoid carcinoma were found to be associated with chronic sialadenitis On cyto-histopathological co-relation, 94% cases were correctly diagnosed on FNAC as shown in Table 2

TABLE 2 :- CYTO- HISTOPATHOLOGICAL CORRELATION

HISTOPATHOLOGICAL DIAGNOSIS	No. OF CASES	FNAC Diagnosis		ERROR IN CYTODIAGNOSIS
		Consistent	Inconsistent	
BENIGN LYMPHOEPITHELIAL CYST	02	02	-	-
SEBACEOUS CYST	01	01	-	-
MUCOCELE	01	01	-	-
PLEOMORPHIC ADENOMA	38	38	-	-
WARTHIN TUMOR	02	01	01	MUCOCELE
BASAL CELL ADENOMA	03	03	-	-
MONOMORPHIC ADENOMA	01	01	-	-
MUCOEPIDERMOID CARCINOMA	05	04	01	PLEOMORHIC ADENOMA ex CARCINOMA
ADENOID CYSTIC CARCIINOMA	03	03	-	-
SALIVARY DUCT CELL CARCINOMA	02	02	-	-
CARCINOMA ex PLEOMORPHIC ADENOMA	01	01	-	-
TOTAL	59	57	02	-

On clinic-histopathologic co-relation, clinically 45 cases were correctly diagnosed

TABLE 3 : CORRELATION OF CYTOLOGICAL DIAGNOSIS WITH CLINICAL AND HISTOPATHOLOGICAL DIAGNOSIS

HISTOPATHOLOGICAL DIAGNOSIS	No. OF CASES	CLINICAL DIAGNOSIS		CYTOLOGICAL DIAGNOSIS	
		consistent	inconsistent	consistent	inconsistent
NON-NEOPLASTIC	04	01	03	04	-
BENIGN NEOPLASM	44	35	09	43	01
MALIGNANT NEOPLASM	11	07	04	09	02
TOTAL	59	43	16	56	03

Sensitivity, specificity and diagnostic accuracy of FNAC for neoplasms was found to be 89.58%, 100% and 90% respectively. P value for FNAC between positive and negative cases for neoplasm was found to be 0.001 which was considered highly significant

DISCUSSION : Only a few recorded analysis of salivary gland tumors based on significantly large number of cases are published from India. The present study involves all cases of salivary gland tumors which presented in ENT OPD with histopatholocal study from our institute during october 2015 to October 2018.

Age Distribution :- Salivary gland tumors were observed in all ages ranged from six to 80 years but the highest incidence was in fifth decade. Similar wide age range has been observed by other authors. Frable and Frable (1991)2 reported age range of two to 93 years. Cristallini et al. (1997)3 reported age range of 11-85 years. Stewart et al. (2000)4 and Rajwanshi et al. (2006)5 reported age range of 20-92

years and nine to 75 years respectively. In the present study the maximum patients (19 cases) were in the age range of 41-50 years. Ahmed et al. (2002)1 also observed maximum patients in the age range of 31-40 years. In the present study mean age for benign tumors was 40.36 years and mean age for malignant tumors was 40.76 years. This finding was in accordance with those published in studies of Ahmed et al.,1 Agarwal et al.,6 Potdar et al.7 & Thomas et al.[8]

Sex Distribution :- The male to female ratio of present study was found to be 0.8:1. Thus the slight female predominance in the present study was in accordance with the study of Frable and Frable (1991),2 Stewart et al (2000)4 and Rajwanshi et al. (2006).5 Cajulis et al. (1997)9 and Cristallini et al. (1997)3 observed male preponderance in their study.

Site Distribution:- In the present study parotid gland was the most commonly affected site (41 cases) followed by submandibular gland (14 cases) and minor salivary glands (1 case). submental gland was affected in three case. These findings were in accordance with the studies of Frable and Frable (1991),2 Cristallini et al. (1997)3 and Bocatto et al. (1998).10 In the study by Rajwanshi et al. (2006),5 minor salivary gland involvement was more frequent than submandibular gland involvement.

Distribution of benign & malignant tumors:- In the present study 44cases were diagnosed as benign tumors and 11 masses were diagnosed as malignant tumors on cytology. This finding was in accordance with studies of Frable and Frable,2 Stewart et al.4 and Elagoz et al.[11]

Classification of salivary gland lesions as per WHO classification :-

The salivary gland lesions were studied as per the classification given in second edition of the World Health Organization's Histological Classification of Salivary Gland Tumors. This Classification is more extensive and detailed than the previous edition published 20 years ago. The new edition is based on data regarding newly described tumor entities and the behavior and prognosis of the previously classified tumors. Among the carcinomas, various types were distinguished for purposes of recognition, prognosis, and treatment. The term tumor was replaced by carcinoma in the following two entities: acinic cell carcinoma and mucoepidermoid carcinoma. The tumor-like lesions were described in more detail (Gerhard S, Leslie HS 1992).[12]

Associated pathology along with salivary gland tumors :-

In the present study, four cases of pleomorphic adenoma were found to be associated with acute sialadenitis and one cases of mucoepidermoid carcinoma were associated with chronic sialadenitis. Azzopardi J, Evans D (1971)13 in their study found a case of malignant lymphoma of parotid gland associated with Mikulicz disease (benign lymphoepithelial lesion). Hyman G, Wolff M (1976)14 in their study of malignant lymphomas of salivary glands found four cases associated with the lymphoepithelial lesion.

Comparison of cytology diagnosis with histopathology

As observed in Table 2, one case of Warthin's tumor was diagnosed as mucocele on cytology. It was a sampling error. Similar error has been reported by Klijanienko J and Vielh P (1997)15 where in a study of 71 cases of warthins tumour five showed only cyst material on cytology. On histopathology, the tissue section showed epithelial cells with oncocytic features surrounded by lymphoid stroma one cases of mucoepidermoid carcinoma were misdiagnosed as pleomorphic ex carcinoma , on cytology. On FNAC, it showed poorly cohesive clusters of cells with chondromyxoid stroma with focal cellular atypia, not enough to warrant malignancy. The presence of few atypical cells is compatible with pleomorphic adenoma and as a general rule a few atypical cells in classic pleomorphic adenoma should not be regarded as evidence of malignancy (Cajulis et al., 1997).9 While on histopathology of the same case, tissue section showed sheets of squamous and intermediate cells with areas of mucin .

The ability of FNAC was evaluated to discriminate between non-neoplastic and neoplastic masses. Sensitivtity, specificity and diagnostic accuracy of FNAC for neoplasms were found to be 96.87%, 100% and 96% respectively

TABLE 4:- CAMPARISON WITH OTHER STUDIES

Authors	Specificity	Sensitivity	Diagnostic accuracy
Frable and Frable2	93.3	99	96.4
Bacatto et al 11	98	98	97
Das et al 17	94.6	75	91
Stow N et al18	86	96	92.5
Akter et al16	90	100	-
Present study	96.87	100	96

CONCLUSION :- To conclude, FNAC in salivary gland masses is fairly reliable for correct preoperative diagnosis. It is safe, minimally invasive, inexpensive and office procedure and provides diagnosis within hours. Overall it has shown high sensitivity, specificity and diagnostic accuracy. Inherent heterogeneity of salivary gland masses giving rise to varied cytomorphologic pictures and sampling errors are responsible for wrong diagnosis. However, multiple sampling and special attention to cytologic features should help to minimize errors.

REFERENCES

1. Ahmed S, Lateef M, Ahmed R. Clinicopathological study of primary salivary gland tumors in Kashmir. J-K practitioner. 2002;9:231-3.
2. Frable MA, Frable WJ. Fine needle aspiration biopsy of salivary galands. Laryngoscope. 1991;101: 245-9.
3. Cristallini EG, Ascani S, Farabi R, Liberati F, Maccio T, Peciarolo A. Fine needle aspiration biopsy of salivary gland 1985-1995. Acta Cytol. 1997;41:1421-25.
4. Stewart CJR, Mackenzie K, McGarry GW, Mowat
A. Fine needle aspiration cytology of salivary glands: A review of 341 cases. Diagn Cytopathol. 2000; 22:139-46.
5. Rajwanshi A, Gupta K, Gupta N, Shukla R, Shrinivasan R, Nijhawan R. Fine needle aspiration cytology of salivary glands: Diagnostic pitfalls- Revisited. Diagn Cytopathol. 2006;34:580-84.
6. Agarwal RV, Solanki BR, Junnarkar RV. Salivary gland tumors. Ind J Cancer. 1967;4(2):209-13.
7. Potdar GG, Dabhoiwala NF, Golwala RM. Parotid tumors. Indian J Surgery. 1969;31:341-9
8. Thomas KM, Hutt MSR, Borgstein J. Salivary gland tumors in Malawi. Cancer. 1980;46:2328- 34.
9. Cajulis RS, Gokaslan ST, Yu GH, Frias-Hidvegi D. Fine needle aspiration biopsy of salivary glands A five-year experience with emphasis on diagnostic pitfalls. Acta Cytol. 1997;41:1412-20.
10. Boccato P, Altavilla G, Bladamura S. Fine needle aspiration biopsy of salivary gland lesions- a repraisal of pitfalls and problems. Acta Cytol. 1998;42:888-98.
11. Elagoz S, Gulluoglu M, Yilmazbayhan D, Ozer H, Arslan I. The value of FNAC in salivary gland lesions. J Otorhinol laryngol. 2007:69(1):51-6.
12. Gerhard S, Leslie HS. The World Health Organization's histological classification of salivary gland tumours: a commentary on the second edition. Cancer. 1992;70:379-85.
13. Azzopardi J, Evans D. Malignant lymphoma of parotid associated with Mikulicz disease (benign lymphoepithelial lesion). J Clin Path. 1971;24:744- 52.
14. Hyman GA, Wolff M. Malignant lymphomas of the salivary glands. Review of the literature and report of 33 new cases, including four cases associated with the lymphoepithelial lesion. Am J Clin Pathol. 1976;65(4):421-38.
15. Klijanienko J, Vielh P. Fine needle sampling of salivary gland lesions. Cytology and histology co- relation of 71 cases of Warthin's tumor. Diagn Cytopathol. 1997;16:221-5.
16. Akhter J, Lakhay M, Hirachand S. Role of FNAC in the diagnosis of salivary gland swellings. Kathmandu Univ Med J. 2008:6(2):204-8.
17. Das DK, Petkar MA, Al-Mane NM, Mallik MK, Anim JT. Role of fine needle aspiration cytology in the diagnosis of swellings in the salivary gland regions: A study of 712 cases. Med Princ Pract. 2004;3:95-106.
18. Stow N. Fine needle aspiration cytology in the management of salivary gland tumors: an Australian experience. Ear, Nose and Throat Journal. 2004; 83(2):128-31.