VOLUME-7, ISSUE-1, JANUARY-2018 • PRINT ISSN No 2277 - 8160

Original Research Paper

ENT

A RARE CASE OF CYSTIC HYGROMA PRESENTING IN AN ADULT

Dr. Ragesh V G	3rd Year Resident, Department of ENT, NHL Medical College, Ahmedabad
Dr. Saurabh Gandhi*	Assistant Prof., Department of ENT, NHL Medical College, Ahmedabad *Corresponding Author
Dr. Madhavi S Raibagkar	HOD & Prof., Department of ENT, NHL Medical College, Ahmedabad
Dr. Shweta Mittal	2nd Year Resident, Department of ENT, NHL Medical College, Ahmedabad
Dr. Divya Prajapati	1st Year Resident, Department of ENT, NHL Medical College, Ahmedabad

ABSTRACT

Cystic hygroma is a benign congenital malformation of the lymphatic system.
Commonly seen in pediatric age group, very rare in adulthood.
18 years old male patient presented with left sided neck swelling since last 8 months. CT scan showed 8x6x3 mm sized cystic lesion in anterior triangle of neck.
FNAC suggestive of lymphatic malformation. Complete surgical excision was done. HPE confirmed the diagnosis of cystic hygroma. Patient was kept on regular follow-up , no recurrence till post-op 8 months.

KEYWORDS :

INTRODUCTION

Cystic hygroma (CH) is soft tissue water containing tumor which is an aberrant proliferation of lymphatic vessels resulting from abnormal development of the lymphatic system. Also known as "**hygroma cysticum"** or **"cystic lymphangioma"** or "**lymphatic malformation"**. Well recognized in pediatric group, it rarely presents in adulthood. Incidence is very rare in adults and less than 150 cases have been reported in the literature. In head and neck, cervical area is the predominant site of occurance due to the extensive lymphatic system. Here we report a rare case of cystic hygroma in an adult.

CASE REPORT

18 years old male patient presented to our setup with chief complaint of left sided neck swelling since last 8 months which was insidious in onset, painless, progressive. On examination a 7x5 cm^2 single large swelling in the left side anterior triangle of neck. It was non-tender, non-warm, cystic, not fixed with underlying structure. No other associated lymphadenopathy was found.

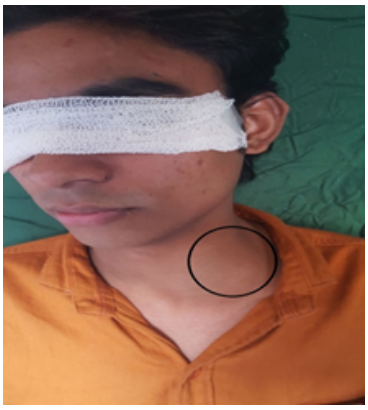

USG showed 56 X 33 mm sized well defined multiloculated (septated) cystic lesion, with internal septae, avascular in anterior triangle of neck FNAC suggestive of lymphatic malformation. CT scan of neck revealed 8x6x3 cm sized well defined fluid density lesion with enhancing septa in supraclavicular region below sternocleidomastoid muscle. It extended from C5 to T2 vertebral level. It displaced the left internal jugular vein anteriomedially and the sternocleidomastoid muscle anteriorly and common carotid artery posteriorly.

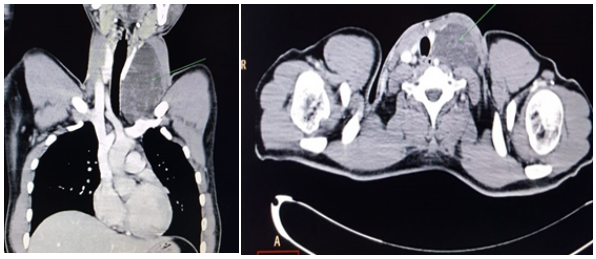

Complete surgical excision was done under general anesthesia; histopathological specimen was sent. HPE confirmed the diagnosis of cystic hygroma.

He was kept in regular follow up and there was no recurrence till post-op 8 months.

DISCUSSION

Cystic hygroma is a benign congenital malformation of the lymphatic system. It is subtype of lymphangioma which generally presents as either as congenital anomaly or within 2 years of birth (90%) and adult presentation is very rare. First reported in 1828 by Redenbacher and the name "Cystic Hygroma" was given in 1834 by Werner. Most common site is head and neck (75–90%) and in this posterior triangle of the neck (75%) is common. Other sites are axillary (20%), thoracic wall (10%),mediastinum (5%),pharynx, retroperitoneal space and pelvis. CH's arises due to or a combination of failure of lymphatic to connect to the venous system, abnormal budding of lymphatic tissue and sequestered lymphatic rests that retain their embryonic growth potential.

There are three histological subtypes of cystic hygroma- capillary lymphangioma, cavernous lymphangioma, cystic lymphangioma. Radiological investigation are essentially used for diagnosing the extent of the disease. Intrathoracic extension, which may be present in 10% of cases.

Microscopically, lymphangioma is characterized by large, dilated lymphatic vessels in a fibrotic or loose stromal background. Focal areas of papillary endothelial proliferation is seen. The main

histopathologic differential diagnosis of cystic hygroma is cavernous hemangioma in which blood filled large cystic spaces were described to be similar to lymphangioma. The lining endothelium of cavernous hemangioma shows positivity with pancytokeratin and Factor VIII, immunohistochemically. The presence of lymphatic spaces with thin walls containing fibrous tissue, smooth muscle, and lymphoid aggregates favors the diagnosis of lymphangioma . In general, lymphangioma is accepted as a benign tumor with no malignant transformation and curable by excision.

Surgical excision is mainstay of treatment . Complete excision has 81% cure rate and only when a part of lymphatic malformation is excised in case of extensive lesions it has got 88% recurrence rate .Other modalities includes intra-cystic injection of sclerosing agent.

CONCLUSION

Cystic hygroma is commonly known disease in pediatrics but is very rare in adults and is a *diagnostic challenge*.Based on clinical, radiological and cytological findings, probable diagnosis of cystic hygroma is made which can be confirmed histopathologically. Complete surgical excision is treatment of choice and has better prognosis. Giant cystic hygroma with extension into thorax is a *surgical challenge* but comprehensive knowledge of anatomy with meticulous surgical dissection is key for successful complete excision.

REFERENCE

1. Scott Brown 7th edition /volume 3/part 14 (chapter- 140/ Pages 1782-1783)
2. Report in Grand Rounds journal(Vol 11) pages 5–11 (Specialities: General Surgery Article
3. Type: Case Report DOI: 10.1102/1470-5206.2011.0002 2011) http://www.grandroundsjournal.com/articles/gr110002/gr110002.pdf
4. Cystic hygroma of neck in adult: case report and literature review http://ispub.com/IJS/22/2/12186
5. Case report available from http://advancejournals.org/bmr-medicine/article/a-giant-cystic-hygroma-in-adult-a-surgical- challenge/
6. Adult-onset cystic hygroma: A case report of rare entity https://www.ncbi.nlm.nih.gov/pmc/articles/PMC4836099/
7. Cystic hygroma in adult, a case report https://www.ncbi.nlm.nih.gov/pmc/articles/PMC3066745/
8. Cervical Cystic Hygroma in an Adult Case Reports in Pathology Volume 2014 (2014), Article ID 209427 https://www.hindawi.com/journals/cripa/2014/209427/