VOLUME-7, ISSUE-10, OCTOBER-2018 • PRINT ISSN No 2277 - 8160

Original Research Paper

Medial Science

A CASE REPORT ON HAEMATOCOLPOS

Archana Suneja

Kiran Borkar

ABSTRACT

Background: Abdominal masses in female adolescents are uncommon. A rare cause of this condition is hematocolpos due to imperforate hymen. Ideally, diagnosis should be made early during fetal and neonatal examinations to prevent symptomatic presentations of its complications at puberty.

Case report: We report a case of a 14-year-old girl who presented with delayed menarche, eight months history of cyclic abdominal pain, and a two days history of retention of urine. The development of her secondary sexual characteristics was normal for her age. A bulging bluish imperforate hymen was found on examination. Her transabdominal ultrasound revealed about 15x 6.6 cm mass in continuation of uterus in region of vagina with debris within. She had virginity-preserving hymenotomy and evacuation of about 300 ml of accumulated coffee-colored menstrual blood.

Conclusion: Clinicians should have high index of suspicion of imperforate hymen when assessing cases of delayed menarche with cyclic lower abdominal pain to prevent the consequences of its delayed treatment like massive hematometra, hematocolpos and urinary retention.

KEYWORDS :

BACKGROUND

Hymen development origin is variable and complex. Imperforate hymen is rarely a part of systemic/genetic anomaly. Genital examination at birth or during puberty is mandatory which often guides the timing of hymenectomy and prevents the sequelae of imperforate hymen. Hymenectomy is ideal during puberty and resolves all genitourinary obstructions.

An imperforate hymen is a condition in which the hymen covers the entire opening of the vagina, sealing it shut. The condition is a congenital disorder, meaning that it's something a girl is born with. No one knows why it happens.

What Is the Hymen? The hymen is a thin membrane that usually covers part of the opening of the vagina. It typically has an opening that widens as a girl approaches puberty.

Hymens may have different shapes, with the most common shape being a half moon. The presence of a hymen doesn't indicate "virginity." In fact, some girls are born without a hymen. The hymen can stretch or tear during sexual intercourse, tampon insertion, sporting activities, or medical procedures.

Imperforate hymen is relatively rare but it is the most frequently encountered obstructive anomaly of the female lower genital tract. The clinicalpresentation vary significantly from patient to patient depending on the age at diagnosis but in most cases the diagnosis is missed in early childhood and therefore the diagnosis is made after puberty when the patient present with haematocolpos, heamatometra or both. When this happens, the presentation could even be tricky because the patient may presents with unlikely symptoms apart from cryptomenorhoea like, urinary retention or bowel obstruction or both.(1)

Imperforate Hymen Symptoms

In a pubescent girl, lack of a first menstrual period may be a sign of an imperforate hymen. An imperforate hymen typically doesn't cause any problems until a girl gets her period. At this point, the hymen membrane can block menstrual blood from flowing out of the vagina. This blockage may cause: A painful mass or a feeling of fullness in the lower abdomen or pelvis (from the buildup of menstrual blood in the vagina),Stomach pain, Back pain, Difficulty urinating, Painful bowel movements(2)

An emerging abdominal tumor in young females is a rare situation and requires a specific clinical and ultrasonographic approach. Common causes of a newly diagnosed abdominal mass in young females include cysts and solid tumors of various origins. In this context, hematocolpos is a rare entity that can cause such symptoms: it comprises the blood collection in the distal closed vagina and is usually diagnosed in young adolescents with no menstruation and cyclic abdominal pain. Its incidence is approximately one every 2000 young adolescentsand in 90% of cases is caused by an imperforate hymen.(3)

Usual clinical signs include cyclical low abdominal pain, urinary retention, back pain, primary amenorrhea, and/or a quickly enlarging pelvic tumor. It may also affect neonatal age and can be manifested as fetal ascites or renal failure sometimes leading to variable degrees of hydroureter and/or hydronephrosis. For its diagnosis, 2D sonography is the usually indicated imaging method of choice. 3D sonography and MRI are rarely suggested and used, although they both provide a better visualization and differentiation of the tissues and a safer distinction among other causes of hematocolpos, such as vaginal septum or partial agenesis. In addition, an endocrine profile of the patient is usually necessary. Surgery to remove an imperforate hymen can be performed in infants, but some parents opt to wait until closer to puberty. Girls recover from the surgery within a few days.(4)

Surgical management is the treatment of choice, through incision or excision of the hymen, using cold knife, scissors, electrocoagulation, or laser. The recurrence rate remains low, occurring more often during minor surgical approaches, such as after a cruciate incision. Notably, a spontaneous rupture of an imperforate hymen is likely to precede any decision for surgical management. Finally, further issues have to be weighted, such as the bleeding and the subsequent emotional stress of the young female after the procedure, along with the completion and keeping of legal documentation.(3)Case Report

Miss UG is a 15-year-old girl who was referred to the gynaecologic clinic of Enugu State University Teaching Hospital on account of eight month history of cyclic abdominal pain, delayed menarche, and a three week history of lower abdominal swelling. She admitted to occasional episodes of constipation and urinary retention. Her secondary sexual characteristics were normal for the age (Tanner stage III). A 20 cm sized suprapubic, tender, cystic, and dull to percussion mass was found on abdominal examination. Perineal examination revealed a bulging pinkish imperforate hymen. Transabdominal ultrasound revealed a grossly dilated uterine cavity, and vagina that were containing 811.8 cm3 of fluid with low

level echoes. The urinary bladder was compressed by the fluid. The kidneys, ureters, uterus and ovaries were normal. The full blood count, serum urea, electrolyte and creatinine were also normal. The patient and her mother were counseled on the surgical treatment options and the possibility of loss of virginity during the surgery. They gave consent to the surgery that may preserve virginity. She had hymenotomy under spinal anesthesia on 28/10/2017. Over 1000 mls of coffee-colored menstrual blood was evacuated. The urethra was catheterized to avoid its iatrogenic damage before about 1.5 cm cruciate incisions were made on the central portion of the membrane. Minimal trimming of the edges of the hymen was done to prevent defloration. The urethral catheter was removed after the procedure in the theater. Intravenous ceftriaxone 1 g 12hourly were administered for the first 24 hours, and tablets ceftriaxone 200 mg twice daily were continued for the next seven days. Her postoperative recovery was uneventful. She was discharged on the third postoperative day, and was to be seen in the gynecological clinic in six weeks.

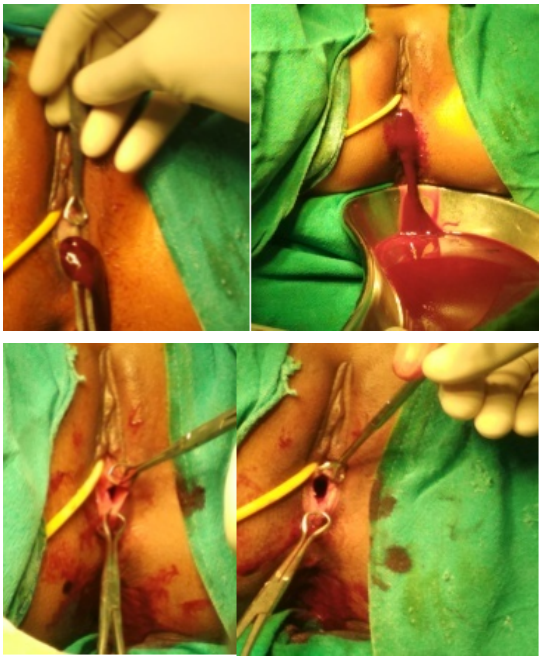

DISCUSSION

Gross hymenal abnormality of significance is imperforate hymen. It is due to failure of disintegration of the central cells of the Müllerian eminence that projects into the urogenital sinus.The existence is almost always unnoticed.

Until the girl attains the age of 14–16 years. As the uterus is functioning normally, the menstrual blood is pent up inside the vagina behind the hymen (cryptomenorrhea). Depending upon the amount of blood so accumulated, it first distends the vagina (hematocolpos). The uterus is next involved and the cavity is dilated (hematometra). In the late and neglected cases, the tubes may also be distended after the fimbrial ends are closed by adhesions (Hematosalpinx) Abdominal examination reveals a suprapubic swelling, which may be uterine or full bladder. Prior catheterization reveals the true state. Vulval inspection reveals a tense bulging membrane of bluish coloration (Fig. 4.3). In majority, however, it is not the true hymen but the obstructing membrane is a transverse vaginal septum close to the inner aspect of the hymen. Rectal examination reveals the bulged vagina. Ultrasonography can make the diagnosis of hematometra and hematocolpos. In newborn (usually within one week of birth), accumulated mucus behind the imperforate membrane gives the clinical entity of mucocolpos. The secretion is either from the desquamated vaginal epithelial cells or from the cervical glands(4).

Early diagnosis and timed surgical treatment of an imperforate hymen are important to prevent the complications associated with the delayed treatment after puberty. The diagnosis is usually delayed till after puberty when it presents with its complications like delayed menarche, cyclic lower abdominal pain and mass, and bulging vaginal membrane as in miss UG. Constipation, urinary retention and infection, pelvic infection and tubo- ovarian abscess, hematosalpix, and endometrosis are the other reported symptomatic presentations of imperforate hymens when treatments were delayed. Our patient also had occasional constipation and retention of urine. A defect on the hymenal barrier can encourage ascending pelvic infection in the accumulated menstrual blood as pelvic inflammatory disease, and pelvic abscess, and this informed the empirical use of antibiotics in our patient . The diagnosis of imperforate hymen in miss UG was delayed till after menarche when over 300 ml of menstrual blood was accumulated. Early diagnosis of imperforate0 hymen in the fetus, newborn or in childhood and timed hymenotomy at menarche would have prevented the complications. The timing of surgery is controversial. Some authorities believe that hymenotomy is simple and can be done even in newborns. Virginity is cherished by many religions, cultures and families. Our patient and her mother were counseled about this issue of defloration during surgery. They opted for a virginity-preserving hymenotomy. Minimal edges of the hymen were excised in our patient as were done by other authors. Foleys catheter in the young girls made the procedure unpopular. Other consequences or clinical implications that timed hymenotony with good surgical techniques can prevent include recurrence or closure of the opening, scarring of the edges of the hymen and dysparenuia, ascending pelvic infection and infertility, chronic pelvic pain, and ectopic gestation. Most girls who want to conceive after surgery usually achieve pregnancy .(1)

CONCLUSION

Imperforate hymen is a rare congenital malformation that closes the vagina outflow tract causing accumulation of mucus, fluid and menstrual blood. High index of suspicion is required for early diagnosis and treatment before the complications like massive hematometra and hematocolpos occur. Virginity- preserving hymenotomy should be the treatment of choice as virginity is cherished by many religions, cultures and families.(5)

REFERENCES

1. Ii O, Bu O, Ia U, Ds O, Pk E, Ij O. Imperforate Hymen Presenting with Massive Hematometra and Hematocolpos: A Case Report. Gynecol Obstet [Internet]. 2015 Oct 15 [cited 2017 Nov 26];5(10). Available from: https://www.omicsonline.org/open-access/imperforate- hymen-presenting-with-massive-hematometra-andhematocolpos-a-case-report -2161-0932-1000328.php?aid=62332
2. Lindsey KonkelMedically. INTRO TO IMPERFORATE HYMEN.
3. Makris GM, Macchiella D, Vaidakis D, Chrelias C, Battista MJ, Siristatidis C. Abdominal Tumor in a 14-Year-Old Adolescent: Imperforate Hymen, Resulting in Hematocolpos—A Case Report and Review of the Literature [Internet]. Case Reports in Obstetrics and Gynecology. 2015 [cited 2017 Nov 26]. Available from: https://www.hindawi.com/journ als/criog/2015/429740/
4. Debra Rose Wilson. DIAGNOSIS OF IMPERFORATE HYMEN.
5. Ii O, Bu O, Ia U, Ds O, Pk E, Ij O. Imperforate Hymen Presenting with Massive Hematometra and Hematocolpos: A Case Report. Gynecol Obstet [Internet]. 2015

Oct 15 [cited 2017 Nov 26];5(10). Available from: https://www.omicsonline.org/ open-access/imperforate- hymen-presenting-with-massive -hematometra-andhematocolpos-a-case-report-2161-0932- 1000328.php?aid=62332