VOLUME-7, ISSUE-10, OCTOBER-2018 • PRINT ISSN No 2277 - 8160

Original Research Paper

Radiology

ROLE OF MAGNETIC RESONANANCE IMAGING IN TUBERCULOUS SPONDYLITIS AND NEUROLOGICAL STATUS

Vinita Malhotra

Chandan Kumar* *Corresponding Author

Raj Laxmi

A. K. Gupta

Ashok Kumar Verma

ABSTRACT

INTRODUCTION: Tubercular spondylitis is defined as an infection by Mycobacterium tuberculosis of one or more of the extradural components of the spine namely the vertebra, intervertebral disks, paraspinal soft tissues and epidural space. It is associated with disproportionate amount of morbidity due to its tendency to produce significant deformity and neurologic complications. Therefore, Prompt diagnosis and treatment are of utmost importance. MRI has proven best technique for early diagnosis tubercular spondylitis and neurological complications.

AIMS AND OBJECTIVES: MRI is a non-invasive diagnostic tool for evaluation and early diagnosis of tubercular spondylitis. To obtain the correlation between MR imaging findings and the neurological status of the patient.

MATERIAL AND METHODS: 55 Patients with strong clinical suspicion of tubercular spondylitis with and without neurological deficit are included. Proper history, clinical examination and neurological examination of affected cord followed by MRI study was done on 1.5 tesla scanner.

RESULTS AND CONCLUSION: Early visualization of change in bone marrow intensity, erosion of end plate, destruction/ collapse of vertebral body, loss of disc space and change in intensity of intervertebral disc space, pre and paravertebral soft tissue abscess/collection, calcification/ bony fragments in pre and paravertebral spaces, bilateral psoas abscess are well seen on MRI sequences. Epidural abscess, thecal sac compression, CSF compression, cord edema, cord compression of spinal cord are also well seen on MRI. There is significant correlation between the clinical as per the ASIA class and the MRI findings in relation to the spinal canal .IN MRI proper coil and proper sequences were used.

KEYWORDS : Magnetic Resonance Imaging, Spinal Tuberculosis, Neurological Complications.

INTRODUCTION

Tubercular spondylitis is defined as an infection by Mycobacterium tuberculosis of one or more of the extradural components of the spine namely the vertebra, intervertebral disks, paraspinal soft tissues and epidural space. It is associated with disproportionate amount of morbidity due to its tendency to produce significant deformity and neurologic complications. Therefore, Prompt diagnosis and treatment are of utmost importance. MRI has proven best technique for early diagnosis tubercular spondylitis and neurological complications. Tubercular spondylitis is a serious clinical problem because concomitant neurological deficit frequently occurs. An early diagnosis and prompt treatment is of utmost importance. Conventional X-rays are useful in diagnosis of spinal tuberculosis but main disadvantage is that more than 50% of bone has to be destroyed before lesion can be seen on a plain radiograph.

CT Scan can evaluate extent of disease, patterns of bone destruction, disc space narrowing, para vertebral soft tissue abscesses and calcification. However, it may not detect epidural, thecal or spinal cord involvement. Four patterns of spread in vertebral body is recognized are anterior, central, paradiscal and neural arch involvement.

MRI because of the lack of ionizing radiation, high contrast resolution, ability to detect marrow infiltration, edema of cord and ease of assessment of extramural disease and status of spinal cord has become the established optimal imaging technique in the diagnosis of spinal infections and their sequel. Soft tissue and intraosseous abscess are also well seen on MRI.

AIMS AND OBJECTIVES

- To demonstrate, analyze, and evaluate magnetic resonance imaging as a valuable noninvasive diagnostic tool to promote early detection of tubercular spondylitis.
- To obtain the correlation between MR Imaging findings and the neurological status of the patient.

MATERIAL AND METHODS

The present study was conducted in department of radiodiagnosis in collaboration with department of orthopedic surgery between October 2017 and May2018. The cases either admitted or seen in OPD in department of orthopedic Surgery, enrolled in the study after taking the informed consent.

Each patient underwent complete clinical and neurological examination and was classified according to the ASIA impairment scale.

In the ASIA scale, severity of neural deficit as reflected by score depends upon the level of involvement in addition to the severity of cord compression at the involved level. Higher the level of affection of the spinal cord, lower the score.

MRI was performed on a 1.5T scanner
(Siemens, Germany)

MAIN Sequences used are

1. Sagittal and axial TIW FSE spine echo (FSE) with low TR/TE. These are characterized by short TR of 400 to 500 m sec and short TE of 12-20 msec. Fov was 300 to 340 mm.
2. Sagittal and axial T2W fast spin echo (FSE) with long TR/TE. TR of 4300-4500 m sec and TE of 128 m sec were employed.
3. Fat suppressed coronal T2 images (STIR-short tau inversion recovery) TR 5800 TE 70 For sagittal images, the entire spine was covered in about 12 slices. Slice thickness for all planes was 4 mm with distance factor of 10.

OBSERVATION

A total of 55 patients with strong suspicion of tuberculous spondylitis were clinically examined and MRI was done.

Mean age distribution was 42 years ranging from 15-80 years. Most of the patients were in the ages 20-40. Out of total of 55 patients, 28 (50.91%) were male and 27(49.01%) were female. Predominant symptoms were fever only, fever and neurological deficit. Duration of Symptoms in patients at the time of presentation was 1-5 months. Chest Radiograph of presented patients was normal in 33 (60%), abnormal 22(40%).

Table 1: Distribution of Patients according to final ASIA Class based on sensory and motor grading.

ASIA CLASS	NUMBER OF PATIENT	PERCENTAGE
A	2	3.64
B	1	1.82
C	10	18.18
D	29	52.72
Not applicable (No Neurological deficit at presentation)	13	23.64
Total	55	100

More than half of the affected vertebrae (61.82%) were in the thoracic region followed by (27.27%) in the lumbar Region. CVJ and cervical were in3.64%, and5.45% respectively. (1.82 %) were in Lumbo sacral region.

6 patients were excluded from evaluation of spinal cord parameters as the vertebral level of involvement was below L1.

Table 2: Osseous features confirming to tuberculous spondylitis as seen on MRI

Feature	Number of Patients	Percentage
End Plate involvement	51	92.73 %
Vertebral body	49	89.09
Posterior elements	16	29.09
Inter vertebral disc/diskitis	52	94.55
Pre-Vertebral granulation tissue/abscess	53	96.4
Para vertebral granulation tissue/abscess	52	94.5
Epidural abscess/granulation tissue	49	89.09

92.73 % out of 55 patients had end plate and disc involvement, 29.09% patients had posterior elements involved, Vertebral collapse was noted in 24(43.6%) patients. Pre and paravertebral soft tissue involvement was seen in 96. 4% and 94.5% of granulation tissue /abscess.

Most of the lesions were hypointense in 26 patients (47.27%) or isointense in29 patients (52.7%) on T1 Weighted images and hyperintense in 31 patients (53.97%) or mixed intensity in 24 patients (46.03 %) on T2 weighted images. No lesion was hypointense or isointense on T2 images.

Table 3: Frequency table showing features in relation to spinal cord as seen on MRI

Feature	Before treatment (%)	After 6 months of of treatment (%)
Thecal compression	45/55 (81.82)	11/55 (20)
Loss of CSF Thickness	42/55 (76.32)	9/55 (16.36)
Cord edema	35/49 (71.43)	1/49 (2.04)
Cord Compression	31/49 (63.3)	4/49 (8.16)

Table 4: Composite table showing the number of patients in ASIA class A to D against most important MRI features in relation to spinal canal.

MRI Feature	Before treatment					After 6 months of treatment				
	ASIA A (n=2)	ASIA B (n=1)	ASIA C (n=10)	ASIA D (n=29)	ASIA E (n=13)	ASIA A	ASIA B	ASIA C	ASIA D	ASIA E
Epidural abscess	2	1	10	29	8	2	1	6	9	5
Thecal Sac										
Normal	0	0	0	1	9	2	0	5	24	13
Compressed	2	1	10	28	4	0	1	5	5	0
CSF Thickness										
Normal	0	0	0	2	11	2	1	6	24	4
compressed	2	1	10	27	2	0	0	4	5	0
Cord										
Normal	0	0	1	4	13	1	0	6	23	13
Compressed	2	1	7	21	0	1	1	2	2	0
Cord edema										
Absent	0	0	2	2	11	2	1	7	25	13
Present	2	1	6	23	2	0	0	1	0	0

Active disease would require active treatment of spinal tuberculosis with or without surgical decompression.

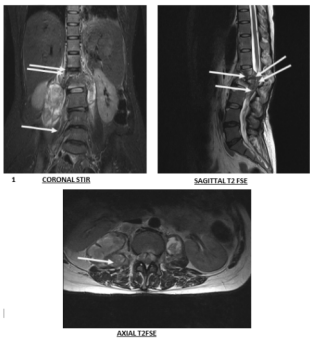

female 37 yrs old, presented with fever lower limb weakness. partial collapse of l1&l2 vertebrae with angular kyphosis. there is loss of intervening disc space between l1 -2. soft tissue collections in pre and para vertebral region. an epidural abscess (8.66 mm) causing posterior displacement and compression of the spinal cord.

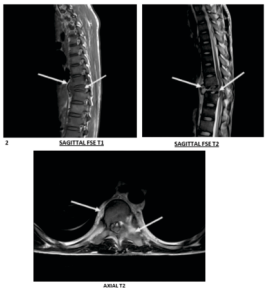

Male 18 yrs old, presented with lower limb weakness, fever T9-T11 vertebrae are involved along with posterior element involvement. There is partial collapse of T10 leading to angular kyphosis. Ventral epidural abscess of (5.35mm) causing posterior displacement and compression of cord.
1.28 cm subligamentous prevertebral abscess are present. Para vertebral collection(1.6cm) are seen.
Hyperintense intervening disc spaces are seen.

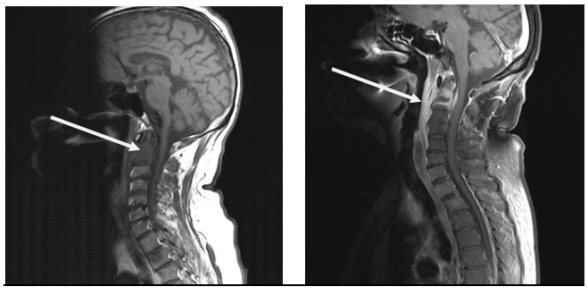

3 (T1 SAGITTAL) (STIR SAGITTAL)

69 YRS old male patient present with fever and neck pain. No neurological deficit is seen.

Altered signal intensity of C1 and C2 vertebral bodies Hypointense on T1, hyperintense in T2 and STIR. Prevertebral and paravertebral soft tissue collection is seen. There is loss of intervertebral disc space.

DISCUSSION

55 patients were included in our study, out of which 42 were neurological patients and 13 were non-neurological patients. More than half of the vertebrae (61.82%) were in the thoracic region followed by (27.27%) in the lumbar region.

In MRI first and foremost thing that is visualized is change in marrow signal of vertebrae. On TI W, shows hypointense (47.27 %) to isointense (52.73%) signal intensity. On T2 weighted hyper intense (56.36 %) or mixed intensity (43.64%) signal. No signal was hypo intense or isointense on T2.

Erosion of superior and inferior surface of the end plates was seen. Almost 92.06% of patients presented with end plate involvement.

Partial collapse of vertebra is seen in24 (43.76%) patients. On T2 there is absence of normally visible internuclear cleft due to underlying inflammation.

Posterior elements are involved in16 (29.09 %) in contrast to pyogenic osteomyelitis.

Inter-vertebral diskitis (94.55%) is seen as irregularity of normally sharp disc-end plate interface on T1 W. On T2 shows abnormally hyperintense signal intensity.

Jain et al stated that preservation of disc despite extensive bone destruction is virtually pathognomic for Spinal tuberculosis.

Pre-vertebral and para vertebral granulation tissue is visible as hypo to intermediate signal intensity on TIW images, hyperintensity on T2W images and homogenous enhancement on post gadolinium images. Similarly intraosseous abscess is seen as hyperintensity on T2W. On T2W images, abscesses were relatively more hyperintense than the granulation tissues.

Calcification and or bone fragment in soft tissue can be identified as small areas of signal void within the pre/paravertebral soft tissue.

Combination of osteitis, abscess with or without discitis is almost diagnostic of tubercular spine.

Maximum number of patients belonged to ASIA D involving mainly thoracic vertebrae, where the spinal canal is narrow and abscess tend to localized under anterior longitudinal ligament. A and B class shows maximum neurological deficit and cord compression.

Epidural extension of the lesion with resultant thecal compression with or without cord compression was seen in 89.09% of patients (49/55). Mean epidural thickness was 6.48 mm.

Spinal cord involvement was very clearly seen on sagittal and axial MR images .81.82 % patients had thecal compression. Out of which 63,3% had actual cord compression. Cord edema was seen as hyperintensity of cord on T2 in 71.43% patients. Thus, in decreasing order of frequency the progression of compression was thecal compression, loss of CSF thickness, cord edema and cord compression.

According to **cotton et al** neurological deficit occurs only when there is more than 60% encroachment of the spinal canal above the level of the conus. **Jain et al** reported it up to 76% canal encroachment leads to no significant deficit. Compression of cord was identified on MR by recognizing the altered, flattened configuration of the cord at the site of compression.

The High signal on T2 W images within the cord could represent either cord edema or myelomalacia. It can be differentiated on the clinical ground and duration of disease. Arachnoiditis as complication of spine tuberculosis was not seen in any of the patient. On TIW images arachnoiditis is seen as shaggy cord CSF interface. On post gadolinium images there was meningeal enhancement.

After six months of ATT treatment or surgical and ATT treatment shows majority of patients of ASIA D recovered to ASIA E with neurological complete recovery. After similar treatment in ASIA C few of them remained in ASIA C only. Some of them recovered to ASIA D and majority of them recovered to ASIA E.

There was significant reduction in cord edema after six months therapy (71.43% to 2.04 %). There was either decrease in size or complete resolution of extra osseous soft tissue epidural abscess (1.74 mm ± 1.3 mm) Cord compression was reduced to 8.16 % from initial 63.3 %. The involved vertebrae which were hypointense on TIW images, became hyperintense on T1W images after treatment suggesting fat replacement.

MRI is not only the modality of choice in diagnosis of Tuberculous spondylitis, but also for follow up study as there is a definite correlation between MR findings and neurological status.

CONCLUSION

Change in signal intensity with or/and without abscess or/and discitis is almost diagnostic of tubercular spine.

Thus, it is concluded from our study that there is significant correlation between the clinical status as per the ASIA class and the MRI findings in relation to the spinal canal. The most important structural abnormality that needs to be addressed is the thecal sac compression, the size of epidural abscess, presence or absence of retropulsed fractured vertebral fragment, size of CSF pockets, cord compression, and cord edema.

REFERENCES

1. Weaver P, Lifeso RM. The radiological diagnosis of tuberculosis of the adult spine, Skeletal Radiol 1984; 12(3): 178-186.
2. ModicMT, Feiglin DH, Piralno DW, Boumphery F. Weinstein MA Duchesneau PM et at: Vertebral Osteomyelitis: Assessment using MR Radiology. 1985;158: 157-166.
3. Lifeso RM, Weaver P. Harder, EH. Tuberculous spondylitis in adults, J Bone Joint Surg. Dec. 1985; 67-A (9): 1405-1413
4. Sharif HS, Clark DC. Aabed MY, Haddad MC. Al-Deeb SM, Yaqub B et al. Granulomatous spinal infections: MR imaging Radiology 1990: 177:101-107.
5. Boxer Dl. Pratt L. Hine AL, McNicol M: Radiological features during and following treatment of spinal tuberculosis. Br. J Radiol. 1992; 65%476-479.
6. Name-Hyun Kim, Hwan – Mo Lee, Jin-Suck Sub. Magnetic Reasonance imaging for the diagnosis of tubercular spondylitis. Spine 1994; 19 (21): 2451-2455.
7. Shanley DJ: Tuberculosis of the Spine. Imaging Features AJR AM J Roentgenol 1995; 164: 659-664.
8. Sternbach G. Percival Pott: Tuberculous spondylities. J Emerg Med 1996; 14(1): 79-83.
9. Cotton A, Flipo RM. Drouot MH, Maury F, Chastanet P: Spinal Tuberculosis: Study of clinical and radiological aspect s from a series of 82 cases. J. Radiol 1996; 77(6) :419-426.
10. Gupta R.K. Agarwal P. Rastogi H, Kumar S. PhadkeRV: Problems in distinguishing spinal tuberculosis from neoplasis on MRI Neuroradiology. 1996; 38(1): 97-104.
11. Sharma A, Goyal M, Mishra NK Gupta, Y. Gaikwad SB. MR. Imaging of tuberculous spinal arachnoiditis. AJR Am J Roentgenol1997; 168(3) 807-812.
12. Moon MS. Tuberculosis of the spine Contoversies and a new challenge Spone. 1997;

22(15):1791-1797.
13. Pertuiset E, Beaudreuil J, Liote F, et al. Spinal tuberculosis in adults. A study of 103 cases in a developed country, 1980-1994. Medicine (Baltimore), 1999; 78 (5): 309-320.
14. Turgut M. Spinal tuberculosis (Pott's disease): its clinical presentation, Surgical management, and outcome. A survey study on 694 patients. Neurosurg Rev. 2001; 24(1): 8-13.
15. Moorthy S, Prabhu NK Spectrum of MR imaging findings in spinal tuberculosis. AJR Am J Roentgenol. 2002; 179(4): 979-983.
16. Jung NY, Jee WH, Ha KY et al. Discrimination of tuberculous spondylitis from pyogenic spondylitis on MRI. AJR Am J Roentgenol 2004: 182(6) 1405-1410
17. Rajasekaran S, Prasad Shetty A, Dheenadhayalan J, et al. Morphological changes during growth in healed childhood spinal tuberculosis: a 15- year prospective study of 61 children treated with ambulatory chemotherapy. J PediatrOrthop. 2006: 26(6): 716-724.