



COMPARATIVE STUDY OF HUMAN GALL BLADDER VARIATIONS IN SOUTH INDIAN POPULATION

Mythili Krishnan

Department of Anatomy, Karuna Medical College, Vilayodi Palakkad - 678103, Kerala, India.

Kirubhanand Chandrashekar*

Department of Anatomy, All India Institute of Medical Sciences - Nagpur, Maharashtra, India. *Corresponding Author

ABSTRACT

Human gall bladder has a distinct anatomical entity with significant clinical implications. The present study was carried on cadavers during undergraduate dissection, in the Department of Anatomy, Karuna Medical College, Vilayodi Kerala India. The purpose of this study was to determine the anatomy of gall bladder and variations associated to them. The growing importance of such variations lie not only from the point of biliary disease but also with respect to the various invasive techniques in the treatment of gall bladder and extrahepatic bile duct disease. Cases of gall bladder with Phrygian cap, Hartmann's pouch and cholelithiasis are reported in the present research study.

KEYWORDS : Hartmann's pouch, diverticulum, gall bladder, Phrygian cap, cholelithiasis.

INTRODUCTION

The gallbladder is affected by many congenital anomalies, which may affect its location size and morphology. Some of these malformations are rare. It has gained interest in laparoscopic cholecystectomy. Injuries caused during laparoscopic cholecystectomy can cause significant morbidity and even mortality.

Hartmann's pouch (Diverticulum)

Hartmann's pouch (Diverticulum) is of congenital or acquired type. The congenital type has all three layers of gall bladder wall, whereas the acquired variety is a result of any disease process and has little or no smooth muscle in its wall. Diverticulum of the gall bladder may remain uneventful or present with an array of clinical signs and symptoms. It is often associated with cholelithiasis and carcinoma of gall bladder (Rajguru et al., 2012).

Cholelithiasis

Impaction of gall stones within the gall bladder results in formation of mucocele. Absorbed bile is replaced by mucous secreted by gall bladder epithelium. Gall stones within Hartmann's pouch causes obstruction of common hepatic duct by extrinsic compression known as Mirizzi sign. Its clinical manifestation is intermittent or persistent jaundice (Cherukuri et al., 1998). The presence of Hartmann's pouch is not being identified preoperatively. Identification of presence of Hartmann's pouch and cholelithiasis is important during surgery to prevent intra operative and post-operative complications.

Phrygian cap deformity

Phrygian cap deformity of fundus of gall bladder was found in one specimen. A septum which divides the gallbladder into two cavities joined by a canal has been described as a stricture (Beilby, 1967), a septate gallbladder (Mohan, 1965), and an 'hourglass' gallbladder (Harlaftis et al., 1977). This is in contrast to multiple septae where only 13 cases (Jena et al., 1977; Toombs et al., 1982). A differentiation can be drawn between congenital and acquired forms of septum by the presence of adenomyomatosis in the acquired group (Jutras et al., 1960). However, not all agree (Aguirre et al., 1969). Adenomyomatosis may be of a segmental nature, which give rise to an 'hourglass' deformity of the gallbladder.

The phrygian cap, a triangular deformity of the gallbladder fundus as seen on X-ray and ultrasound, is a fairly common anatomical variant. It probably has a similar aetiology to a congenital septum, although it does not give rise to symptoms. When the fundus of the gallbladder is folding over the body of the gallbladder, the "Phrygian cap" variation is created. In many cases with "Phrygian cap" deformity, there is a mucosal fold created, which partially

subdivides the lumen of the organ.

MATERIALS AND METHOD

Study was carried out to determine the external morphology of the gall bladder obtained from 50 specimens collected from 10% formalin fixed human cadavers during routine undergraduate dissection in the Department of Anatomy, over a period of 8 years by routine procedure of standard dissection of cadavers. 10% formalin fixed cadavers were studied in detail about their position, shapes and dimensions.

The cadavers were embalmed with routine embalming solutions for anatomical dissection. Skin over rectus sheath and linea alba was incised and vertically along the middle of the rectus muscle the abdominal cavity was opened. Peritoneal cavity was exposed. Liver was pulled superiorly and tilted its inferior margin to expose the lesser omentum. Anterior layer of the peritoneum was removed from the omentum.

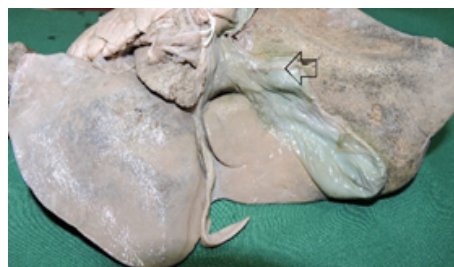The anatomy of all the gall bladders was macroscopically studied for identification of Hartmann's pouches. Further lumen of gall bladder was dissected to check the gall stones within the lumen of body, neck and Hartmann's pouch.

OBSERVATION:

Hartmann's pouch

The Hartmann's pouch was formed in the luminal surface of the gall bladder as a solitary diverticulum incidence of this sort is reported to be 9% as reported in literature. This important anatomical as well as clinical entity should be differentiated from other types of congenital anomalies and pathological states of gall bladder.

Figure 1: Specimen indicating Hartmann's pouch

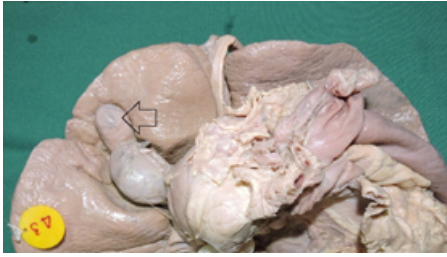


The diverticula found in the present study were congenital, i.e., true diverticula, as they were solitary, external outpouching of the gall bladder wall, without calculi and without any breach of mucosa. No internal saccular lesions were observed in the interior of the gall bladder. No pathology was detected in these specimens.

Phrygian cap

A Phrygian cap is a common variant and does not give rise to symptoms. In order to cause symptoms, the connection between the two gallbladder cavities must be very narrow, obstructing the flow of bile between them.

Figure 2 : Specimen indicating Phrygian Cap



In the case of Phrygian cap, the folding of the fundus was oriented upwards. Solitary or multiple septa can be found inside the gallbladder. These septa may cause stasis of the bile and formation of stones.

DISCUSSION

Hartmann's pouch

Hartmann's pouch is a sacculation found in the neck of gall bladder i.e frequent but inconstant feature of human gallbladders. There is a significant association between the presence of Hartmann's pouch and stones ($p < 0.05$). Adhesions between the cystic duct and the neck of the gallbladder are responsible for Hartmann's pouch. Hartmann's gallbladder pouch is a morphologic rather than an anatomic entity (Charyshkin, AL 2013). True diverticula may or may not be involved in the pathology within the gall bladder.

Hartmann's pouch of gall bladder was found in a total of nine (9%) cadavers out of one hundred. Congenital diverticula (true) includes all three histological layers of the gallbladder. A Pseudo diverticula have an acquired cause and may develop multiple fundal lesions, internal saccular lesions without external hernia like protrusions and little or no smooth muscle may be present in gall bladder wall. (Jaba Rajguru, Shilpi Jain, Satyam Khare, Ratna R Fulzele, 2013).

Congenital diverticula contract following a fatty meal in absence of secondary inflammatory pathology, whereas the acquired diverticulum is visualized and does not contract normally as inhibition by mechanical traction factors or since there is no muscularis mucosae present to respond to normal stimulus and exhibit as hernia like protrusions of gall bladder mucosa through intramural diverticulosis (K.Lakshmi Kumari and Vijaya Babu, 2014).

PHRYGIAN CAP

Incidence of phrygian cap is 4% and is normally asymptomatic but can be misinterpreted as liver lesion in imaging studies. It is recognized with ultrasound, CT, MRI, and delayed scans of scintigraphy. The "Phrygian cap" gallbladder is considered to empty at a normal rate. The folded fundus of the gall bladder, referred to as the Phrygian cap, was reported in 3%-7.5% of the 14 cases by Lichtenstein & Nicosia (1955) due to disproportion between the size of the gall bladder and that of the gall bladder bed. Deutsch (1986) found this anomaly in 0.33% and considered it as non-developed form of congenital septum. Gore et al (2000) found it in 1%-6% of population and observed a fold or septum between the body and the fundus.

In the present study, folded fundus (Phrygian cap) was found which was similar to that of Lichtenstein & Nicosia (1955) and Gore et al (2000) with presence of a septum as reported by de sepel et al (2003), Chalkoo (2009) and Talpur et al (2010) recently.

It is the most common congenital anomaly of the gallbladder and can simulate a mass in the liver during hepatobiliary imaging, which may suggest a tumour. It can also simulate a duplication of the gallbladder. It is a benign anatomical abnormality, per se usually

asymptomatic unless complicated with calculus or a calculus cholecystitis. Gall bladder with Phrygian cap deformity can lead to misdiagnosis of gall bladder stones on B-mode ultrasonography.

Preferred mode of diagnosis for Phrygian cap is cholecystigraphy and multi-phase MRI, as Ultrasonography and CT are inconclusive. Phrygian cap has to be differentiated from septate gallbladder, hour glass gall bladder, bilobed gallbladder and other congenital anomalies of gall bladder. Prophylactic cholecystectomy is not indicated in patients with Phrygian cap deformity alone as it is of no pathological significance.

CONCLUSION

The liver, gall bladder and the biliary ductal system develop from the hepatic diverticulum of the foregut, at beginning of the fourth week of development. The diverticulum proliferates into the septum transversum dividing into two parts i.e the cranial part being primodium for the liver and the bile ducts, while the caudal part gives rise to the gall bladder as solitary, external out pouching of the gall bladder wall.

Cholelithiasis which is a pathological entity has been witnessed in cadaveric dissection of present research study conducted, though not accounted because of meager anatomical relevance.

Though the occurrence of bizarre forms of variations of the gallbladder have been well known in form of numerous case reports. These variations may remain asymptomatic but often lead to complications and therefore have definite clinical bearings. Given the fact that most of interventional procedures are done laparoscopically, and there has been phenomenal increase in the number of laparoscopic cholecystectomies in this present era. Comprehensive study of the morphological variations of the gall bladder and their incidence is relatively scarce. The present research study favors prevailing literature.

REFERENCES

1. Aguirre, J.A., Bohler, R.O. & Guraieb, S. Hyperplastic cholecystoses: A new contribution to the Unitarian theory. *American Journal of Roentgenology, Radium Therapy and Nuclear Medicine*, 1969, 107, 1.
2. Beilby, J. Stricture of the gallbladder. *Journal of Pathology*, 1967, 93, 175. Chalkoo, M. Laparoscopic cholecystectomy in a mucocele of gallbladder with a phrygian cap - A case report. *Physicians Academy Physicians Academy*, 2009, 3, 3-5.
3. Charyshkin AL (2013) Cholecystectomy for Large Hartmann's Pouch Spliced with Biliary Pathways. *Int J Biomed*, 3: 27-28.
4. Cherukuri R, Levine MS, Maki DD, Rubesin SE, Laufer I, Rosato EF (1998) Hartmann's pouch: radiographic evaluation of postoperative findings. *Am J Roentgenol*, 171: 1577-1582.
5. de sepel, J., Carroccio, A. & Pomp, A. Soft-tissue images. "Phrygian cap" gallbladder. *Canadian Journal of Surgery*, 2003, 46, 50-51. De Csepel, J. & Pomp, A. Soft-tissue images. "Phrygian cap" gallbladder. *Canadian Journal of Surgery*, 2003, 46, 50-51.
6. Deutsch, A.A., Englestein, D., Cohen, M., Kunichevsky, M. & Reiss, R. Septum of the gallbladder, clinical implications, and treatment. *Postgraduate Medical Journal*, 1986, 62, 453-456.
7. Gore, R.M., Fulcher, A.S., Taylor, A.J. & Ghahremani, G.G. *Textbook of Gastrointestinal Radiology, in Anomalies and Anatomic Variants of the Gallbladder and Biliary Tract*. 2nd ed. WB Saunders Co., Philadelphia, PA, 2000. p. 1305-1320.
8. Harlaftis N., Gray, S.W. & Skandalakis, J.E. Multiple gallbladders. *Surgery*, 1977, 145: 928-934.
9. Jena, P.K., Hardie, R.A. & Hobsley, M. Multiseptate hypoplastic gallbladder. *British Journal of Surgery*, 1977, 64, 192.
10. Jaba R, Shilpi J, Satyam K, Ratna R, Fulzele RG (2013) Embryological Basis and Clinical Correlation of the Rare Congenital Anomaly of the Human Gall Bladder: - "The Diverticulum" - A Morphological Study. *J Clin Diagnostic Res*, 7: 2107-2110.
11. Jutras, J.A., Longtin, J.M. & Levesque, H.P. Hyperplastic cholecystoses: Hickey lecture. *American Journal of Roentgenology, Radium Therapy and Nuclear Medicine*, 1960, 83, 795.
12. Lakshmi Kumari K, Vijaya Babu PVSS (2014) Hartmann's Pouch - A study in North Coastal Andhra Pradesh, India. *J Dent Med Sci*, 13: 61-62.
13. Lichtenstein, M. & Nicosia, A.J. The clinical significance of accessory hepato-biliary ducts. *Annals of Surgery*, 1955, 141: 120-124.
14. Mohan gallbladder. *Canadian Journal of Surgery*, 1965, 8, 84. Rafailidis, V., Varelas, S., Kotsidis, N., Rafailidis, D. & Presentation, C. Two congenital anomalies in one: An ectopic gallbladder with Phrygian cap deformity. *Case Reports in Radiology*, 2014, 2014, 1-4. B. Septate
15. Rajguru J, Khare S, Jain S, Ghai R, Singla M, Goel P (2012) Variations in the external morphology of gall bladder. *J Anat Soc India*, 61: 9-12.
16. Talpur, K.A., Laghari, A.A., Yousfani, S.A., Malik, A.M., Memon, A.I. & Khan, S.A. Anatomical variations and congenital anomalies of extra hepatic biliary system encountered during laparoscopic cholecystectomy. *Journal of Pakistan Medical Association*, 2010, 60, 89-93.
17. Toombs, B.D., Foucar, E., Rowlands, B.J. & Stray, R. Multiseptate gallbladder. *Southern Medical Journal*, 1982, 75, 610.