VOLUME-8, ISSUE-5, MAY-2019 • PRINT ISSN No. 2277 - 8160

Original Research Paper

Ophthalmology

ROLE OF SINGLE DOSE OF INTRAVITREAL RANIBIZUMAB IN RETINITIS PIGMENTOSA ASSOCIATED CYSTOID MACULAR EDEMA--- A RETROSPECTIVE STUDY.

Dr. Kaushik Sadhukhan — Assistant Professor, Department of ophthalmology, Malda medical college.

Dr. Subhrajyoti Naskar* — Assistant Professor, Department of Community Medicine, Malda Medical College *Corresponding Author

Dr. Dhritashree Mandal — Clinical Tutor, Department of Plastic Surgery, NRS Medical college.

ABSTRACT

Purpose: To study the effect of single dose of intravitreal Ranibizumab(0.5mg) under topical anaesthesia in cystoid macular edema(CME) associated with Retinitis pigmentosa(R.P) over the period of 6 months.

Methodology: 11 eyes of 11 patients with cystoid macular edema associated with Retinitis pigmentosa were taken into our study. After detailed history taking and detailed systemic and ocular examinations and spectral domain OCT to measure central macular thickness(CMT), prior informed consent and institutional clearance, we have administered single dose of intravitreal Ranibizumab(0.5mg) under topical anaesthesia to each patient. There after CMT was measured after 1month, 3 months, 6 months of injection respectively. Then we have used paired T test (with the help of SPSS software) to get the required statistical data. This is hospital based experimental uncontrolled clinical trial.

Conclusion: Intravitreal Ranibizumab may be an effective tool to deal with RP-CME for the duaration of few months but prospective trials of longer duration are definitely needed to achieve concrete conclusion.

KEYWORDS : BCVA= Best corrected visual acuity, CMT= Central macular thickness, OCT= Ocular coherence tomography, RP-CME= Retinitis pigmentosa associated cystoid macular edema.

INTRODUCTION:

Retinitis pigmentosa(RP) is a hereditary retinal disorder where cystoid macular edema(CME) may be present in 10-40% cases (1-4). Initially RP causes night blindness and progressive peripheral visual field loss but later on central vision becomes compromised due to CME(5) which can be treated. The pathogenesis of RP-CME is not established but may be owing to breakdown of the blood- retinal barrier(6,7,8,9) or impairment of retinal pigment epithelium pump mechanism(10) or Muller cell dysfunction(11) or vitreous traction and epiretinal membrane formation leading to mechanical damage of Muller cells(12,13). Treatment modalities mainly include carbonic anhydrase inhibitors(9,14) and steroids (oral, periocular, intravitreal)(15,16,17,18), topical nonsteroidal anti inflammatory such as ketorolac(19). Intravitreal anti-VEGF were also tried because it decreases permeability of choroidal vessels thus reducing CME(20). Ranibizumab is a VEGF inhibitor which antagonizes all isoforms of VEGF receptors including VEGF-A.

METHODOLOGY:

We conducted this hospital based experimental uncontrolled clinical trialfrom august 2016 to july 2018 in Malda Medical College in West Bengal. We have taken 11 eyes of 11 patients of RP who were having CME at their presentation. At first detailed history taking was done including age, sex, age of onset of night blindness, gradual painless progressive visual loss and family history of same disease, any systemic disease etc. Then detailed systemic examination including cardiological and neurological examination and detailed ocular examination including best corrected visual acuity(BCVA), intraocular pressure measurement with Goldmans applanation tonometer, fundal evaluation under mydriasis with the help of 90 D lens, 78 D lens, indirect ophthalmoscope were done. There after each and every patient was advised to undergo spectral domain OCT to evaluate the macular status and measure the central macular thickness(CMT). Then after proper written informed consent from patients and institutional clearance, single dose of Ranibizumab (0.5 mg) was injected intravitreally under topical anaesthesia with utmost care to each patient. BCVA and OCT to evaluate CMT were done in each case after 1month, 3 months, 6 months of that injection. Here normal CMT was taken as 250 micron. Significant improvement in CMT was considered when it became below 300 micron after 6 months. Then we have used paired T test (with the help of SPSS software) mainly to assess the changes in CMT.

RESULTS:

In our study all 11 patients were male in the age range of 25 years to 35 years. Out of 11 eyes, 8 showed significant improvement in CMT after 6 months but no statistically significant difference in BCVA was proven among the patients. Here is the data which we derived from the paired T test(By using the SPSS software) mainly to evaluate the changes in CMT after intravitreal Ranibizumab 1month, 3 months, 6 months respectively.

In relation to CMT: (Total number of patients 11):

	I Month after intervention	3 Months after intervention	6 months after intervention
Mean before intervention(MI)	184.273	184.273	184.273
SD before intervention(SD1)	54.195	54.195	54.195
Mean after intervention(M2)	106.727	153.364	112.455
SD after intervention(SD2)	45.098	46.294	39.447
P value	<0.05	<0.001	<0.001

It was clearly evident from the above table, the p values 1month, 3months, 6 months after intervention are <0.05,< 0.001 , <0.001 respectively and all of these values are statistically significant. So we can state that intravitreal Ranibizumab can be a reliable weapon to handle cystoid macular edema associated with Retinitis pigmentosa for a short span of time but we can not derive concrete decisison about its role for prolonged time.

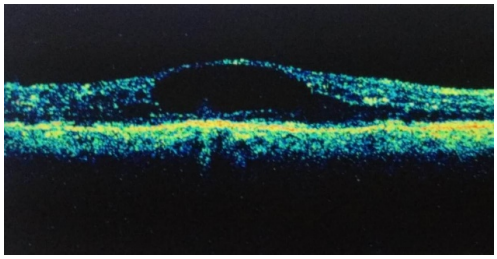

FIG 1 (OCT picture) (Patient with CME in R.P before intervention)

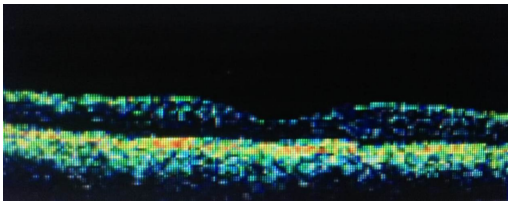

FIG 2 (OCT picture) (CME resolved significantly 6 months after intervention)

DISCUSSION AND CONCLUSION:

CME is one of the complications of RP which impairs vision but its pathogenesis stillremains inconclusive. Again clinical trials for R.P is very difficult to be built up because of highly variable disease course, significant genetic and allelic heterogenicity and very slow progression to visual loss. Although single dose of intravitreal Ranibizumab(0.5mg) gives promising result in terms of improvement of RP-CME as evidenced by reduction of CMT after 6 months of injection, RP-CME is potentially reversible phenomenon. However the improvement in BCVA is not statistically proven. Hence proper and clear cut understanding of its pathogenesis as well as long term prospective clinical trials are mandatory to draw a decisive conclusion regarding management of RP-CME including the role of intravitreal anti-VEGF therapy in it

REFERENCES:

1. Hajali M, Fishman GA, Anderson RJ. The prevalence of cystoid macular oedema in retinitis pigmentosa patients determined by optical coherence tomography. Br J Ophthalmol 2008;92:1065–8. 10.1136/bjo.2008.138560 [PubMed] [CrossRef] [Google Scholar]
2. Testa F, Rossi S, Colucci R, et al. Macular abnormalities in Italian patients with retinitis pigmentosa. Br J Ophthalmol 2014;98:946–50. 10.1136/bjophthalmol-2013-304082 [PMC free article] [PubMed] [CrossRef] [Google Scholar]
3. Adackapara CA, Sunness JS, Dibernardo CW, et al. Prevalence of cystoid macular edema and stability in OCT retinal thickness in eyes with retinitis pigmentosa during a 48-week lutein trial. Retina (Philadelphia, Pa) 2008;28:103–10. 10.1097/IAE.0b013e31809862aa [PubMed] [CrossRef] [Google Scholar]
4. Ozdemir H, Karacorlu M, Karacorlu S. Intravitreal triamcinolone acetonide for treatment of cystoid macular oedema in pati6. Scorolli L, Morara M, Meduri A, et al. Treatment of cystoid macular edema in retinitis pigmentosa with intravitreal triamcinolone. Arch Ophthalmol 2007;125:759–64. 10.1001/archopht.125.6.759 [PubMed] [CrossRef] [Google Scholar]
5. Scorolli L, Morara M, Meduri A, et al. Treatment of cystoid macular edema in retinitis pigmentosa with intravitreal triamcinolone. Arch Ophthalmol 2007;125:759–64. 10.1001/archopht.125.6.759 [PubMed] [CrossRef] [Google Scholar]
6. Kent D, Vinores SA, Campochiaro PA. Macular oedema: the role of soluble mediators. Br J Ophthalmol 2000;84:542–5. 10.1136/bjo.84.5.542 [PMC free article][PubMed] [CrossRef] [Google Scholar]
7. Vinores SA, Derevjanik NL, Ozaki H, et al. Cellular mechanisms of blood-retinal barrier dysfunction in macular edema. Doc Ophthalmol 1999;97:217–28. 10.1023/A:1002136712070 [PubMed] [CrossRef] [Google Scholar]
8. Rizzolo LJ. Polarity and the development of the outer blood-retinal barrier. Histol Histopathol 1997;12:1057–67. [PubMed] [Google Scholar]
9. Vinores SA. The retina and its disorders. Breakdown of the blood-Retinal Barrier. Oxford: Elsevier, 2010:52. [Google Scholar]
10. Hamann S. Molecular mechanisms of water transport in the eye. Int Rev Cytol2002(215):395–431. 10.1016/S0074-7696(02)15016-9 [PubMed] [CrossRef] [Google Scholar]
11. Reichenbach A, Wurm A, Pannicke T, et al. Muller cells as players in retinal degeneration and edema. Graefes Arch Clin Exp Ophthalmol 2007;245:627–36. 10.1007/s00417-006-0516-y [PubMed] [CrossRef] [Google Scholar]
12. Garcia-Arumi J, Martinez V, Sararols L, et al. Vitreoretinal surgery for cystoid macular edema associated with retinitis pigmentosa. Ophthalmology 2003;110:1164–9. 10.1016/S0161-6420(03)00259-8 [PubMed] [CrossRef] [Google Scholar]
13. Schepens CL, Avila MP, Jalkh AE, et al. Role of the vitreous in cystoid macular edema. Surv Ophthalmol 1984;28(Suppl):499–504. 10.1016/0039-6257(84)90232-7 [PubMed] [CrossRef] [Google Scholar]
14. Liew G, Moore AT, Webster AR, et al. Efficacy and prognostic factors of response to carbonic anhydrase inhibitors in management of cystoid macular edema in retinitis pigmentosa. Invest Ophthalmol Vis Sci 2015;56:1531–6. 10.1167/iovs.14-15995 [PubMed] [CrossRef] [Google Scholar]
15. Penfold PL, Wen L, Madigan MC, et al. Triamcinolone acetonide modulates permeability and intercellular adhesion molecule-1 (ICAM-1) expression of the ECV304 cell line: implications for macular degeneration. Clin Exp Immunol 2000;121:458–65. 10.1046/j.1365-2249.2000.01316.x [PMC free article] [PubMed] [CrossRef] [Google Scholar]
16. Moshfeghi DM, Kaiser PK, Scott IU, et al. Acute endophthalmitis following intravitreal triamcinolone acetonide injection. Am J Ophthalmol 2003;136:791–6. 10.1016/S0002-9394(03)00483-5 [PubMed] [CrossRef] [Google Scholar]
17. Roth DB, Chieh J, Spirn MJ, et al. Noninfectious endophthalmitis associated with intravitreal triamcinolone injection. Arch Ophthalmol 2003;121:1279–82. 10.1001/archopht.121.9.1279 [PubMed] [CrossRef] [Google Scholar]
18. Jonas JB, Hayler JK, Sofker A, et al. Intravitreal injection of crystalline cortisone as adjunctive treatment of proliferative diabetic retinopathy. Am J Ophthalmol2001;131:468–71. 10.1016/S0002-9394(00)00882-5 [PubMed] [CrossRef] [Google Scholar]
19. Park S, Lim LT, Gavin MP. Topical steroidal and nonsteroidal antiinflammatory drugs for the treatment of cystoid macular edema in retinitis pigmentosa. Retin Cases Brief Rep 2013;7:134–6. 10.1097/ICB.0b013e31825a300f [PubMed] [CrossRef] [Google Scholar
20. Brown DM, Heier JS, Ciulla T, et al. Primary endpoint results of a phase II study of vascular endothelial growth factor trap-eye in wet age-related macular degeneration. Ophthalmology 2011;118:1089–97. 79. Brown DM, Heier JS, Ciulla T, et al. Primary endpoint results of a phase 10.1016/j.ophtha.2011.02.039 [PubMed] [CrossRef] [Google Scholar]