

ANESTHETIC MANAGEMENT OF POST ACID INGESTION ESOPHAGOPLEURAL FISTULA POSTED FOR FISTULA REPAIR – CASE REPORT

Dr. Shakuntala Goswami	Associate Professor, Department of Anaesthesiology, B.J. Medical College, Ahmedabad.
Dr. Dhvani Trambadia*	3rd Year Resident, Department of Anaesthesiology, B.J. Medical College, Ahmedabad. *Corresponding Author
Dr. Aarti vaghasia	3rd Year Resident, Department of Anaesthesiology, B.J. Medical College, Ahmedabad.
Dr. Payal Yadav	3rd Year Resident, Department of Anaesthesiology, B.J. Medical College, Ahmedabad.
Dr. Anjali Sahoo	3rd Year Resident, Department of Anaesthesiology, B.J. Medical College, Ahmedabad.
Dr. Monika	2nd Year Resident, Department of Anaesthesiology, B.J. Medical College, Ahmedabad.

ABSTRACT

Introduction:-The esophagopleural fistula can occur as an iatrogenic complication due to trauma followed by repeated dilatation of esophagus in a patient's of post acid ingestion stricture of esophagus. There are chances of difficult airway in such kind of patient due to distorted oral, pharyngeal and glottic anatomy. In this case lung isolation provided with double lumen tube insertion.

Aims :- are protection of the healthy lung, improve exposure of surgical field, provide hemodynamic stability and adequate analgesia for pain relief. Patient was managed successfully with GA+thoracic epidural with double lumen tube insertion.

Result:- Perioperative period was uneventful with lung isolation and excellent pain relief with thoracic epidural analgesia.

Conclusion: Such patient can be managed successfully with good lung isolation, adequate analgesia and continuous hemodynamic monitoring with IBP and CVP.

KEYWORDS : Esophagopleural Fistula, Post Acid Ingestion**INTRODUCTION:-**

Acquired esophagopleural fistula is not so common. Likely causes of fistula are tuberculosis, carcinoma, post pneumonectomy and as a part of iatrogenic procedure (most common variety).

Case history:- A 22 year old female posted for fistula repair for left esophagopleural fistula. Patient had past history of acid ingestion before 2 years. She underwent Upper GI endoscopy multiple times under GA for esophageal stricture dilation. After last endoscopy patient developed difficulty in breathing which was insidious in onset gradually progressive then patient was diagnosed as esophagopleural fistula and hydropneumothorax for which ICD inserted on left side.

General Examination :- patient was poorly built and cachectic and pallor was present. (weight 42 kg, height 152 cm). In systemic examination specially

Respiratory system:- decreased air entry over left lung with ICD in situ on left side with good chest movement. All routine investigations were within normal limits except PFT suggestive of moderate obstruction and haemoglobin. HB was 9.6 gm%. IDL (indirect laryngoscopy) examination showed bilateral vocal cords normal and mobile. Fibrotic band extending from epiglottis to posterior pharyngeal wall and lateral pharyngeal wall. ABGA (arterial blood gas analysis): pre op ABGA shows Po₂-96.6, pCO₂-37.8, PH 7.4, HCO₃-24.5, Spo₂-99.6%. Chest radiograph showed air fluid level in left lower lung field. Blunted left CP angle and ICD noted on left upper zone. ICD in situ left side. Barium swallow examination showed fistulous communication between esophagus and left pleura

Figure I. fistulous tract between esophagus and pleura

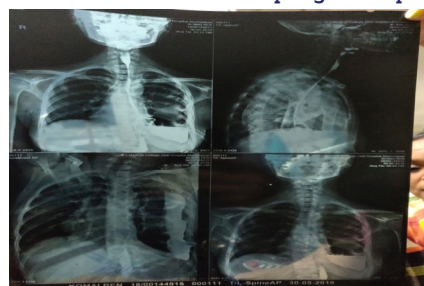
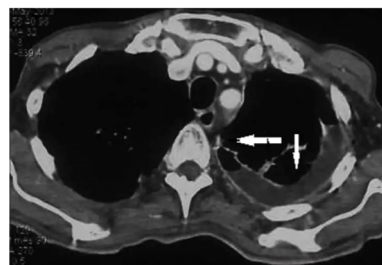


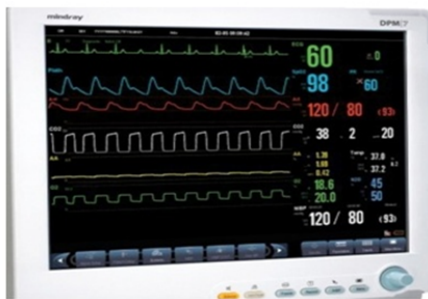Figure II. CT thorax showed Left hydropneumothorax with esophagopleural fistula.



The patient was electively posted for Thoracotomy ligation of fistula. Pre operative optimization :- appropriate antibiotic therapy, bronchodilators, nebulization, airway humidification, chest physiotherapy and incentive spirometry was done to facilitate her postoperative recovery. Patient's relative were explained the risk of anesthesia and informed written consent was taken in ASA IV with post op ventilator support. Anesthesia plan:- we planned General anesthesia using DLT for lung isolation and thoracic epidural catheter insertion for

periop analgesia. Patient was taken inside the OT and routine monitors were applied (ECG, BP, SPO₂, Temperature) and urine output was monitored. In OT two large wide bore peripheral intravenous access was secured in the operation theatre. Central venous access was secured in the right internal jugular vein and arterial line was secured in right radial artery under ultrasonography guidance. Invasive blood pressure monitoring was done after arterial line placement. In Premedication glycopyrrolate (4 mcg/kg), ondansetron (0.15 mg/kg), fentanyl (2 mcg/kg) given intravenously. Thoracic epidural catheter placed in sitting position at D7-D8 level. Test dose xylocaine 2% 2 cc given in epidural. General anaesthesia was given with propofol (2.5 mg/kg) and suxamethonium (2 mg/kg). Intubation was done with right sided cuffed double lumen tube number 32. As anatomy was distorted we faced difficulty in intubation as well as positioning of double lumen tube (DLT) which required two attempts for placement. Confirmation was done with ETCO₂ monitoring. Proper placement of position was done with alternate clamping of tracheal and bronchial lumen of tube with simultaneous auscultation of lung field. Maintenance was done with oxygen, sevoflurane and vecuronium (0.1 mg/kg) ventilation of both lung was continued until positioning of the patient. Thereafter right lateral position was given and the left lung was isolated and right lung was ventilated through the bronchial lumen of the DLT. Ventilatory settings was tidal volume of 250 ml and frequency of 16 per minute. Pressure points were taken care. Analgesia was provided with volume of 8 ml 0.25% bupivacaine was given as epidural bolus.

Figure III. Intra operative monitoring



All measures to maintain hypoxic pulmonary vasoconstriction (HPV) were taken. Intermittent suctioning was performed. Intraoperative ABGA revealed satisfactory oxygenation. Thoracotomy ligation of fistula was performed. Bronchial stump integrity was checked by applying positive end expiratory pressure (PEEP). Esophageal plaything was sutured. Intraoperative 2 packed cell volume (PCV) total 480 ml and 1000 ml NS and 500 ml RL and 500 ml DNS given. Urine output was 1350 ml at the end of surgery. Intraoperative period was uneventful with no complications. Reversal was started after return of spontaneous respiratory attempts. Patient was given inj glycopyrrolate (8 mcg/kg) IV and inj neostigmine (0.05 mg/kg) IV. After through suctioning DLT removed. After extubation patient was conscious and following verbal command. Patient was given nebulisation with salbutamol and budesonide. Post op ABGA was within normal limits. Duration of surgery was 4.5 hr and post op patient was stable and shifted to ICU for observation. Contrast esophagogram performed after 10 days showed "NO LEAK" and ICD was removed after which she was discharged.

DISCUSSION:-

GOALS of anesthesia in such kind of patients are :-

1. difficult intubation due to post acid ingestion distorted laryngeal and pharyngeal anatomy.
2. difficulty in oxygenation and/or ventilation depending on

the size and the site of fistula

3. Prevention of sudden hypoxemia during one lung ventilation (OLV)
4. maintenance of HPV
5. ventilatory management during handling of the airway by surgeons.
6. prevention of soiling of normal dependent lung
7. post operative analgesia to facilitate early recovery

such kind of patient's require lung isolation and that can be provided by DLTs which prevent soiling of other lung, and allows suctioning of the affected lung during surgery. Maintenance of HPV can be done with CPAP to the lung being operated. PEEP can be applied/continuous oxygen sufflation with catheter to the dependent lung. central venous access with monitoring of CVP ensures optimal fluid management perioperatively as thoracic surgeries are associated with major fluid shifts and it is important to avoid overhydration as water-logging of the healthy lung adversely affects the outcome by delaying weaning. Continuous IBP monitoring helps to maintain hemodynamic stability and intermittent ABGA monitoring

CONCLUSION:-

Optimal ventilatory management with ONE LUNG ANESTHESIA, fluid management guided by CVP, IBP and ABGA (oxygenation and ventilation) excellent intraoperative and postoperative analgesia with thoracic epidural, and the team efforts by the anesthetist and surgeon provide the best possible outcome.

ACKNOWLEDGEMENT:-

I acknowledge my teacher Dr. Shakuntala Goswami (Associate Goswami) for their constant guidance and inspiration.

Disclaimer :-

I dr dhvani trambadia wants to verify that the views expressed in the article are mine, and not an official position of the institution or funder.

REFERENCES:-

1. Manoranjan Dash, Thitta Mohanty, priyadarsini Parida. Esophagopleural fistula. lung india. 2017 may june 287-289.
2. Didee R, shaw IH. Acquired trachea oesophageal fistula in adults. contin Educ Anaesth critic care pain 2012. 12:105-108.
3. Wechsler RJ, steiner RM, Goodman LR, Teplick SK, Mapp E, Laufer I. Iatrogenic esophageal-pleural fistula. subtlety of diagnosis in the absence of mediastinitis. radiology. 1982; 144:239-43 [pubmed]
4. Manoj kumar Pattnaik, Sameer kumar panigrahy. Esophagopleural fistula-a rare case report. indian journal of thoracic and cardiovascular surgery. volume 31. page number 316-319.
5. spalding AR, burney DP, Richie RE. acquired benign bronchoesophagopleural fistula in the adult. thorax surg 1979; 28:378-383