



INFECTED DENTIGEROUS CYST WITH UNERUPTED TOOTH

Dr. M. K Rajasekar	Professor, Dept Of Ent, Sree Balaji Medical College, Chennai.
Dr. Sridhara Narayanan*	Professor, Dept Of Ent, Sree Balaji Medical College, Chennai. *corresponding Author
Dr. Pravilika	Junior Resident, Dept Of Ent, Sree Balaji Medical College, Chennai.

ABSTRACT

Dentigerous cysts are odontogenic cysts associated with crown of impacted or unerupted tooth. They commonly occur in middle aged individuals and are believed to originate from the epithelial remnants of tooth forming organs. Dentigerous cyst can occur in the first decade of life in some rare cases. They are usually diagnosed on imaging when evaluated for delayed eruption. We hereby present a case of 23 year old female who came with complaints of right sided facial pain and asymmetry for 7 years associated with history of surgery for the same. Patient was evaluated and underwent complete excision of the cyst along with removal of the impacted unerupted tooth. Management options include conservative measures, enucleation, excision or marsupialization. This report throws light on how management of the dentigerous cyst by excision was the suitable treatment of choice for this patient.

KEYWORDS : Unerupted Tooth, Dentigerous Cyst, Excision

INTRODUCTION :

Odontogenic cysts are a group of common lesions – thought to be of developmental origin that commonly involve the maxilla and the mandible and frequently cause destruction of these bones. These cysts are seldom discovered in young individuals since they frequently occur in individuals between 20 and 40 years of age. These cysts are discovered unexpectedly on routine radiographic examination since they are asymptomatic unless after an infection. On imaging, these cysts may appear unilocular with well circumscribed margins. Infected cysts show ill-defined margins. Histologically these cysts are lined by non-keratinized stratified squamous epithelium. Various modalities of management from marsupialization to enucleation have been reported in literature. The common treatment for DC is enucleation followed by extraction of the involved tooth. In cases where the cyst is large, then the management is two staged which includes marsupialization to decrease the size of the osseous defect followed by enucleation and and extraction of tooth. Enucleation is the choice of treatment whenever the cyst is small and saving the involved tooth is impossible. When diagnosed at a late stage, they are usually managed by enucleation and by the extraction of the involved tooth.

CASE REPORT :

A 23 year old female presented to our OPD with chief complaints of left sided facial pain, asymmetry for 7 years. Patient has undergone surgery for the same 7 years back details of which were unknown. Upon examination, patient had her all permanent teeth associated with over crowding and small cystic swelling over the gingiva-buccal sulcus above the incisors. CT PNS was done which revealed dentigerous cyst in the left maxillary sinus causing left pre-maxillary bulge and intra osseus cyst in the right maxillary cavity.

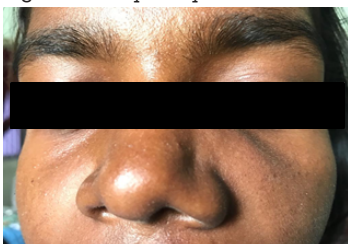

Fig 1 showing facial asymmetry on the left side

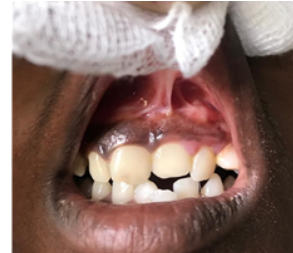

Fig 2 showing small cystic swelling over the left gingiva buccal sulcus above

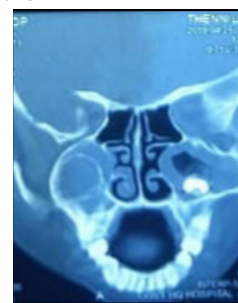

Fig 3 CT PNS coronal cut showing dentigerous cyst with unerupted tooth in right maxillary cavity

Based on the clinical and radiological evidence, a provisional diagnosis of dentigerous cyst was made. Patient underwent complete excision of the cyst with removal of the uninterrupted tooth by a gingiva buccal incision. Specimen was sent for HPE which revealed non-keratinized squamous epithelium suggestive of dentigerous cyst.

Post operative healing was satisfactory with no recurrence.

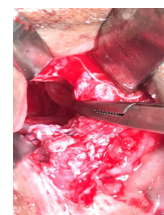


Fig 4

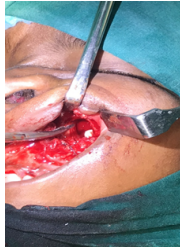

Fig 5
Fig 4 & 5 showing intra-op pictures

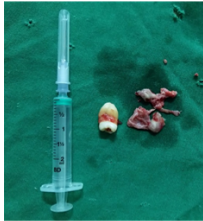

Fig 6 showing excised cyst with unerupted tooth.

DISCUSSION :

Dentigerous cyst also called as follicular cyst is a odontogenic cyst which is of developmental origin. The term dentigerous the literal meaning "tooth bearing." The cyst is usually lined by epithelial cells which is derived from the enamel epithelium of the tooth forming organ. The etiology behind accumulation of exudate between the reduced enamel epithelium and the crown may be due to the pressure exerted by an erupting tooth on the follicle thereby leading to formation of cyst.

Odontogenic keratocyst, adenomatoid odontogenic tumor, and ameloblastic fibroma can mimic a dentigerous cyst. A suspicion of other lesions can arise when the follicular space is larger than 5 mm in diameter.

Another factor which could be triggering the cyst formation in addition to developmental origin is the periapical inflammation of a non-vital deciduous teeth which are in proximity to the follicles of unerupted permanent successors. Occasionally the dentigerous cyst may give rise to mucoepidermoid/ameloblastoma/squamous cell carcinoma.

These cysts have the tendency to become large in size and can cause displacement of teeth or it may remain relatively small in a few cases. The age range varies widely, from 5 years to 57 years.[3] Many dentigerous cysts are small asymptomatic lesions that are discovered serendipitously on routine radiographs. Some may cause bony expansion that is usually painless until secondary infection occurs if they are large in size. Early detection and management of these cysts is important to reduce morbidity as they can grow to varying sizes.

Three types of dentigerous cyst have been described radiographically: central type, in which the radiolucency surrounds just the crown of the tooth, with the crown projecting into the cyst lumen. In the lateral type, the cyst develops laterally along the tooth root and partially surrounds the crown, the circumferential type, the crown is surrounded by the cyst and the cyst contains the entire tooth. Our case was a classic presentation of the circumferential variety.

CONCLUSION :

Dentigerous are the most common developmental cysts. Early detection and prompt management is required to prevent the lesion from becoming an aggressive one causing gross expansion of bone with subsequent facial asymmetry, pain,

displacement of teeth, and root resorption as it commonly involves young individuals.

Marsupialization can be the treatment of choice, whereas in the present case, excision was done taking into account the poor oral hygiene, cooperation and the socioeconomic status of the patient.

The prognosis is good which are generally diagnosed by histopathology, recurrence being a rare finding.

REFERENCES :

1. Delbem AC, Cunha RF, Afonso RL, Bianco KG, Idem AP. Dentigerous cyst in primary dentition- Report of 2 cases. *Pediatr Dent* 2006;28:269-72.
2. Naclério H, Simões WA, Zindel D, Chilvarquer I, Aparecida TA. Dentigerous cyst associated with an upper permanent central incisor: case report and literature review. *J Clin Pediatr Dent* 2002;26:187-92
3. Management of a dentigerous cyst associated with inverted and fused mesiodens: a rare case report. Patel KI, Patel N, Venkataraghavan K.
4. J. M. V. Reyes, J. A. E. Bermúdez, and Y. E. G. Ruisánchez, "Dentigerous cysts: case report," *Journal of Advanced Oral Research*, vol. 7, no. 1, 2016
5. D. W. Anderson and D. Evans, "Dentigerous cyst of mandible presenting as sepsis," *The American Journal of Emergency Medicine*, vol. 32, no. 12, pp. 1561.e3-1561.e4, 2014.
6. An infected dentigerous cyst associated with an impacted permanent maxillary canine, inverted mesiodens and impacted supernumerary teeth. Karthik Rajaram Mohan, Balan Natarajan, Sudhaamani Mani, Yasmeen ahmed Sahuthullah, Arivukkadal Vijaya Kannan, and Haritha Doraiswamy.
7. Browne RM. The pathogenesis of odontogenic cysts: A review. *J Oral Pathol*. 1975;4:31-46