



EFFECT OF LENGTH OF SACRAL VESTIBULE S1 AND S2 ON MORPHOMETRIC ANALYSIS OF SACRAL VESTIBULE S1 AND S2 USING PLAIN COMPUTED TOMOGRAPHY IN NORTH INDIAN POPULATION

Dr. Tarun Kumar

Dr. Rajendra Prasad, Government Medical College, Kangra at Tanda, Himachal Pradesh

Dr.Devinder Kumar*

Dr. Rajendra Prasad, Government Medical College, Kangra at Tanda, Himachal Pradesh *Corresponding Author

ABSTRACT

Background: The present study was aimed to study and develop in-depth understanding of the effect of the length of sacral vestibule S1 and S2 on morphometry of sacral vestibule in North-West Indian population presenting to our institution, which will go a long way in planning to treat the posterior pelvic injuries with percutaneous screws, thereby reducing the morbidity associated with open fixation.

Methods: This study was conducted in the Department of Orthopaedics and Radiodiagnosis at Dr Rajendra Prasad Govt. Medical College, Kangra at Tanda over a period of one year. All the patients of the age > 18 years and above submitting for either abdominal, lower spinal or non-orthopaedic pathology of pelvic region, presenting for computed tomography to the Department of Radiodiagnosis were included in the study.

Results: The length of vestibule of S1 and S2 ranged from 98.60 to 128.2 mm with a mean value of 112.08 ± 6.21 mm and from 108.20 to 128.60 mm with a mean of 128.60 ± 11.85 mm respectively. There was a weak relation between length of vestibule of S1 and age-groups 18-30 years ($r=0.042$; $P=0.595$), 31-40 years ($r=0.016$; $P=0.885$), 41-50 years ($r=-0.128$; $P=0.140$), 51-60 years ($r=0.005$; $P=0.945$), and >60 years ($r=-0.107$; $P=0.740$). There was a weak relation between length of vestibule of S2 and age-groups 18-30 years ($r=0.025$; $P=0.758$), 31-40 years ($r=0.002$; $P=0.987$), 41-50 years ($r=-0.130$; $P=0.134$), 51-60 years ($r=-0.093$; $P=0.173$), and >60 years ($r=-0.406$; $P=0.190$). There was significant difference in length of vestibule of S1 ($P=0.001$) and S2 ($P=0.041$) between males and females. There was a weak relation between interspinous distance with length of vestibule of S1 ($r=0.501$; $P=0.001$) and S2 ($r=-0.012$; $P=0.759$).

Conclusion: The present study, the first of its kind in North Western part of India arrived to help us anthropometric measurements of sacral vestibule, thereby, helping in development of local protocols for percutaneous fixation in sacral fracture.

KEYWORDS : Sacral Vestibule, length of the Vestibule, Interspinous distance.

INTRODUCTION

The sacral bone is an inverted triangle that sits obliquely between the two innominate bones of the pelvis at the distal aspect of the spinal column. It functions mechanically to convey axial load from the lumbar spine into the lower extremities for balanced locomotion. The ventral sacral body is concave and derived from five vertebrae. The transverse processes of the sacral vertebrae coalesce to form the sacral ala, which projects laterally from the upper sacral promontory.¹

The standard treatment of unstable sacral fractures is surgical fixation due to a high incidence of residual morbidity under conservative treatment. The primary goal is anatomic reduction, followed by a rigid fracture fixation. There are several operating techniques like fixation with iliosacral screws or plates, triangular osteosynthesis, ilioiliac (plates, internal fixators, and bars) and trans-sacral screws or bars. In recent years, sacroiliac screws and spinopelvic internal fixators have become the preferred implants for fixation of posterior pelvic ring fractures. Whereas full weight bearing is allowed for most spinopelvic fixations, none or partial weight bearing is recommended for iliosacral screw fixations.²

The present study was aimed to study and develop in-depth understanding of the morphometry of sacral vestibule in North-West Indian population presenting to our institution, which will go a long way in planning to treat the posterior pelvic injuries with percutaneous screws, thereby reducing the morbidity associated with open fixation.

MATERIALS AND METHODS

This study was conducted in the Department of Orthopaedics and Radiodiagnosis at Dr Rajendra Prasad Govt. Medical College, Kangra at Tanda over a period of one year. All the patients of the age > 18 years and above submitting for either

abdominal, lower spinal or non-orthopaedic pathology of pelvic region, presenting for computed tomography to the Department of Radiodiagnosis were included in the study. The patients were informed about the aims and methods of the study and once consent was given for participation; they were evaluated. The evaluation included clinical assessment for height. This helped to draw comparison while arriving at morphometry of Sacral vestibule.

The following patients were excluded from the study

1. Age < 18 years.
2. The patient with pelvic ring dysmorphism.
3. Osteolytic pelvic lesions.
4. Fractures involving the posterior elements.
5. Post operated cases of above fracture
6. Not willing to participate in the study
7. Implants obscuring the lumbosacral junction.

Each patient and his attendants were adequately informed about the aims, methods, the anticipated benefits and potential risks of the study and the discomfort it might entail them and the remedies thereof. Every precaution was taken to respect the privacy of the patient, the confidentiality of the patient's information and to minimize the impact of the study on his/her physical and mental integrity and personality. The patients were given the right to abstain from participation in the study or to withdraw consent to participate at any time of the study without reprisal. Due care and caution were taken at all stages of the research to ensure that the patient was put to minimum risk, suffer from no irreversible adverse effects and generally, benefit from and by the research. Written informed consent was obtained from all the patients and attendants included in the study.

The subjects included in this study followed the protocol generally used by the Department of Radiodiagnosis for the

conditions mentioned above. The subjects were placed in the supine position with fully extended knee joint with patella facing the sky for CT examination. 3D volume reconstruction of surface anatomy of bony pelvis was then performed using available CT data.

All CT scan were included scanning by anteroposterior tomogram as well as axial images of Sacral Vestibule. All angles were measured at the CT workstation. Measurements of the angles were performed by a junior resident (the investigator) from the Department of Orthopaedics Dr. RPGMC Tanda and were supervised by consulting Orthopaedician and Radiologist.

Following parameters were noted in each patient according to the sex of the patient:

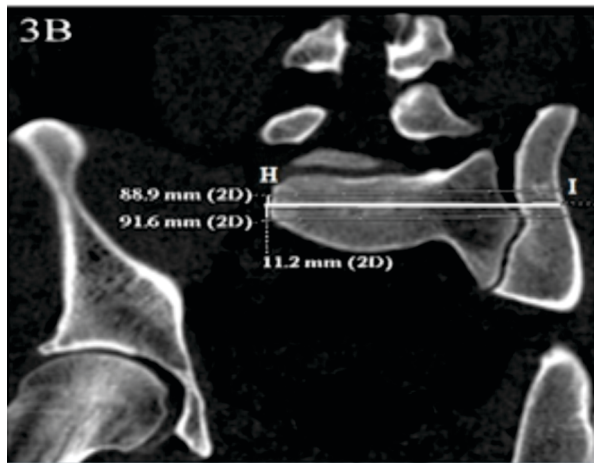
- Age of the patient
- Sex of the patient
- Length of the vestibule S1 and s2
- Interspinus distance

STATISTICAL ANALYSES

Data were presented as frequency, percentages, and median (inter quartile range; IQR). Difference between quantitative variables was compared using Mann Whitney U test. Spearman correlation coefficient was used to find relation between two variables. P value <0.05 was considered significant. Statistical analyses were performed using SPSS v20.

MAXIMUM LENGTH OF VESTIBULE

It was maximum length of a 10-mm-diameter corridor along the axis of the osseous Corridor was measured. This signified the length of iliosacral screw that might be used.



Morphological Analysis of Sacral Vestibule

LENGTH OF THE VESTIBULE (MM)

	S1	S2
Minimum	98.6	108.2
Maximum	128.2	128.6
Mean	112.08±6.21	128.60±11.85
Median	111.5	128
IQR	111.5	128

RELATION WITH AGE (COMPARATIVE ANALYSIS)

	Age-group	Mean±SD	Min-Max	P Value
S1	18-30 ^a	112.13±6.02	98.6-128.1	Pab=0.130; Pac=0.771
	31-40 ^b	110.93±5.59	99.8-124.8	Pad=0.689; Pae=0.059

	41-50 ^c	111.92±5.80	99.7-128.2	Pbc=0.210; Pbd=0.073
	51-60 ^d	112.39±6.67	99.2-128.2	Pbe=0.011; Pcd=0.502
	>60 ^e	115.61±7.50	100.5-124.8	Pce=0.042; Pde=0.108
S2	18-30 ^a	129.12±11.93	108-149	Pab=0.496; Pac=0.886
	31-40 ^b	128.01±12.72	108-149	Pad=0.537; Pae=0.056
	41-50 ^c	129.32±11.39	108-149	Pbc=0.428; Pbd=0.816
	51-60 ^d	128.37±11.69	108-149	Pbe=0.143; Pcd=0.453
	>60 ^e	122.50±12.24	108-140	Pce=0.042; Pde=0.080

The vestibule length of S1 and S2 was not significantly different between different age-groups.

RELATION WITH AGE

		Correlation Coefficient (r)	P Value
S1	18-30	0.064	0.419
	31-40	0.004	0.969
	41-50	-0.162	0.062
	51-60	0.016	0.817
	>60	0.157	0.627
S2	18-30	0.024	0.765
	31-40	0.143	0.189
	41-50	0.027	0.761
	51-60	-0.034	0.621
	>60	0.226	0.479

There was a weak relation between length of vestibule of S1 and age-groups 18-30 years (r=0.064; P=0.419), 31-40 years (r=0.004; P=0.969), 41-50 years (r=-0.162; P=0.062), 51-60 years (r=0.016; P=0.817), and >60 years (r=0.157; P=0.627). There was a weak relation between length of vestibule of S2 and age-groups 18-30 years (r=0.024; P=0.765), 31-40 years (r=0.143; P=0.189), 41-50 years (r=0.027; P=0.761), 51-60 years (r=-0.034; P=0.621), and >60 years (r=0.226; P=0.479).

RELATION WITH SEX

		Male	Female	P Value
S1	Mean±SD	112.83±6.12	111.02±6.19	0.001
	Median	112.2	110.75	
	IQR	7.95	8.63	
S2	Mean±SD	127.77±11.83	129.77±11.81	0.041
	Median	127	130	
	IQR	21	20.25	

There was significant difference in length of vestibule of S1 (P=0.001) and S2 (P=0.041) between males and females.

RELATION WITH INTERSPINUS DISTANCE

	Correlation Coefficient (r)	P Value
S1	-0.030	0.455
S2	0.004	0.925

There was a weak relation between interspinus distance with length of vestibule of S1 (r=0.501; P=0.001) and S2 (r=-0.012; P=0.759).

DISCUSSION

The sacral vestibule refers to the three-dimensional (3D) screw space that is available in the narrowest part of the iliosacral screw channel. The sacral vestibule is located in the transition zone between the sacral wing and sacral body and serves as the entrance to the sacral vertebrae. The vestibule is divided

into two components, the S1 and S2 vestibules. The smaller S2 vestibule is associated with limited tolerance for screw misdirection, which can increase the risk of nerve injury or spinal canal damage. Therefore, S2 vestibules are rarely used for screw replacement. The S1 vestibule, located above the sacral foramina and between the sacral foramina and the slope of the sacral wing, is the isthmus of the transition zone between the sacral wing and the S1 vertebrae. The present study was aimed to morphometrically analyze sacral vestibule using CT at Department of Orthopaedics, Dr RPGMC Kangra at Tanda. A total of 610 patients were included in the study. The present study was aimed to study the effect of length of the sacral S1 and S2 vestibule on morphometric analysis of sacral vestibule using plain computed tomography. A total of 610 patients were included in the study.

The length of vestibule of S1 and S2 ranged from 98.60 to 128.2 mm with a mean value of 112.08 ± 6.21 mm and from 108.20 to 128.60 mm with a mean of 128.60 ± 11.85 mm respectively. There was a weak relation between length of vestibule of S1 and age-groups 18-30 years ($r=0.042$; $P=0.595$), 31-40 years ($r=0.016$; $P=0.885$), 41-50 years ($r=-0.128$; $P=0.140$), 51-60 years ($r=0.005$; $P=0.945$), and >60 years ($r=-0.107$; $P=0.740$). There was a weak relation between length of vestibule of S2 and age-groups 18-30 years ($r=0.025$; $P=0.758$), 31-40 years ($r=0.002$; $P=0.987$), 41-50 years ($r=-0.130$; $P=0.134$), 51-60 years ($r=-0.093$; $P=0.173$), and >60 years ($r=-0.406$; $P=0.190$). There was significant difference in length of vestibule of S1 ($P=0.001$) and S2 ($P=0.041$) between males and females. There was a weak relation between interspinus distance with length of vestibule of S1 ($r=0.501$; $P=0.001$) and S2 ($r=-0.012$; $P=0.759$). There was no relation between height with length of vestibule of S1 ($r=0.068$; $P=0.093$) and S2 ($r=-0.012$; $P=0.766$). The proper location and length, to insert iliosacral screws is parallel to the long diameter with the inclination angle of the vestibule; therefore, these both parameters are very important references for the operation. Due to smaller size in these parameters, the insertion location, direction of the screw, and the position relationships between the screws are particularly limited for female patients³. Sacral variations are common in Indian population; however, these parameters are higher than Chinese populations⁴.

Kaiser et al. observed that S1 and S2 vestibule length was 119.2 ± 35.7 mm and 128.1 ± 20.4 mm respectively⁵. The above-mentioned results were comparable to our study. Therefore, the placement of iliosacral screws should be considered carefully based on the size, gender, height and ethnicity of the patient.

CONCLUSION

The present study, the first of its kind in Northern part of India arrived to help us anthropometric measurements of sacral vestibule, thereby, helping in development of local protocols for percutaneous fixation in sacral fracture.

REFERENCES

1. Sugar O. How the Sacrum Got Its Name. *JAMA*. 1987;257:2061-3.
2. Mehta S, Auerbach JD, Born CT, Chin KR. Sacral fractures. *J Amer Acad Orthop Surg* 2006; 14(12):656-65.
3. Dong Q, Tian W, and Ma B. Evaluation and clinical application of sacral S1 vestibule measurements in Chinese adults. *Int. J. Morphol.* 2014;32(1):202-7.
4. Singh ID, Ajita R, Singh N. Variation in the number of sacral pieces. *IOSR Journal of Dental and Medical Sciences (IOSR-JDMS)*. 2015;14:106-8.
5. Kaiser SP, Gardner MJ, Liu J, Rouff ML Jr, Morshed S. Anatomic determinants of sacral dysmorphism and implications for safe iliosacral screw placement. *J Bone Joint Surg Am* 2014; 96(e120):1-8.