



CONGENITAL PENOSCROTAL URETHROCUTANEOUS FISTULA: A RARE PRESENTATION

Ranjith Kumar Sridhar

Post Graduate, M.S. General Surgery, Sri Ramachandra Institute of Higher Education and Research, Chennai, Tamil Nadu.

Jegadeesh Sundaram*

M. Ch Paediatric Surgery, Assistant Professor, Department of Paediatric Surgery, Sri Ramachandra Institute of Higher Education and Research, Chennai, Tamil Nadu. *Corresponding Author

ABSTRACT

Congenital urethrocuteaneous fistula is an extremely rare but easily manageable anomaly that can either be present in an isolated fashion or in association with other abnormalities of the genitourinary tract like hypospadias or chordee or anorectal malformations. A case of isolated congenital urethrocuteaneous fistula at the penoscrotal junction which was managed surgically by primary tubularisation of exposed urethral plate with tunica vaginalis reinforcement has been reported along with review of literature. Surgical principles will be similar to any hypospadias repair. Treatment of this rare condition is decided according to the site of the fistula, associated anomalies and condition of the distal urethra. A meticulous clinical examination will yield the diagnosis and to rule out other associated anomalies.

KEYWORDS : Congenital, Urethrocuteaneous, Hypospadias, Anorectal

INTRODUCTION

While most of the urethrocuteaneous fistulae are acquired as a complication of hypospadias repair surgery, congenital urethrocuteaneous fistulae (CUCF) are extremely rare with only 64 reported cases since 1962. Penoscrotal position is rare among the reported cases. [1,2] The cause is unclear. However, it may be due to a focal defect in the urethral plate that prevents fusion of urethral folds. [3]

In this study, we describe a case of a congenital penoscrotal urethrocuteaneous fistula that was managed by primary tubularisation of exposed urethral plate with tunica vaginalis reinforcement. Post-operatively, the child recovered well without any complications and is comfortable on follow-up.

Case Presentation

A 10-year-old uncircumcised boy presented to our outpatient clinic with complaints of passing urine through an opening located on the ventral aspect of his penis. There was no history of poor stream of urine or pain during micturition. He had neither history of trauma nor surgical intervention. There was no family history of genitourinary tract malformations. On local examination, a fistula was seen on the ventral aspect of the shaft of the penis at penoscrotal junction, with exposed urethral plate measuring 7 x 3 mm. Distal to the fistula, the spongiosum, preputial skin, and the glans were intact with normal external urethral meatus. The distal and proximal urethra could be negotiated with an 8 French silicon tube without difficulty (Figure1). There were no associated genitourinary or anorectal anomalies. Ultrasound abdomen and cystourethrogram were normal. The child was managed by a circum-fistulous incision, mobilization of the splayed out spongiosa in that region, primary surgical tubularisation of exposed urethral plate over an 8 French silicon catheter, spongiosal repair (Figure2), and reinforcement with tunica vaginalis (Figure3). Catheter was removed on 7th post-operative day, and he had uneventful recovery. On follow up after 6 months, the boy had a good stream of urine through the external urethral meatus (Figure4).

DISCUSSION

Congenital urethrocuteaneous fistula is a rare anomaly which can either be isolated or in conjunction with other genitourinary or anorectal anomalies with a few reported cases. As in a meta-analysis study by Lin Y et al of 63 cases, the least common site of CUCF was at the penoscrotal junction (5/63) while sub-coronal position was most common (33/63) [1]. With extensive review of English language literature, we

could not find any report of any isolated penoscrotal CUCF without associated anomalies, making our case, a first reported case of such nature.

Until 8 weeks of gestation, the male and female external genitalia are identical. The male external genitalia develops under the influence of testosterone. In a growing phallus, the urethral folds coalesce in the midline from base to tip, forming a tubularised penile urethra and median scrotal raphe. At the 11th week, when Leydig cells increase in number and size, urethral folds begin to fuse ventrally in the midline to form urethra. Failure of fusion gives rise to the formation of CUCF. [4]

The etiology however remains unclear and several theories have been stated previously to explain its causes. Olbourne stated that fistulae located in the shaft of the penis is probably due to a focal defect in urethral plate function which may result in a complete defect or a partial deficiency of urethral fold fusion. [3] As theorized by Goldstein, a transient deficiency in testicular evocator substance may lead to a CUCF with chordee. [5] Another theory by Duckett suggested formation of a CUCF by rupture of small diverticulum from the penile urethra. [4] Karnak regarded congenital urethrocuteaneous fistulae (excluding those associated with anorectal anomalies) as a separate set of anomalies. [6] Congenital urethrocuteaneous fistulae may be secondary to embryonic urethral blowouts behind a distal congenital obstruction as suggested by Campbell. [7] As stated by Cook and Stephens in their study, pressure atrophy from the heel of the baby's foot was a potential cause for CUCF. [8] Caldamone et al noted a ventral penile cyst before the spontaneous development of urethral fistula, which was also seen by Knapp who noticed six cases of cysts along the mediogenital raphe at the frenulum. [9,10] Similarly, there was a case report of a baby with postnatal anterior urethrocuteaneous fistula with prenatally identified penile cystic structure. [10]

Surgical approach to repair CUCF depends on the type of fistula. It is of paramount importance to rule out urethral duplication (Y type urethral fistula) which may be associated with anorectal anomalies. Surgical repair follows the principles of hypospadias repair. These include local skin flap, preputial skin flap, Thiersch-Duplay urethroplasty, Denis Brown urethroplasty, buccal mucosal graft and tubularised incised plate urethroplasty with dartos flap and primary closure. [2] The choice of the method of repair is based on the size and the location of the fistula as well as existing other anomalies and the condition of the distal urethra. If there are

associated anomalies like deficient distal urethra or spongiosum, associated chordee or hypospadias, a formal hypospadias repair is recommended.

CONCLUSION

A CUCF is an extremely rare anomaly which is easily manageable and needs meticulous examination to rule other associated anomalies. The type of surgery is based on the patency of the distal urethra, intactness of the distal spongiosum, size of fistula, and the width of exposed urethral plate. Following the principles of hypospadias repair, with proper mobilization and tubularisation, this condition is manageable with high success rate without recurrence.

FIGURES

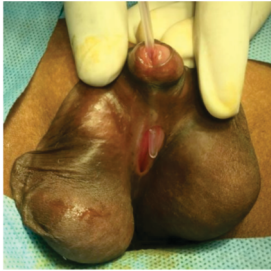

Figure 1

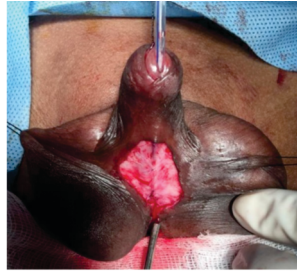


Figure 2

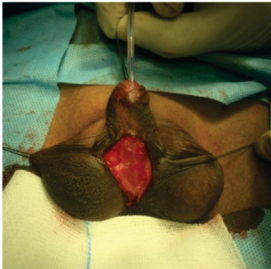

Figure 3

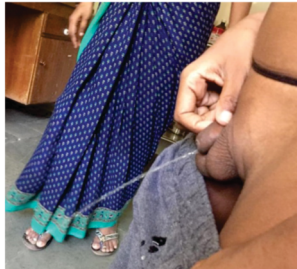

Figure 4

REFERENCES

1. Lin Y, Deng C, Peng Q. Congenital Anterior Urethrocutaneous Fistula: A Systematic Review. *Afr J Paediatr Surg* 2018;15:63-8.
2. Hassan A, Kotb M, Shehata S. Congenital anterior urethrocutaneous fistula: A case report and review of literature. *Urology Case Reports* 2019;27.
3. Olbourne NA. Congenital urethral fistula. Case reports. *Plast Reconstr Surg*. 1976;57:237-9.
4. Kale SM, Mody NB, Patil SB, Sadawarte P. Congenital urethrocutaneous fistula in an adolescent male. *Indian J Plast Surg* 2015;48:204-7.
5. Goldstein M. Congenital urethral fistula with chordee. *J Urol*. 1975;113:138-40.
6. Karmak I, Tanyel FC, Hiçsönmez A. Congenital urethrocutaneous fistula: A case report and literature review, with a nomenclature proposal. *J Pediatr Surg* 1995;30:1504-5.
7. Campbell M: *Clinical Pediatric Urology*. Philadelphia:W. B. Saunders Co.1951:531-3.
8. Cook WA, Stephens FS. Pathoembryology of the urinary tract. In: *Urological Surgery in Neonates and Young Infants*, L. R. King, Ed. Saunders, Philadelphia, USA, 1988.
9. Caldamone AA, Chen SC, Elder JS, Ritchey ML, Diamond DA, Koyle MA, et al. Congenital anterior urethrocutaneous fistula. *J Urol* 1999;162:1430-2.
10. Biswas S, Ghosh D, Das S. Congenital Urethrocutaneous Fistula—Our Experience with Nine Cases. *Indian J Surg* 2014;76:156-8.