VOLUME - 9, ISSUE - 7, JULY - 2020 • PRINT ISSN No. 2277 - 8160 • DOI : 10.36106/gjra

Original Research Paper

Anatomy

A STUDY TO DETERMINE THE VARIATIONS IN ITS ORIGIN, COURSE AND TERMINATION OF THE HUMAN BRACHIAL ARTERY IN ADULT AND FOETUS

Hazarika Dipali Assistant Professor, Assam Medical College, Dibrugarh, Assam.

Baro Baneswar Associate Professor, Diphu Medical College, Diphu, Karbi Anglong, Assam.

Rabha Gunamani* Assistant Professor, Diphu Medical College, Diphu, Karbi Anglong, Assam.
*Corresponding Author

ABSTRACT

Background: The brachial artery provides the main arterial supply to the arm. Variations in the branching pattern of the major arterial trunks have been reported in foetal and adult human limbs. Knowledge of such variations has got clinical importance especially in the field of orthopedic, vascular and plastic surgeries. **Method:** The study was conducted on 100 numbers of upper limb of both male and female belonging to different age group in Department of Anatomy, Assam Medical College and Hospital, Dibrugarh. **Results:** In the present study, normal course of the brachial artery in foetus was found in 90.625% and 93.75% and variations were found in 6.25% and 6.25% specimens;in adult, it was found in 90.625% and 93.75% and. variations were found in 6.25% and 6.25% specimens in the right and left limb respectively. Normal termination of the brachial artery in foetus was found in 90.625% and 96.875% and variations were found in 3.125% and 6.254% in the right limb and 3.125% and 3.125% in the left limb in1cm and 2cm below the intercondyler line respectively. **Conclusions:** Knowledge of the anatomy of brachial artery for effective and fruitful management of arterial implication from primary level of general practitioners, among the Anatomists, Surgeons.

KEYWORDS : Brachial artery, Radial artery, Ulnar artery, Variation of artery

INTRODUCTION

The brachial artery provides the main arterial supply to the arm and is the continuation of the axillary artery. It begins at the inferior (distal) border of the teres major and ends in the cubital fossa opposite the neck of the radius under cover of the bicipital aponeurosis, where it divides into the radial and ulnar arteries[1]. At first brachial artery is medial to the humerus, but gradually spirals anterior to it until it lies midway between the humeral epicondyles. Its pulsation can be felt throughout[2]. At the cubital fossa, it passes lateral to median nerve and medial to the tendon of biceps brachii to divide into a radial and ulnar artery. In 25% of the individuals, brachial artery variations are common, according to the Compendium of Human Anatomic Variation[3]. Variations in the branching pattern of the major arterial trunks have been reported with an incidence of up to 20% in human adult limbs and they have been the subject of much controversy since the beginning of the nineteenth century[4]. High up division of the brachial artery can also be explained on the basis of observations made by Arey in 1957 where he highlighted that, there may be persistence of vessels which normally obliterate and disappearance or failure of development of vessels which normally persist[5]. Knowledge of such variations has got clinical importance especially in the field of orthopedic, vascular and plastic surgeries[6].

MATERIALS AND METHODS

The present study on human brachial artery has been carried out in the Department of Anatomy, Assam Medical College and Hospital, Dibrugarh during the period from 1st July, 2015 to 30th June, 2016. The present study was conducted on 50 cadavers which consist of 100 numbers of upper limb of both male and female belonging to different age group. No specific criteria have been put on selection of specimens. Both foetus and adult cadavers coming to the department of anatomy are included. The brachial arteries along with its branches, origin, course and termination are studied on the cadavers during dissection for undergraduate students. Because of shortage of cadavers an attempt is made to dissect out few stillborn foetuses (28-42 weeks) from Obstetrics and Gynaecology Department and from the post-mortem fresh cadavers. The adult cadavers were received from the different clinical department of Assam Medical College and Hospital.

After fulfilment of all official formalities the foetuses are received in the morgue of the anatomy department. The particulars of cadavers are recorded and the cadavers are preserved in the morgue with the preservatives as follows like Formalin (1-1.5 litre), Glycerine (.5 -1 litre), Methylated Spirit (1-1.5 litre),Potassium carbonate (200-250 ml), water (3-5 litre) depending on the weight of the cadavers.

Procedure:

The foetus is laid on the table in supine position, under sufficient light in a well ventilated room. In order to have a clear site for dissection the blood in the vessels is drained by flushing the vessels by normal saline using gravitational method. 10% solution of formalin is injected to the cadaver in order to preserve it for further dissection. The arm is abducted and the dissection is carried out on the axilla.

The Following Incisions Are Made On Skin Through The Deep Fascia On The Arm:

(1)Along the border of bicipital aponeurosis
(2)A longitudinal incision along the middle line of biceps.
(3)A transverse incision on the front of the elbow between the two epicondyles. The skin is reflected on either side of the longitudinal incision and the deep fascia is removed down the anterior surface of the arm as far as the elbow. The brachial artery is dissected out. It is traced proximally to continuity with axillary artery at the lower border of teres major muscle and distally to its termination in the cubital fossa. Now the brachial artery is examined for any variation and abnormalities. For better view, the brachial artery is painted with fabric colour (red).Then, photographs are taken of the dissected brachial arteries.

RESULTS AND OBSERVATIONS

In the present study, a total of 100 (one hundred) upper limbs of 50 cadavers of both sexes were studied. Out of these 100 Specimens, 64 limbs were of foetus and 36 limbs are adult.

Right Side Brachial Artery Of Foetus:

Origin: It is found that the origin of brachial artery occurs from lower border of teres major muscle and all are single in origin. No accessory or aberrant artery is seen.

Course: In majority of cases the brachial artery is found to be normal in its course and termination. The median nerve is found to run parallel to brachial artery throughout its length in two cases (Figure 1).

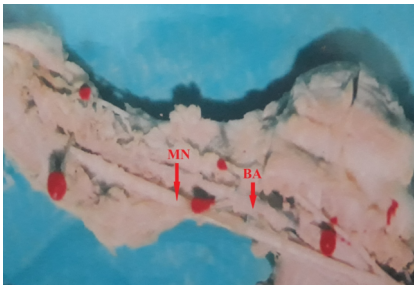

Figure 1: Brachial Artery Parallel To Median Nerve (ba=brachial Artery, mn=median Nerve)

In other cases, it lies lateral to the median nerve. In the cubital fossa, opposite the neck of the radius, it is divided into three terminal branches i.e ulnar, redial and redial recurrent artery, out of 32 right limbs of foetus limbs show three variations in its course and in termination (Figure 2).

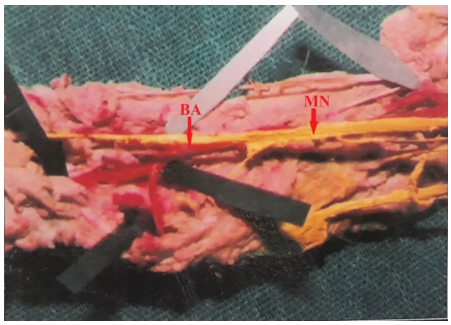

Figure 2: In The Cubital Fossa, Brachial Artery Divides Into 3 Branches-radial, Ulnar And Radial Recurrent Artery(BA=Brachial artery,MN=Median Nerve)

Table1 Showing numbers Of Normal And Variation In Course Of Brachial Artery In Foetus (32 Number Of Cadavers)

	RIGHT			LEFT		
	ARTERY	NO.	(%)	ARTERY	NO.	(%)
Normal	Brachial Artery	29	90.625	Brachial Artery	30	93.75
Variation	Brachial Artery Parallel To Median Nerve	2	6.25	Brachial Artery Parallel To Median Nerve	2	6.25

- **Variations shown by brachial artery in relation to Median Nerve:** Normally the artery passes medial to the median nerve after it origin from the third part of axillary below the lower border of the tires major in the middle third of the arm the brachial artery crosses deep to median nerve. In the present study, 4 numbers of the cases the brachial artery runs parallel to the median nerve in two still born foetuses.

Termination: It is found that the Brachial artery terminates in the cubital fossa at a distance of 2.0 cm below the intercondylar line into the branches i.e. radial, ulnar and radial recurrent artery, out of the 32 limbs observed of two limbs show variations in its termination of brachial artery (Figure 3 and Figure 4)



Figure 3: In The Cubital Fossa ,1cm Above The Intercondylar Line The Brachial Artery Divided Into Radial And Ulnar Artery (BA=Brachial artery,MN=Median Nerve)

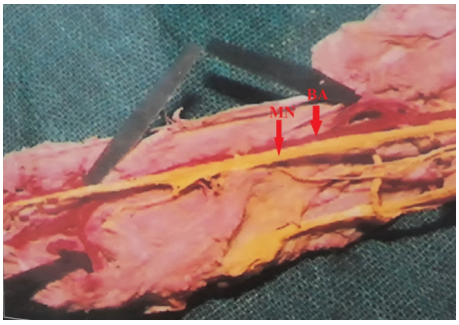

Figure 4: In The Cubital Fossa ,2 Cm Below The Intercondylar Line The Brachial Artery Divided Into 3 Branches- Radial, Ulnar, Radial Recurrent Artery (BA=Brachial artery,MN=Median Nerve)

Table – 2 Showing Numbers Of Normal And Variation Of Brachial Artery Termination In Foetus Cadavers (32 Number Of Cadavers)

RIGHT SIDE BRACHIAL ARTERY		LEFT SIDE BRACHIAL ARTERY	
NO.	(%)	NO.	(%)
Normal:Point of termination of brachial artery 1.5 cm belowintercondylar line into radial ulnar artery			
29	90.625	31	96.875
Variations: Point of termination of brachial artery 1.0 cm above the intercondylar line radial ulnar artery			
2	6.25	1	3.125
Variations: Point of termination of brachial artery 2.0 cm below the intercondylar line terminate in to radial, ulnar and radial recurrent.			
2	6.250	1	3.125

Left Brachial Artery of foetus:

Origin: It is found that the origin of brachial artery occur lower border of teres major muscle. All are single in origin. No accessory and aberrant artery is seen.

Course and Termination: In majority of cases the brachial artery is found to be normal in its course termination. The median nerve is found to run paralleled to the brachial artery throughout its length in two cases out of 32 limbs (Figure 5 and 6).

In other cases, it lies laterally to the medial nerve. In the cubital fossa opposite the neck of the radius, it is divided into two terminal branches i.e. ulnar and radial.

It is found that the brachial artery terminates in the cubital fossa at a distance of 2.0 cm below the intercondylar line into 3 braches i.e. radial, ulnar and radial recurrent arteries. It is found in one limb out of the 32 left limbs observed .

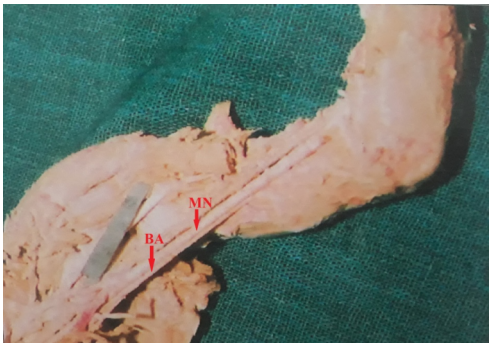

Figure 5: Brachial Artery Parallel To Median Nerve (BA=Brachial artery,MN=Median Nerve)

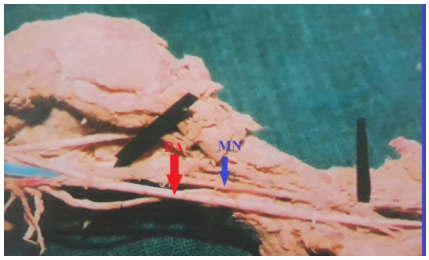

Figure 6: Brachial Artery Parallel To Median Nerve (BA=Brachial artery,MN=Median Nerve)

Right Side Brachial Artery of adults:

Origin: In all cases occurs at the distal border of teres major muscle. All are single in origin. No accessory or aberrant artery is present.

Course and Termination: In majority of cases the brachial artery is found to be normal in its course and termination. During the dissection of the case of the present study, variation is observed in the origin of radial artery in the right upper limb of an adult male cadaver. The radial artery which is a terminal branch of brachial artery takes origin in this limb from the 3rd part of axillary artery from its ventral surface. It runs on the medial side of median nerve and medial to biceps muscle. The radial artery crosses the median nerve anteriorly in the upper third of the arm, from medial to lateral side. Then it follows its normal course in the forearm. The brachial artery lies posterior to median nerve. At the level of middle third of the arm it crosses the radial artery from lateral to medial side (Figure 7).

Figure 7: High Origin Of The Radial Artery From The Axillary Artery And Superficially Cross The Median Nerve(AA=Axillaryartery,BA=Brachial artery, RA=Radial artery ,MN=Median Nerve)

It is found that the termination of brachial artery occurs in the cubital fossa at a distance of 2.0 cm below the intercondylar line into two branches i.e. ulnar and anterior ulnar recurrent artery.

In the right limb of an adult male cadaver the radial artery was arising from the 3rd part of the axillary artery from its anterior surface, while on the left side it was seen to be normal.

Table-3 Numbers of Normal And Variation In Course Of Brachial Artery And Its Terminal Branches In Adult (18 Numbers Of Cadavers)

	RIGHT ARTERY	NO.	(%)	LEFT ARTERY	NO.	(%)
Normal	Brachial Artery	16	88.8	Brachial Artery	15	80.2
Variation	High Origin of Radial artery	1	5.6	High Origin of Radial artery	1	5.6

*Superior ulnar collateral artery found to be normal in both side and Inferior ulnar collateral artery found to be absent in 1 (one) number case in both left and right side.

Table 4 Numbers of Normal And Variation Of Brachial Artery Termination In Adults Cadavers (18 Number Of Cadavers)

RIGHT SIDE BRACHIAL ARTERY		LEFT SIDE BRACHIAL ARTERY	
NO.	(%)	NO.	(%)
Normal:Point of termination of brachial artery into radial and ulnar artery			
17	94.40	17	94.40
Variations:Point of termination of brachial artery into ulnar and anterior ulnar recurrent artery			
1	5.60	1	5.60

Left Side Brachial Artery Of Adults:

Origin: In all cases occurs at the distal border of teres major muscle. All are single in origin. No accessory or aberrant artery is present.

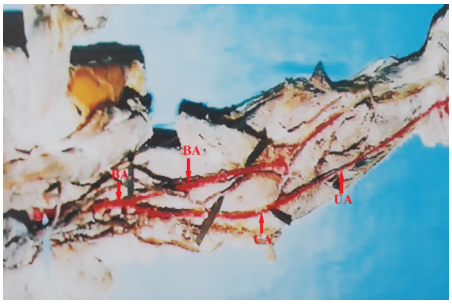

Figure 8: High Origin Of Ulnar Artery From The Brachial Artery Runs Superficially Throughout The Artery Runs In The Same Plane As The Superficial Veins (BA=Brachial artery, UA=Ulnar artery)

Course and Termination: In majority of cases the brachial artery is found to be normal in its course termination. During the dissection of a female cadaver a variation is observed in origin of ulnar artery in left upper limb. It arises from the brachial artery about 8 cm proximal to the elbow. It runs on the medial side of median nerve. In the arm it decends downwards superficial to the flexor muscles in the fore arm. It crossed the elbow superficial to the flexor digitorum superficialis muscle. At the middle of the arm, the median nerve crosses in front of the brachial artery from lateral to medial side. (Figure 8).

It is found that the termination brachial artery occurs in cubital fossa at distance of 2 cm below the intercondylar line into two branches i.e. radial and common interosseous arteries. In the left limb on an adult female cadaver, the ulnar artery was arising from the middle third of the brachial artery from its medial side, while in the right side it is found to be normal.

DISCUSSION

The results and observation of the present study has been discussed and compared. A humble attempt is made to study all the important features as far as possible.

Patnaik et al[7] observed the average length of this artery as 26.29 cm and its bifurcated into its terminal branches 2.99 cm distal to the intercondylar line of humerus. In the present study the length of brachial artery in fetuses range from 7.0 cm to 8.0 cm and its terminal branches 1.5 to 2.0 cm distal to the intercondylar line of humerus, in both upper limbs and in adult limbs from 24 to 22 cm. However, the average length cannot be considered as relevant because of different gestational age of the collected specimens .

Ceirvo A et al[8] reported a rare anomaly consisting of brachial artery agenesis or regenesis. The brachial artery was absent from its origin but reconstituted as a normal appearing vessel 3 cm above antecubital fossa. In the present study, in all the cases, the brachial artery arises from the lower border of teres

major muscle, all are single in origin. The present finding is supported by Gray's Anatomy[9], Sahana S.N[10] and other test book descriptions.

Adachi[11] also observed the superficial brachial artery may replace the main trunk or may be accompanied by equally important, less important or more important trunk running parallel and deep to median nerve in normal position. In the present study, the brachial artery is not crossing superfacial to median nerve. It is seen that brachial artery is running parallel medial to the median nerve lie laterally. This variation is found in 4 upper limbs of two still born fetuses and in both the fetuses it is bilateral.

Vare and Bansal[12] reported high division of brachial artery and also observed two brachial arteries, one superficial and the other deep brachial artery. Rossi Junior et al.[13] conducted a study on 56 cadavers in which they encountered a case of high division of the brachial artery, located in the upper 1/3rd in both arm, close to the axilla in a male cadaver (1.78%), placed 20 cm above the right cubital fossa and 21.5 cm from the left one. Incidence of a high division of the brachial artery is rare in general population, especially when it is bilateral. In present study in all the 100 upper limbs, no high division of the brachial artery is present.

Anson[14] mentioned that the superficial brachial artery arises from the axillary artery, it is continuous between the medial and lateral cords of the brachial plexus to the median nerve. It was superficial to the musculature of the arm under the brachial fascia in the elbow region normal in position and divided into radial and ulnar arteries. In the present study in all 100 upper limbs, it is seen that the brachial artery begins from the lower border of the teres major muscle. It runs downward in the elbow region, normal in position and divided into radial and ulnar artery.

Hofer and Hofer[15] described that the brachial artery passed between the two heads of pronator teres instead of dividing above it. In all the 100 limbs cases, it is seen that the lateral border of the pronator teres forms the medial border of the cubital fossa. The medial nerve passes between the humeral and ulnar heads of pronator teres. The brachial artery is divided above the heads of pronator teres into radial artery and ulnar artery. The ulnar artery passes deep to the ulnar head of pronator which separates the ulnar artery from the median nerve.

Linell E.A[16] found the median nerve crossed deep to the brachial artery in both limbs of the same cadaver out of 34 limbs dissected but in our study in all cases the median nerve runs parallel to brachial artery.

Karlsson & Niechajev[17], De Garis & Swartley[18], Miller[19], Anson[14] observed high origin of radial arteries in 14.27% of individuals. It was recorded by them as 7.7% and 3% and 15% respectively .

Karlsson & Niechajev[17] observed high origin of ulnar artery in 1% and radial artery 10% of their cases of study. Fuss et al[20], Golan et al[21] also observed the high origin of the radial artery as a kind of persistent superficial artery. In the present study a high origin of radial arery from the 3rd of axillary artery is found is found in right upper limbs of a adult male cadaver and similarly in another case a high origin of ulnar artery 8 cm above the elbow arise from brachial artery is found in left upper limb of a female adult cadaver out of 100 upper limb dissected.

Sahana SN[10] mentioned that the brachial artery terminated in the usual position into three branches - the ulnar, the radial and the common interosseous artery. Patnaik VVG et al[22] conducted a study on 50 upper limbs and described a case of trifurcation of brachial artery where it divided into radial, ulnar and radial recurrent arteries instead of radial and ulnar arteries at the level of neck of radius in the cubital fossa in one upper limb accounting for 2%. Malcic-Gurbuz et al[23] observed a case of trifurcation of brachial artery that divided into radial, ulnar and superior ulnar collateral arteries high up in the arm. Bilodi AK[24] reported a case of trifurcation of brachial artery where it was dividing into radial, ulnar and common interroseous arteries. Shivanal U et al[25] found that trifurcation of brachial artery was observed in five among 50 specimens. In all the cases the brachial artery was terminating in the cubital fossa into radial, ulnar and radial recurrent arteries and this was accounting for 10% of variations. William's et al[26] also observed some variation of brachial artery.. In the present study, the brachial artery terminates into radial and common interosseous arteries left upper limb of an adult female and in another case the brachial artery terminates into ulnar and anterior ulnar recurrent artery in right upper limb of an adult. In the foetus, the brachial artery terminates 1.0 cm above the intercondylar line of humerus into two branches radial and ulnar arteries. In two limbs, it terminates 2.0 cm below the intercondylar line into radial, ulnar radial recurrent in right and left upper limbs.

CONCLUSION

The variation in the arterial pattern of the upper limb have been observed frequently, either in routine dissection or in clinical practice. It is not very uncommon to find out the variation in its course, relation, termination during routine anatomical dissection.

Various studies on the brachial artery had been carried out in different parts of the world. The purpose of this study was to find out the effectiveness and applicability of different types of variation in the management of arterial replacement. Once again we emphasize the need of knowledge of the anatomy of brachial artery for effective and fruitful management of arterial implication from primary level of general practitioners, among the Anatomists, Surgeons. The clinical implication of these variations are also highlighted in the diagnostic interventional and surgical significance of such a variation, diagnostically, it may disturb the evaluation of angiographic images. Interventionally accidental puncture of superficially placed arteries may occur while attempting venipuncture. Surgically it is vulnerable in both orthopaedic and plastic surgery operations. All significant improvement of variations in the number and course of the arteries of the upper limb have clinical and surgical significance, normally the pulsation of the brachial artery is felt or auscultated in front of the elbow, to record the blood pressure. Due to the diagnostically above said variation B.P cannot be recorded in usual way.

REFERENCES:

(1) Keith LM, Anne MR (2007). Essencial Clinical Anatomy (3rd Edn) Lippincott Williams & Wilkins pp: 439-440.

(2) Williams, P.L.; Bannister, L.H., Berry, M.M; Collins, P; Dyson, M; Dussek, J.E; Ferguson, M.W.J. (1999). Gray's Anatomy In: Arteries of the limbs & Cardiovascular System. Gabella, G. Edr. 38th Edn. Churchill Livingstone, New York: pp 1537-44.

(3) Bergman RA, Thompson SA, Afifi AK, Saadeh FA (1988). Compendium of Human Anatomic Variation. Baltimore: Urbanand Schwarzenberg;.

(4) Rodriguez-Niedenfuhr M, Burton GJ, Deu J, Sanudo JR.(2001). Development of the arterial pattern in the upper limb of staged human embryos: normal development and anatomic variations. J Anat.; 199: 407–417.

(5) Arey LB.(1988). Developmental Anatomy. 6th Ed. Philadelphia, W.B. Saunders; 375–377.

(6) Gonzalez-Compta X (1991). Origin of the radial artery from the axillary artery and associated hand vascular anomalies. J Hand Surg Am.; 16: 293–296.

(7) Patnaik, V.V.G.; Kalsey, G; Singla Rajan, K. (2001):Bifurcation of axillary artery in its 3rd part – A Case Report. Journal of the Anatomical Society of India. 50(2): 166-169.

(8) Ciervo A.,Kahn M.,Pangilinan A.J., and Dardik H(2001):Absence of the brachial artery: Report of a rare human variation and review of upper extremity arterial anomalies ,J Vasc Surg 2001;33:191-4.

(9) Gray's Anatomy(1999): In artery of a limband cardiovascular system,38th Edition, New York,Page1537-44.

(10) Sahana SN(1962): Human Anatomy(Descriptive and Applied),Vol.1,Calcutta, pp-706.
(11) Adachi, B: Das(1928): Arterien system des japaner, Kyoto Vol 1. p 229-54.
(12) Vare, A.M. & Bansal, P.C. (1969): A case of anomalous brachial artery & other associated vascular anomalies in a single upper limb. Journal of Anatomical Society of India. 18(2): 50-53.
(13) Junior R, Esteves, Simoes JS, Fernandes GJM. (2011). Bilateral high division of the brachial artery in one human male cadaver: a case report. J Morphol Sci.;28(3):204-7.
(14) Anson, B.J(1966): Morris 'Human Anatomy In: The Cardiovascular system-Arteries & Veins. Thomas, M. Edr. McGraw Hill Book C. New York: pp 708-724.
(15) Hofer, K. & Hofer, G. (1910): Ueberden Verlauf der arteria brachialis mit dem nervus medianus zwischen den beiden kopfen des musculus pronator teres. Anatomical Anzeles. 36: p. 510.
(16) Linell, E.A. (1921): The distribution of the nerves in upper limb with reference to variability & their clinical significance. Journal of Anatomy. 55: p. 79.
(17) Karlsson, S. & Niechajev I.A. (1982): Arterial anatomy of the upper extremity. Acta Radiological Diagnosis 23: pp. 115-121.
(18) De Garis, C.F. & Swartley, W.B. (1928): The axillary artery in white & negro stocks. American Journal of Anatomy 41: pp 353-97.
(19) Miller, R.A. (1939): Observations upon the arrangement of axillary artery & brachial plexus. American Journal of Anatomy. 64: 143-163.
(20) Fuss, F.K; Matula, C.H.W. & Tschabhcher, M. (1985): Die arteria brachialis superficialis Anatomical Anzeles. 160: 28594.
(21) Golan, J; Kaus, M; & Szware, P. (1994): High Origin of the radial & ulnar arteries in human. Folia Morphologica. 53: 3748.
(22) Patnaik VVG, Kalsey G, Rajan KS. (2002). Branching pattern of brachial artery - a morphological study. J Anat Soc India.;51:176-86.
(23) Malcic GJ, Gurunluogl R, Ozdogmus O, Yalin, Aymelek A.(2002). Unique case of trifurcation of the brachial artery: its clinical significance. Clinic Anat. May;15(3):224-7.
(24) Bilodi AK, Sanikop MB.(2004). Variations in termination of brachial artery - a case report. Kathmandu Univ Med J.;2(1):49-51.
(25) Shivanal Uma & Gowda M. S. Trinesh(2015). International Journal of Research in Medical Sciences ,June 2015 ,Vol 3 ,Issue 6, P- 1392.
(26) Williams, P.L.; Bannister, L.H., Berry, M.M; Collins, P; Dyson, M; Dussek, J.E; Ferguson, M.W.J.: (1999). Gray's Anatomy In: Arteries of the limbs & Cardiovascular System. Gabella, G. Edr. 38th Edn. Churchill Livingstone, New York: pp 1537-44.