

CU-SIL DENTURES- AN ALTERNATIVE TREATMENT OPTION FOR MANAGEMENT OF FEW REMAINING NATURAL TEETH

Lavanya MK	BDS Student, SRM Dental College, Ramapuram, Chennai
Dr. Padmashini Gnanam*	Senior Lecturer, Prosthodontics, SRM Dental College, Ramapuram, Chennai *Corresponding Author
Dr. B. Muthukumar	Head of the Department, Prosthodontics, SRM Dental College, Ramapuram, Chennai

ABSTRACT

The main responsibility of the dentist is to rehabilitate the patient whilst preserving the remaining natural dentition. It has long been proven that the presence of teeth helps to preserve the alveolar ridge in its place. The current trend in prosthodontics is to rehabilitate the patient using a conventional removable partial denture or to remove the natural teeth and replace it with a complete denture. A conventional RPD will have deleterious effects on the periodontium of the natural teeth. Complete dentures will lead to alveolar bone loss and loss of proprioception. Transitional dentures are like a bridge which help the patient to transition from a dentulous state to an edentulous state. They will have all the benefits of preserving natural teeth while eliminating the ill effects of a complete denture. Cu-sil denture is a type of transitional denture which involves making holes in a complete denture through which the natural teeth emerge. This case report discusses a simple and cost-effective method of processing a Cu-sil denture.

KEYWORDS : Cu-sil denture, partially edentulous arch, soft liners, transitional denture

INTRODUCTION:

De Van's principle states that "Perpetual preservation of what remains of the human masticatory apparatus is important rather than meticulous replacement of what is lost." The main concern in prosthetic rehabilitation is preservation of natural remaining artificial teeth. Even few remaining teeth present in the oral cavity can help the patient by providing support to the prosthesis, aiding in proprioception and in preserving the alveolar ridge.

Studies prove that alveolar bone loss occurs when the teeth are extracted followed by rehabilitation with complete dentures.¹ Also, the psychological trauma associated with loss of teeth coupled with problems like reduced stability, and retention, compromised masticatory function, unesthetic appearance make the transition from a dentulous state to edentulous state very difficult for the patient.^{2,3}

In such cases, alternative treatment options can be considered which retain the few remaining natural teeth. These include overdentures and transitional dentures. Immediate dentures are another option wherein extraction and denture placement are done on the same day. However, there are obstacles associated with each of these treatment modalities. Over dentures may not be a favourable option because of the need for endodontic treatment, poor position of the remaining teeth, a greater number of patient visits and increased cost of treatment.⁴

Immediate dentures are not possible if the patient is unwilling to extract the teeth and the associated problems related to loss of natural teeth. Transitional dentures are a great technique which preserves the natural teeth as well as an easy and cost-effective option. Cu-sil denture is a type of transitional denture. It is basically a complete denture with holes in them which allows the natural teeth to emerge through.

This article presents a case report of prosthetic rehabilitation using a Cu-sil denture.

CASE REPORT:

A 57-year-old male patient reported to the Department of Prosthodontics at SRM dental college, Ramapuram, Chennai, Tamil Nadu, India. His chief complaint was ill fitting and loose maxillary denture.

On intra oral examination the patient had a Kennedy class 1 modification 1 edentulous space in maxilla with presence of only 13 and 24 (Fig. 1) and Kennedy's class 2 edentulous space in mandibular arch with missing 34, 35, 36, 45, 46, 47 and 48. Patient was already a denture wearer with a satisfactory lower denture but poor retention and esthetics in upper denture. On examination of individual teeth, 13 and 24 had gingival recession in them and the mandibular teeth were supra-erupted.

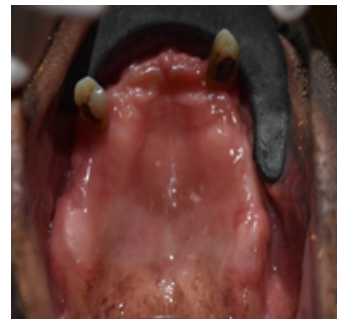

Figure 1 – Pre-operative maxillary arch with presence of 13 and 24

Treatment options were discussed with the patient. He was not willing for any extractions or endodontic treatment. Considering the above conditions, a treatment plan was formulated which consisted of a Cu-sil denture in the maxillary arch. The treatment procedure was explained to the patient.

TREATMENT PROCEDURE:

In the first appointment, primary impressions of the maxilla and mandible were made using irreversible hydrocolloid. [Zelgan Plus alginate impression material, Dentsply]. This was followed by custom tray fabrication for maxillary cast using autopolymerizing acrylic resin. [DPI RR Cold Cure, DPI India]

During the second appointment, border molding was done in the maxilla using green stick compound [DPI pinnacle tracing sticks, DPI India] and the final impression was made with light body impression material (Fig. 2). [Aquasil, Dentsply Sirona, USA]. Master cast was prepared and occlusal rims were fabricated.

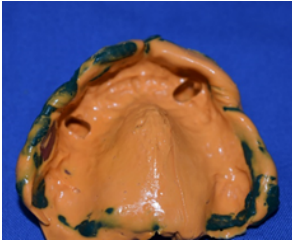


Figure 2 – Secondary impression of maxillary arch

At the third appointment, Vertical and centric jaw relation were recorded and articulated in a mean value articulator. Teeth setting was done with the 13 and 24 in place. [Acryrock, Ruthanium, Confident India]

At the wax try-in appointment, the occlusion and dental esthetics were examined After obtaining the patient's consent, the trial denture was waxed up for processing.

Two gasket rings made of silicone rubber were selected to a diameter corresponding to the diameter of a canine and premolar (Fig. 3). The rings were altered to fit snugly and passively on the cervical margin of 13 and 24 (Fig. 4, 5). There is a risk of extreme thinning of the denture base in the final denture in 13 and 24 region. Hence, the buccal area above 13 and 24 was reinforced by placing a small piece of 21 gauge wire. The rings were secured in position by waxing it along with the denture base (Fig. 6, 7). Maxillary waxed up denture was flasks using conventional flask and clamp with type 3 gypsum. [Kalstone, Kalabhai, India].



Figure 3 – Silicone gaskets corresponding to diameter of canine and premolar

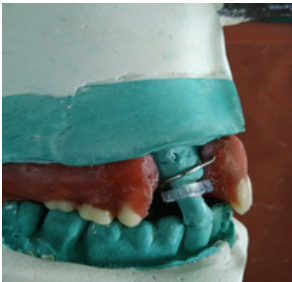

Figure 4 – Silicone ring fit snugly around the canine and reinforced with 21 gauge wire

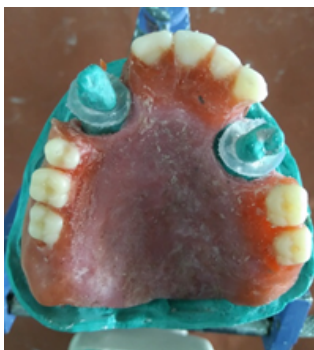

Figure 5 – Silicone rings in place

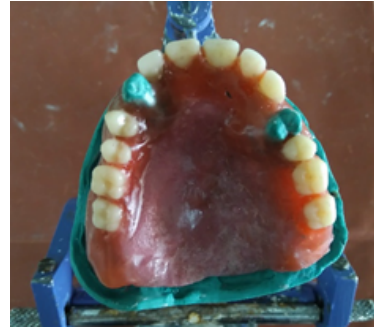

Figure 6 – Waxed up denture with the silicone rings

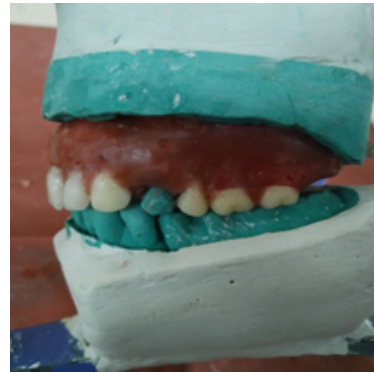

Figure 7 - Waxed up denture with the silicone rings

Dewaxing was done and any residual wax was manually removed. A thin layer of separating medium [Cold Mold Seal, DPI India] was carefully painted over the stone taking care not to touch the silicone rings. Polymerization was done using conventional heat curing technique. Once the denture was processed, the flask was bench cooled for 30 minutes. Deflasking was done to retrieve the denture using hammer and plaster knife. The finished and polished denture (Fig. 8) was inserted into the patient's mouth. The silicone ring was adjusted chair side to allow passive seating on the tooth (Fig. 9). Review showed that the patient was comfortable in using the denture and his previous problem of retention was also solved.

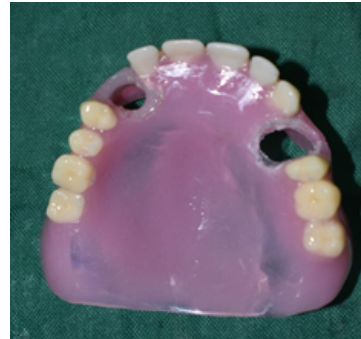

Figure 8 – Processed denture with silicone ring

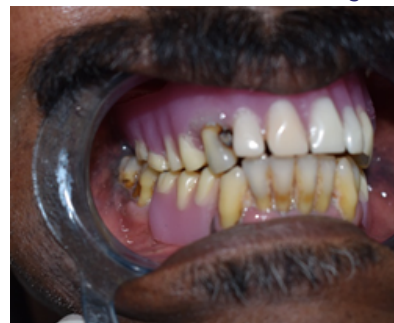

Figure 9 – Post operative intra oral view with denture

DISCUSSION:

Cu-sil dentures are a good treatment option in patients who have isolated, periodontally compromised teeth. These dentures are designed to preserve the remaining natural teeth and thus the alveolar bone. They have a positive effect on retention and stability of denture. The silicone fits snugly around the natural teeth completing the peripheral seal. It also acts like a cushion, distributing forces more evenly. Also, it gives patients a psychological satisfaction of retaining their natural teeth and not having to endure any extractions. These natural teeth help in preservation of alveolar bone and aid in proprioception. The main advantage of a Cu-sil denture is that if the patient loses his natural teeth in the future, the denture can be modified and adjusted to work as a complete denture.⁵ The denture is easy to fabricate. The resultant prosthesis is very easy to remove and insert without any hindrance. Elimination of clasps makes the denture esthetic and does not injure the soft tissues. However, the longevity of the silicone rings is short lived and may need to be replaced. The silicone ring can also accumulate plaque and calculus if hygiene is not maintained properly.⁶

CONCLUSION:

Cu-sil denture serves as a viable treatment alternative for patient with very few remaining teeth. An elastic gasket seals itself around the cervical part of each tooth, thereby providing a stable and healthy fit. It promotes healthy stimulation to maintain alveolar bone. Retention is improved, vertical dimension and proprioception are maintained.

REFERENCES:

1. Crum RJ, Rooney GE., Jr Alveolar bone loss in overdentures – A 5 year study. *J Prosthet Dent.* 1978;40:610–3.
2. Bolender Z. 12th ed. St. Louis, MO: Mosby; 2013. *Prosthodontic Treatment for Edentulous Patients*; pp. 6–23. (160-76). 190-208.
3. Zarb GA, Bolender CL, Hickey JC, Carlsson GE. 10th ed. St. Louis, MO: Mosby; 1997. *Boucher's Prosthodontic Treatment For edentulous Patients*; pp. 71–99.
4. Khandelwal M, Punia V. Saving one is better than none: Technique for cu-sil like denture – A case report. 2011;03(01):41–5.
5. Gagandeep K, Sangeetha G, Deepika S. Cusil denture: A novel conservative approach- A case report. *Unique J Med Dent Sci.* 2013;01(02):56–8.
6. Jain JK, Prabhu CR, Zahrane MA, Esawy MS, Ajagannavar SL, Pal KS. Cu-sil dentures - a novel approach to conserve few remaining teeth: Case reports. *J Int Oral Health.* 2015;7(8):138–140.