

SURGICAL ANATOMY OF EXTERNAL LARYNGEAL NERVE IN RELATION TO THYROID SURGERY : OUR EXPERIENCE

Dr Brajendra Baser

Professor & HOD (Former) SAIMS Medical College, Indore Director, Akash Hospital Indore

Dr Vishal Rattan Munjal

Prof & HOD SAIMS Medical College, Indore

Dr Manya Thakur Roy*

Assistant Professor ENT, Pt JNM Medical College Raipur CG, India
*Corresponding Author

ABSTRACT

Objectives - To Study Surgical Anatomy of External Laryngeal Nerve and its variation in relation to Thyroid Surgery.

Methodology – A Non-randomized prospective Study was conducted in patients undergoing Thyroid surgery in SAIMS, Indore. The ELN was identified and preserved intra operatively. The function of Nerve was assessed and documented by pre op & post op EGG and Video laryngoscopy.

Results- Intraoperative identification of ELN leads to almost negligible changes in voice quality. A permanent drop in Fundamental Frequency (Fo) was seen in significant number of patients when the nerve was not identified during surgery.

Conclusion - Today in the era of 21st century where we are reaching new horizons, efforts to further refine thyroid surgery continues. Good range of voice is not only important for Singers but for Teachers, Politicians, RJ, public speakers etc too. An attempt to preserve External Laryngeal Nerve should be done to preserve Voice Quality as an integral part of surgery.

KEYWORDS : External Laryngeal Nerve, Voice Quality, Thyroid Surgery, Superior Thyroid Pedicle, Fundamental Frequency

INTRODUCTION

For many years surgeons have ligated the superior pole of the thyroid gland near the entrance of the vessels aiming to avoid injury to External Laryngeal Nerve. There have been numerous modifications in the techniques of Thyroid surgeries with better understanding of the anatomy and the physiology of the thyroid gland. The clinical significance of superior laryngeal nerve (SLN) has been clearly overshadowed by emphasis on recurrent laryngeal nerve. The principles of head and neck surgery are based on identification & preservation as opposed to avoidance of important structures. Paralysis of the SLN can be significant to those whose career depends heavily on full range of voice e.g singers teachers, hawkers, telemarketing professionals to name a few. Damage to the nerve can manifest as paralysis to the cricothyroid muscle. Mostly it is asymptomatic, but clinical symptoms of unilateral injury may include hoarse monotonous and breathy voice. Bilateral injury will have same changes with easy fatigue of voice. The clinician may find signs of bowing and inferior displacement of affected cord on Laryngoscopy.¹ The present study is a nonrandomized prospective study which focuses primarily on intra operative identification and preservation of EBSLN during thyroid surgery in 90 patients.

MATERIAL AND METHODS

This study was non randomized prospective study conducted at Department of ORL & HNS, Tertiary Care Center India. The Subjects were FNAC proven euthyroid patients undergoing thyroid surgery in ENT Department of SAIMS from July 2011 to July 2014. The patients were pre operatively assessed to exclude vocal cord palsy by Video Laryngoscopy & Voice Analysis. The Exclusion criteria was Patients presenting with history of recent hoarseness or who have received neck radiation and with history of previous neck surgery, anaplastic thyroid carcinoma, Grave's disease, completion thyroidectomy and abnormal vocal cord function pre-operatively. Initially cadaver dissection was done in Dept of Anatomy and the course of the nerve and position was studied Intra operatively (as shown in Fig 1 -9). An attempt to identify and preserve External Laryngeal Nerve was made during surgery by individual ligation and skeletonization of superior pole vessels in all patients

subjected to thyroid surgery. Intra-operative relationship between the Superior thyroid artery and the External laryngeal nerve was assessed and classified according to Cernea's Classification. The Voice assessment was done both pre operatively and after the surgery by Video Laryngoscopy and EGG (Dr Speech software). The Fundamental frequency of all patients was assessed and compared and documented before & after the surgery by Voice Analysis (EGG).

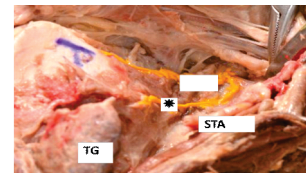


FIG 1 Neck dissection (left) picture showing Superior Laryngeal Nerve along with External Laryngeal Nerve* and Internal Branch of Superior Laryngeal Nerve IBSL, Upper Pole of Thyroid Gland TG, Superior Thyroid Artery STA

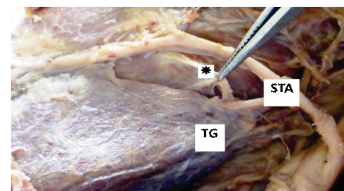


FIG 2 Neck dissection (left) picture showing EBSLN*, Upper Pole of Thyroid Gland TG, Upper Pole of Thyroid Gland TG, Superior Thyroid Artery STA

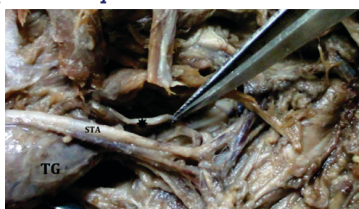


FIG 3 Neck dissection (left) picture showing EBSLN*, Upper Pole of Thyroid Gland TG, Superior Thyroid Artery STA

SURGICAL TECHNIQUE

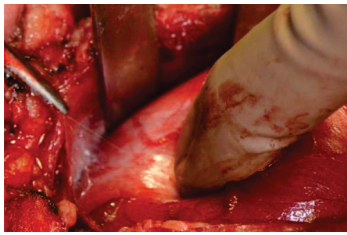


FIG 4 Keeping close to capsule of gland in the avascular cricothyroid space of Reeve an attempt to identify the nerve by dissecting laterally and at the junction of superior thyroid pole is made. Capsular dissection, skeletonization and individual ligation of superior pole vessels is carried out to identify and preserve External Laryngeal Nerve. The superior vascular pedicle is clamped and sectioned after identification of the superior laryngeal nerve.²

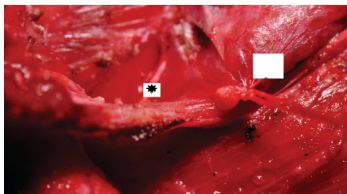


FIG 5 Intra Operative picture showing EBSLN* and Thyroid Gland with Type I Variation

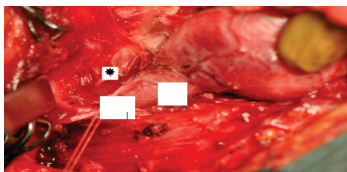


FIG 6 Intra Operative picture of EBSLN*, Thyroid Gland & Superior Thyroid Artery showing Type II variation.

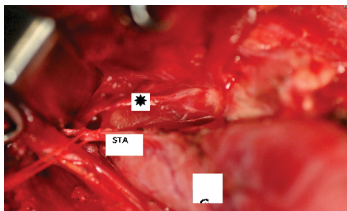


FIG 7 Intra Operative picture showing EBSLN* , Thyroid Gland & Superior Thyroid Artery with Type II Variation.

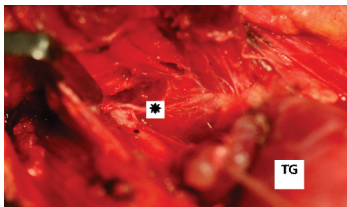


FIG 8 Intra Operative picture showing EBSLN, Superior Thyroid Artery and Thyroid Gland with Type III Variation.

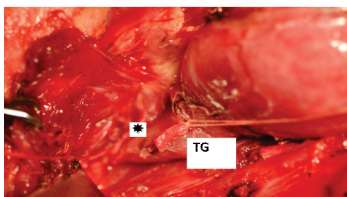


FIG 9 Intra Operative picture showing EBSLN * & Thyroid Gland with Type IV variation

RESULTS

Total number of patients who underwent thyroidectomy was 90, Out Of those 22 were males and 68 were females. The Gender Distribution ratio in this study among Male : Female is 1:3. The youngest person in the study group is 19 years old, the oldest person is 68 years old and the mean age is 43.5 years as shown in Table 1 below

Table 1 Showing Age wise Distribution

AGE(Yrs)	PATIENTS
10-20	5
21-30	27
31-40	22
41-50	21
51-60	9
61-70	6

Table 2 Showing Type of Nerve according to position with reference to Cernea's Classification.

TYPES	VARIATIONS OF THE NERVE	Cernea et al	Present Study
TYPE I	CROSSES STA > 1 CM ABOVE UPPER POLE	60%	22.01%
TYPE IIa	CROSSES STA < 1 CM ABOVE UPPER POLE	17%	49.5%
TYPE IIb	CROSSES STA UNDER COVER OF UPPER POLE	20.2%	28.4%

On assessment of Voice by EGG , In 82 patients there was almost negligible changes in Pre Op & Post Op (F₀) of voice. In 8 Patients Permanent Drop of F₀ patients was seen in 5 cases where Nerve could not be identified and in 3 patients with Type 2 B variation. In present study the ELN injury was 6.8%. In our study Cernea Type 2a was the most common position followed by Type 2b the Type 1. Several other authors also advocate Cernea Type 2a as the most common position found intraoperatively as mentioned below in Table 3.

STUDY	TYPE	PERCENTAGE
PRESENT STUDY	TYPE 2A	49.50 %
AINA & HASSAN ET ALL3	TYPE 2A	56%
SEON-BAE & HYE-YOON ET ALL4	TYPE 2A	58%
ANAND MISHRA & HEMA5	TYPE 2A	53.84%

DISCUSSION

The external laryngeal nerve which is a branch of the superior laryngeal nerve, supplies the cricothyroid muscle is not routinely identified by surgeons during thyroidectomy, as it is a very fine nerve and its course is highly variable. Its injury results in loss of the high pitch of the voice and injury to the superior laryngeal nerve results in choking on swallowing food and liquids due to the epiglottic sensation being lost. In order to prevent injury to the nerve, surgeons routinely ligate the superior thyroid artery with its venae comitantes very close to the superior pole of the thyroid without actually identifying or tracing out the nerve course. According to Chosky and Nicholson the nerved can also be stretched and injured by a retractor or transected when the superior thyroid vessels are divided.⁶

CERNEA ET AL DESCRIBED THE CLASSIFICATION OF THE DIFFERENT TYPES OF ELNS AS FOLLOWS (FIG. 10):

Type 1: Nerve crossing the superior thyroid vessels 1 or more cm superior to the apex of the superior thyroid pole
 Type 2: Nerve crossing the superior thyroid vessels less than 1 cm superior or inferior to the apex of the superior thyroid pole
 Type 2a: Nerve less than 1 cm superior the apex of the superior thyroid pole, and Type 2b: Nerve inferior to the apex of the superior thyroid pole.

Type 2a and 2b nerves are considered to be the "nerves at an

increased risk¹¹ of iatrogenic lesion during a thyroidectomy, owing to their low-lying course^{7,8}

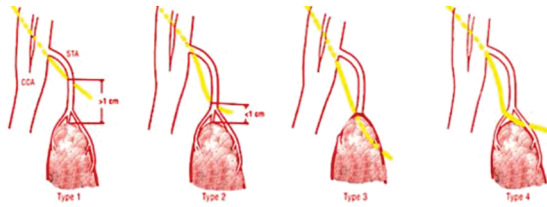


Fig. 10 Showing Variation in course of External Laryngeal Nerve according to Cernea's classification.⁹

The incidence reported in the literatures of injury to EBSLN intraoperatively in thyroid surgery is not very well documented as that of the recurrent laryngeal nerve which has been reported to be from 0.3% to 56% earlier.¹⁰ In present study the ELN injury was 6.8%

In fact, Lennquist et al has described this nerve as the "neglected" nerve in thyroid gland surgery, despite the fact that injury to these nerves can also cause significant disability.¹¹

A full understanding of the anatomy of the superior laryngeal nerve and its branches is necessary for all the head and neck surgeons and could prepare the surgeon to reduce this risk of damage. Especially when the nerve has a variable course as per the Cernea's classification Type 2a and 2b injury can occur easily if not taken care. There are various studies which have suggested that nerve could be easily identified by giving few extra minutes, while dissecting the upper pole. According to Mishra AK et al nerves could be identified in 72 (92.31%) out of 78 patients in which superior pole was dissected during thyroidectomy.¹² Pagedar NA et al conducted a study in Canada on 178 patients undergoing thyroidectomy over a period of 4 years only 3 out of 178 nerves (1.7%) could not be identified using the routine technique.¹³ Aina EN et al conducted a study on the external laryngeal nerve in which total of 202 external laryngeal nerves were identified during thyroid surgery, which was 92.7%.¹⁴ In present study Out of 117 Nerves at risk 4 could not be identified (3.4%)

CONCLUSION

Today in the era where advancement in every field is taking place, efforts to further refine thyroid surgery continues. The voice quality is not only important for singers, speakers or Hawkers but for normal persons too. The aim of the study is not only to treat the disease but also try to improve quality of life after surgery. Injury to the ELN may result in transient loss of high pitched voice but often may lead to permanent change. Patients like Orators, Singers and Teachers who heavily depend on their voices may lose their livelihood.

It is possible to identify the external laryngeal nerve with little effort in almost all cases and as in larger number of patients position of nerve comes under high risk. For ELN preservation it is always advisable to identify and preserve it thus avoiding critical alterations in the voice quality. A permanent drop in fundamental frequency was seen in a significant number of patients in the cases where nerve was not identified during the surgery. Careful dissection & spending few extra minutes during surgery can render almost near normal voice quality for all the patients.

KEY HOME MESSAGE –

The author highly recommend Prevention of voice quality for all the patients undergoing Thyroid Surgery and sensitize surgeons about careful dissection and preservation of ELN in each and every case which is often ignored routinely by many surgeons. It is injustice on the surgeon's part to cause a voice change which could have easily been prevented by spending

another minute or two on dissection and identification of the nerve.

FUNDING: No funding sources

CONFLICT OF INTEREST: None declared

ETHICAL APPROVAL:

The study was approved by the institutional ethics committee

ACKNOWLEDGMENTS

We are thankful to the Dept of Anatomy SAIMS, Indore for helping us in Cadaver Dissection and studying the Anatomy of Nerve.

REFERENCES

1. E N. Aina And A.N. Hisham External Laryngeal Nerve In Thyroid Surgery: Recognition And Surgical Implications; Anz J. Surgery; Volume 71 ; 211-213; Nov-2001
2. Standing S, Berkovitz Bkb. Thyroid Gland. In: Standing S, Ellis H, Healey Jc, Johnson D, Williams A, Collins P Et Al (Eds) Gray's Anatomy, 39th Edition, London; Churchill Livingstone, 2005:560-564.
3. Georgina Magoma, Hassan Saidi- Relation Of The External Laryngeal Nerve To Superior Thyroid Artery In An African Population; Anatomy Journal Of Africa; 28-30; June 2013
4. Seong-Bae Hwang, Hye-Yoon Lee- The Anatomy Of The External Branch Of The Superior Laryngeal Nerve In Koreans; April 2012; 1-7
5. Anand Kumar Mishra, Hema Temadari- Indian Journal Of Medical Sciences; Volume 61; Jan-2007; 36
6. Choksy Sa, Nicholson Ml. 1996. Prevention Of Voice Change In Singers Undergoing Thyroidectomy By Using A Nerve Stimulator To Identify The External Laryngeal Nerve. Br J Surg 83:1131-1132.
7. Cernea Cr, Ferraz Ar, Nishio S, Dutra A Jr, Hojaij Fc, Dos Santos Lr. 1992b. Surgical Anatomy Of The External Branch Of The Superior Laryngeal Nerve. Head Neck 14:380-383.
8. Aina En, Hisham An. 2001b. External Laryngeal Nerve In Thyroid Surgery: Recognition And Surgical Implications. Aust Nz J Surg 71:212-214.
9. Cernea Cr, Ferraz Ar, Nishio S. Surgical Anatomy Of The External Branch Of The Superior Laryngeal Nerve. Head Neck. 1992; 14(5):380-3.
10. Jansson S, Tisell Le, Hagne I, Sanner E, Stenborg R, Svensson P Partial Superior Laryngeal Nerve (Sln) Lesions Before And After Thyroid Surgery. World J Surg 1988; 12: 521-7
11. Friedman M, Toriumi Dm. 1986. Functional Identification Of The External Laryngeal Nerve During Thyroidectomy. Laryngoscope 96:1291-1292
12. Mishra Ak, Temadari H, Singh N, Mishra Sk, Agarwal A. The External Laryngeal Nerve In Thyroid Surgery: The 'No More Neglected' Nerve. Indian J Med Sci. 2007; 61(1):3-8.
13. Nitin A, Pagedar Md, Jeremy L, Freeman Md. Frsc, "External Branch Of The Superior Laryngeal Nerve". Arch Otolaryngol Head Neck Surg. 2009; 135(4):360-2.
14. Aina En, Hisham An. External Laryngeal Nerve In Thyroid Surgery: Recognition And Surgical Implications. Anz J. Surg. 2001; 71:212-4