



SQUAMOUS CELL CARCINOMA OF TEMPORAL BONE: A RARE ENTITY

Dr. Mamta Verma

Senior Resident, Department of ENT, Autonomous State Medical College, Shahjahanpur

Dr. Tarun Kumar Chauhan*

Assistant Professor, Department of Radiodiagnosis, Shri Ram Murti Smarak Institute of Medical Sciences, Bareilly *Corresponding Author

ABSTRACT

Incidence of squamous cell carcinoma (SCC) of temporal bone is very less accounting as less than 6 cases per million per year which is 0.3% of all head and neck tumors. Five year disease specific survival is only 19% to 48% due to delayed diagnosis [1-3]. In this study we are reporting two cases of temporal bone carcinoma. Both cases were initially misdiagnosed as chronic otitis media with extensive cholesteatoma which later on found to be the SCC temporal bone. Both cases then underwent surgical resection with adequate margins to eliminate the disease.

KEYWORDS : Temporal bone carcinoma, head and neck cancers, lateral temporal bone resection, radiotherapy.

INTRODUCTION

Temporal bone carcinoma is rare in all head and neck cancers [1]. Squamous cell carcinoma of temporal bone is the most commonly occurring tumor. Other less frequently types are adenocarcinoma, adenocystic, carcinoma, mucoepidermoid, basal cell carcinoma, ceruminous carcinoma, and rhabdomyosarcoma. Associated risk factors include previous radiotherapy, CSOM or cholesteatoma within external auditory canal and middle ear [4,5]. Evidence has emerged to suggest human papilloma virus (HPV) can be linked to a subset of this disease group [6,7]. The survival rate at 5 years is 27% with a high operative mortality rate of 5% [8]. The long term prognosis of SCC temporal bone malignancies is correlated to the tumor stage, biology of the tumor and the initial treatment.

CASE 1

A 47 year old male patient was admitted with chief complaints of bilateral ear discharge since childhood which was insidious in onset, initially mucoid later mucopurulent, non foul smelling, blood stained, which was unresponsive to the medications, with no aggravating factor. It was also associated with decreased hearing since 2 years, earache (recurrent) and headache since 6 months. There was also history of mass in right ear since 1 month. It was a post operated case of Right Modified Radical Mastoidectomy at a local hospital in 2017. Biopsy was taken at the same time on suspicion which later proved the tumor as moderately differentiated SCC temporal bone.

On examination tragal cartilage prominence was absent. Pinna was protruding outwards. In postauricular region there was a postaural scar of previous surgery and mastoid region was erythematous, tender, with raised local temperature. In right external auditory canal a pink colored mass was seen, which was occluding whole of the canal, single, soft in consistency and having smooth appearance. On palpation it was non tender, sensitive to touch, probe could be passed all around and mass did not bleed on touch. Tuning fork tests showed Rinne test bilateral negative, Webers test lateralized to right, absolute bone conduction tests were reduced bilaterally. Facial nerve function was normal bilaterally. On neck examination no palpable lymph nodes were there and other cranial nerve examination was normal. Audiometric evaluation showed mixed hearing loss of 50 dB in right ear and left ear mixed hearing loss of 40dB. Preop HRCT and MRI temporal bone showed right external auditory canal soft tissue extending from aditus to antrum with destruction of ear ossicles, thinning of tegmen and bony defect on lateral aspect of temporal bone (figure -1A,1B). The choice of surgical

approach was based on the extent of tumor determined via physical examination and imaging studies. Tumor was categorized as University of Pittsburgh (T4N0Mx) Stage 4.

A lateral temporal bone resection with superficial parotidectomy with cavity obliteration Cul de sac closure of the right mastoid was performed under general anesthesia, revealing a defect in the lateral bony wall of the mastoid process. On further dissection it was seen that mastoid cavity was filled with tumor tissue, which bled easily. The tumor tissue was confirmed as a squamous cell carcinoma during the subsequent frozen section pathology reports. The tumor had grown upwards destroying the mastoid and tympanic cavity and infiltrating the dura of the middle cranial fossa. It had also destroyed the bony structure of the sigmoid sinus but had not infiltrated into soft tissues. Destruction of the anterior wall of the external auditory canal and the posterior wall of the tympanic cavity was also seen. But the facial nerve bony canal and labyrinth medial to the tumor were intact. Post operative histopathology reports were suggestive of moderately differentiated SCC temporal bone. Patient was in regular follow up in radiotherapy department after 2 weeks for intensity modulated radiotherapy (IMRT) (66 Gy at 2 Gy per fraction for 4 weeks).

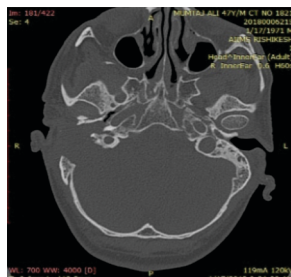


Figure 1A

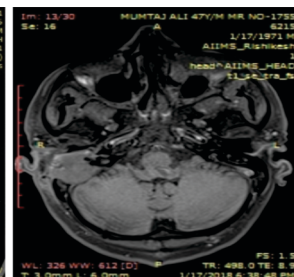


Figure 1B

CASE 2

A 53 year old female patient presented in ENT OPD with complaints of discharge from left ear for 1.5 years which was insidious in onset, mucopurulent, scanty, foul smelling, blood stained. There was pain in left infraauricular region for one year which was also associated with decreased hearing.

On otoscopic examination there was an irregular ulceroproliferative growth involving the left external auditory canal, firm in consistency, which did not bleed on touch. On tuning fork tests, Rinne test was negative on left side and positive on right side, Webers test was lateralized to left ear and absolute bone conduction tests were reduced on both

sides. Bilateral facial nerve examination was normal. On neck examination there was no significant lymph nodes or abnormality seen. On pure tone audiometry there was mixed hearing loss of 50 dB in left ear and 40 dB in right ear. MRI of temporal bone showed soft tissue mass 1cm anterior, 1.5cm posterior, 1cm superior and 1cm inferior away from external opening of pinna. Mass engulfing the ossicles but the medial wall of middle ear free from the growth (Fig 2A,2B). Biopsy was done at local hospital that reported moderately differentiated carcinoma of temporal bone. Tumor was categorized as University of Pittsburgh (T2N0Mx) stage 2.

A left lateral temporal bone resection with superficial parotidectomy was done under general anaesthesia, U shaped incision given from preauricular to postauricular, extending inferiorly to hyoid bone, excising the skin, superficial fascia and temporalis muscle. Circular incision with adequate margins from the tumor given in external auditory canal. Flaps elevated, cortical mastoidectomy done. Epitympanic dissection done upto temporomandibular joint. Extended facial recess approached isolating the facial nerve mastoid segment. Incudo-stapedial joint disarticulated. Tensor tympani tendon was cut. Facial recess extended and complete separation of specimen was done. Superficial parotidectomy done and branches of facial nerve were preserved. Fat and tensor fascia lata harvested from left anterolateral thigh. Eustachian tube opening obliterated using bone wax. Middle ear and mastoid cavity obliterated using fat, tensor fascia lata and temporalis muscle flap. Post operative HPE documented well differentiated squamous cell carcinoma in the resected tumor, attached salivary gland showed normal morphology, four intraparotid lymph nodes showed features of reactive lymph node hyperplasia. Patient followed up in radiotherapy department for further radiotherapy (60Gy at 2 Gy per fraction for four weeks) management after 2 weeks.

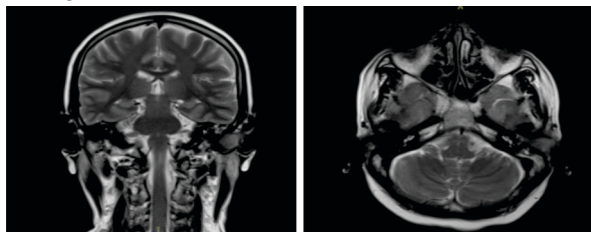


Figure 2A

Figure 2B

DISCUSSION

SCC temporal bone are rare and have low incidence rates. Risk factors for SCC temporal bone are mostly unknown but few of the possible etiologies are chronic suppurative otitis media, cholesteatoma or previous radiotherapy exposure. Approximately 75 % to 85 % of malignant tumors of temporal bone are secondary to CSOM [9]. As chronic inflammation of malignant tumors of middle ear mucosa may lead to metaplasia. In our experience both cases had history of CSOM.

Symptomatology of SCC temporal bone are mostly atypical. Most commonly presenting complaints in these cases were blood stained otorrhoea, mass in external auditory canal, decreased hearing and otalgia in affected ear. Further as tumor extends to middle ear, inner ear or petrous apex patient may presents with vestibulopathy, cranial nerve neuropathies in which facial nerve involvement is the most commonly encountered nerve.

As the presentation is obscure there are more chances of misdiagnosis hence causing the treatment delay. So high suspicion of carcinoma temporal bone is necessary and should be kept in mind in all cases of CSOM. For confirmation of diagnosis tissue biopsy is necessary. If first tissue biopsy is

negative and clinically external auditory canal mass is of high suspicion it is advisable to repeat biopsy in those cases.

In both of our cases tissue biopsy were found to be moderately differentiated SCC. HRCT and magnetic resonance imaging (MRI) should be done in all cases of diagnosed malignancy of temporal bone for staging the disease and determining the extent of surgical limits. HRCT would help in assessing the tumor invasion into bony structures and MRI would give details of tumor with dural and brain involvement. In one of our case tumor destroyed the mastoid and tympanic cavity infiltrating dura of middle cranial fossa and sigmoid sinus. Other case had only limited involvement of external auditory canal and middle ear.

Surgery with post operative radiotherapy is the main treatment approach in our both cases of SCC temporal bone [10]. In one case with University of Pittsburgh (T4N0Mx) tumor stage 4, surgical approach was lateral temporal bone resection with superficial parotidectomy with mastoid and tympanic cavity obliteration and Cul de sac closure. In other case with university of Pittsburgh (T2N0Mx) stage 2 lateral temporal bone resection with superficial parotidectomy was done. Post surgery histopathological report confirmed moderately differentiated SCC temporal bone in both cases. Patients were followed up in radiotherapy department after 2 weeks for further management.

CONCLUSION :

High index of suspicion is required for early diagnosis and treatment of SCC temporal bone which carries a better prognosis. Surgical treatment with lateral temporal bone resection with superficial parotidectomy followed by radiotherapy appears to be the best treatment modality.

REFERENCES.

- Gidley PW, Roberts DB, Sturgis EM. Squamous cell carcinoma of the temporal bone. *Laryngoscope*. 2010;120:1144Y51.
- Barrs DM. Temporal bone carcinoma. *Otolaryngol Clin North Am*. 2001;34:1197Y218.
- Martinez-Devesa P, Barnes ML, Milford CA. Malignant tumours of the ear and temporal bone: a study of 27 patients and review of their management. *Skull Base*. 2008;18.
- Lim LH, Goh YH, Chan YM, Chong VF, Low WK. Malignancy of the temporal bone and external auditory canal. *Otolaryngol Head Neck Surg*. 2000;122:882Y6.
- Moffat DA, Wagstaff SA, Hardy DG. The outcome of radical surgery and postoperative radiotherapy for squamous carcinoma of the temporal bone. *Laryngoscope*. 2005;115:341Y7.
- Tsai ST, Li C, Jin YT, Chao WY, Su JJ. High prevalence of human papillomavirus types 16 and 18 in middle-ear carcinomas. *Int J Cancer*. 1997;71:208Y12.
- Masterson L, Winder DM, Marker A, et al. Investigating the role of human papillomavirus in squamous cell carcinoma of the temporal bone. *Head Neck Oncol*. 2013;5:22.
- Lewis JS. Temporal bone resection: review of 100 cases. *Arch Otolaryngol*. 1975;101:23Y5.9. Zhang F, Sha Y. Computed tomography and magnetic resonance imaging findings for primary middle-ear carcinoma. *J Laryngol Otol* 2013; 127: 578-83.
- Bacciu A, Clemente IA, Piccirillo E, Ferrari S, Sanna M. Guidelines for treating temporal bone carcinoma based on long-term outcomes. *Otol Neurotol* 2013; 34: 898-907.