



## RETROSPECTIVE ANALYSIS OF OUTCOMES OF OPERATED SUBAXIAL CERVICAL SPINE INJURIES

**Rahul Kumar Singh**

Department of Orthopaedics, Heritage Institute of Medical Sciences, Varanasi, Uttar Pradesh, India

**Chhewang Topgia\***

Department of Orthopaedics, Vardhman Mahavir Medical College, New Delhi, India. \*Corresponding Author

**Abhishek Pandey**

Department of Orthopaedics, Heritage Institute of Medical Sciences, Varanasi, Uttar Pradesh, India

### ABSTRACT

**Background:** Cervical spinal cord injuries represent 20-33% of total spinal injuries with the prevalence of the subaxial levels. **Aim:** This study aimed to evaluate the outcome of operated subaxial cervical spine injuries. **Methods:** This study included retrospective analysis of patients with subaxial cervical spine injuries admitted and operated before 2016. The patients with subaxial cervical spine injuries with SLIC score  $\geq 4$ , relative sagittal plane translation  $> 3.5$  mm, relative sagittal plane rotation  $> 11$  degrees, and/or 3 columns injury and two columns injury with neurological deficit were included. Patients medically unfit for surgery, operated through posterior approach, SLIC scores  $< 3$ , and with single and two columns injury without neurological deficit, were excluded. **Results:** Forty-one patients were included in the study. In this study, 39% patients had compressive flexion followed by distractive flexion (24.4%), and vertical compression (19.5%), majority of fractures were type B (53.66%) followed by type C (43.90%), and type 1 (2.44%) fractures. Fracture was the most common injury (46.34%) followed by post-traumatic disc prolapse without significant bony injury (26.83%), pure subluxation (14.63%), and fracture dislocation (12.20%). Retropulsed fragment was present in 34.15% patients, 53.7% had ruptured disc, ALL and PLL was intact in 61% and 12% patients respectively. 29.3% patients had no disability while 61% had mild disability. Only 9.7% patients had moderate disability. None of the patients had severe or complete disability. 68.3% were in Bridwell fusion grade 1 followed by 29.3% in grade 2, and 2.44% in grade 3. Transient dysphagia was the only complication in 70.7% patients. Remaining patients had no complications. **Conclusion:** Cervical spinal cord injuries patients after operation have better functional, neurologic, and radiologic outcome.

**KEYWORDS :** subaxial cervical spine, SLIC score, ASIA grade

### INTRODUCTION

The subaxial cervical spine consists of levels C3 through C7 and includes both the bony anatomy as well as the ligamentous anatomy. Injuries to the subaxial cervical spine can be bony, soft tissue, or a combination of the two.[1] Subaxial cervical spine fractures can be the result of high-energy mechanisms such as motor vehicle accidents and falls from heights to moderate energy mechanisms such as contact and non-contact sports. They can even occur lower energy mechanisms such as ground-level falls. The cervical spine is vulnerable to injury due to the vast amount of motion allowed in this region of the spine.[2] The different mechanisms of injury lead to both different fracture patterns as well as various ligamentous injuries.

Cervical spine injuries occur in 3% of blunt force trauma patients with the subaxial cervical spine being a common location within the cervical spine; 50% of injuries occur between C5 and C7.[2] These can be seen in young patients with high energy mechanisms of injury or older patients with low energy mechanisms of injury.

The numerous fracture and dislocation patterns of the subaxial cervical spine lend to difficulty in creating a reliable and reproducible classification system that allows concise communication, management decision making, and prognostication. Of the more modern classification systems proposed by the Spinal Trauma Study Group, the Subaxial Injury Classification System (SLIC) is commonly used. This is a system based on the injury morphology, competency of the DLC, and the neurological status of the patient. Each of these categories is individually analyzed and given a score in which the sum of the score for all three categories is used for prognostication and management decision making [3]. Conservative treatment is indicated for a score of 3 or less, whereas a score of 5 or greater suggests operative intervention. A score of 4 identifies a gray area where a surgeon's experience and other patient comorbidities may

drive a decision either towards operative stabilization or conservative management.

Fractures deemed unstable or having the potential for neurological compromise in a patient who is fit for surgery should be treated with operative intervention. Surgical intervention can be performed either through an anterior or posterior approach and should be based on the pathology of the injury pattern. Anterior approaches may be associated with fewer wound complications and a higher fusion rate at the risk of postoperative swallowing difficulties [4]. There are however no differences in neurological recovery or patient-reported outcome measures [4, 5].

This study aimed to evaluate the outcome of operated subaxial cervical spine injuries.

### Patients and Methods

This study included retrospective analysis of patients with subaxial cervical spine injuries admitted and operated before 2016. The patients' records were obtained from medical records and these patients were called for follow up, assessed radiologically, neurologically using ASIA chart and for functional outcome as per neck disability index.

The patients with subaxial cervical spine injuries with SLIC score  $\geq 4$ , relative sagittal plane translation  $> 3.5$  mm, relative sagittal plane rotation  $> 11$  degrees, and/or 3 columns injury and two columns injury with neurological deficit were included. Patients medically unfit for surgery, operated through posterior approach, SLIC scores  $< 3$ , and with single and two columns injury without neurological deficit, were excluded.

### Positioning of patient

The patient was positioned supine on the operating table. The standard in line endotracheal intubation was performed with the head slightly extended. The Crutchfield tong was applied

anterior to the ear. The top of the patient's head extended just past the upper end of the fixed aspect of the operating table. This facilitated neck flexion/extension by raising /lowering the head section of the table. The head slightly rotated to about 10 to 15 degrees to the opposite side. Reverse Trendelenburg position of about 10 degrees given to decrease the dependency of the head and neck surgery and decrease venous plexus congestion.

**Anterior approach to cervical spine (Southwick and Robinson)**

The medial border of the sternocleidomastoid is palpated and marked from the mastoid process to its insertion onto the clavicle. The longitudinal incision made below the mandible parallel to sternocleidomastoid over left side of neck at the level of surgery. Palpation of surface landmarks is useful in deciding on the location. The cricoid cartilage is at the level of the C6 vertebral body, the thyroid cartilage is at the level of the C4-C5 disc space, and the hyoid bone is at the level of the C3 vertebral body.

**Data analysis**

Data were presented as frequency and percentage.

**RESULTS**

**General characteristics**

Forty-one patients were included in the study. Table 1 shows the general characteristics of the study subjects. Mean age of the patients was 38.07 ± 12.64 years. Majority of the patients were younger; only 2.4% patients aged above 75 years. Male to female ratio was 2.73:1. Forty-nine percent were farmers. Fall from height was the most common mode of trauma in 56% patients. All patients had pain as well as difficulty in movements. Forty-one percent had radiculopathy while upper motor neuron (UMN) features were present in 12.2% patients. Sixty-one percent patients had neurologic deficit.

**Classification of subaxial spinal injury**

In this study, 39% patients had compressive flexion followed by distractive flexion (24.4%), and vertical compression (19.5%) (Figure 1).

**AO classification**

In this study, majority of fractures were type B (53.66%) followed by type C (43.90%), and type 1 (2.44%) fractures.

**Type of injury**

Fracture was the most common injury (46.34%) followed by post-traumatic disc prolapse without significant bony injury (26.83%), pure subluxation (14.63%), and fracture dislocation (12.20%).

**Intraoperative findings**

Retropulsed fragment was present in 34.15% patients, 53.7% had ruptured disc, ALL and PLL was intact in 61% and 12% patients respectively (Table 2).

**Post-operative findings**

**ASIA grading**

Table 3 shows improvement in ASIA grading. Pre-operatively, 41.5% patients were in ASIA type E grade followed by type D (34.15%), type C (21.95%), and type B (2.44%). Post-operatively, none of the patients was in type B grade. Sixty-one percent were in type E grade followed by 36.6% patients in type D.

**Disability**

In this study, 29.3% patients had no disability while 61% had mild disability. Only 9.7% patients had moderate disability. None of the patients had severe or complete disability.

**Bridwell fusion grade**

Our study found that 68.3% were in grade 1 followed by 29.3% in grade 2, and 2.44% in grade 3.

**Complications**

Transient dysphagia was the only complication in 70.7% patients. Remaining patients had no complications.

**DISCUSSION**

Subaxial cervical spine includes C3 to C7 vertebra. Individual subaxial cervical spine injuries represent a wide spectrum of damage to the anatomic structures of the neck, including fractures, ligamentous injury, and disc disruption, often with injury to the cervical spinal cord and nerve roots [6]. Given its considerable mobility and its close proximity to the more rigid thoracic region, the subaxial cervical spine is particularly susceptible to traumatic disruption, which may often be accompanied by catastrophic neurologic insults as well [7].

Many surgical series recommend early treatment with aggressive canal decompression, improving neurological outcomes and also offering immediate stabilization. In subaxial cervical spine injuries SLIC score is used to determine the threshold for surgical intervention. In our study for these patients with SLIC score 4 preferentially early surgery was indicated in view of refinements of spinal instrumentation and early mobilization, most of the patients in our study with SLIC score 4 were in young age group (55% in 15-30 years and 80% in 15 to 45 years), severe radiculopathy involving motor and sensory impairment, and radiological parameters associated with failure in conservative management of these injuries, such as more than 40% of height compression, kyphotic angulation higher than 15° or 20% of subluxation of one vertebra on another are not addressed by the SLIC score.

Surgical stabilization has been described using both anterior and posterior approach or combined approach. In our study subaxial cervical spine injuries treated operatively with anterior corpectomy and stabilization with cage filled with autologous bone graft of vertebral body and cervical locking plate are studied. The advantages of using interbody cages for reconstruction after anterior cervical corpectomy fusion include, avoidance of morbidity associated with autologous bone graft (iliac crest) harvesting, compared with multi-level anterior cervical discectomy and fusion should result in lesser fusion rates because of increased graft host interfaces where fusion needs to occur [9].

In our study, there was an improvement in ASIA grading, fusion rates which is in agreement with previously reported studies. Postoperative transient dysphagia was most common complication seen in our patients.

**CONCLUSION**

Anterior cervical corpectomy and stabilization with cage filled with bone and cervical reflex locking plate is good and safe method in treating subaxial cervical spine injuries. This procedure has benefits of high primary stability, anatomical reduction, and direct decompression of spinal cord with minimal complications. The patients have better functional, neurologic, and radiological outcomes.

**Table 1: General characteristics**

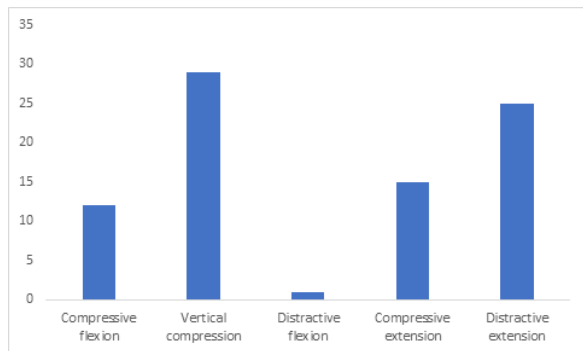
	Frequency	Percentages
<b>Retropulsed fragment</b>		
Present	14	34.15
Absent	27	65.85
<b>Disc status</b>		
Ruptured	22	53.66
Degenerated	6	14.63
Prolapsed	13	31.71
<b>ALL status</b>		
Intact	25	60.98
Torn	16	39.02
<b>PLL status</b>		
Intact	5	12.20
Torn	36	87.80

**Table 2: Intraoperative findings**

	Frequency	Percentages
<b>Age (years)</b>		
15-30	14	34.15
31-45	15	36.59
46-60	9	21.95
61-75	2	4.88
>75	1	2.44
<b>Sex</b>		
Male	30	73.17
Female	11	26.83
<b>Occupation</b>		
Farmer	20	48.78
Labourer	9	21.95
Others	12	29.27
<b>Mode of trauma</b>		
Road traffic accident	18	43.90
Fall from height	23	56.10
<b>Radiculopathy</b>		
Yes	17	41.46
<b>Neurologic deficit</b>		
Yes	25	60.98
<b>UMN features</b>		
Present	5	12.20

**Table 3: Improvement in ASIA grading**

Pre-operative	Post-operative		
	Type C	Type D	Type E
Type B	0	1	0
Type C	1	8	0
Type D		6	8
Type E		0	17



**Figure 1: Allen and Ferrugsons classification**

**REFERENCES**

1. Stauffer ES. Subaxial injuries. Clin. Orthop. Relat. Res. 1989;239:30-39.
2. Feuchtbaum E, Buchowski J, Zebala L. Subaxial cervical spine trauma. Curr Rev Musculoskelet Med. 2016;9:496-504
3. Vaccaro AR, Hulbert RJ, Patel AA, Spine Trauma Study Group et al. The Subaxial Cervical Spine Injury Classification System: a novel approach to recognize the importance of morphology, neurology, and integrity of the disco-ligamentous complex. Spine. 2007;32:2365-74
4. Kwon BK, Fisher CF, Boyd MC, et al. A prospective randomized controlled trial of anterior compared to posterior stabilization for unilateral facet injuries of the cervical spine. J Neurosurg Spine. 2007;7:1-12.
5. Brodke DS, Anderson PA, Newell DW, Grady MS, Champan JR. Comparison of anterior and posterior approaches in cervical spinal cord injuries. J Spinal Disord Tech. 2003;1:229-35
6. Raniga SB, Menon V, Al Muzahmi KS, Butt S. MDCT of acute subaxial cervical spine trauma: a mechanism-based approach. Insights Imaging. 2014;5:321-338
7. Whang PG, Patel AA, Vaccaro AR. The development and evaluation of the subaxial injury classification scoring system for cervical spine trauma. Clin Orthop Relat Res. 2011;469(3):723-731.