



CORRELATION OF CENTRAL MACULAR THICKNESS AND SEVERITY OF DIABETIC RETINOPATHY

Abhishek Padha	Assistant Professor, Department of Ophthalmology, Govt. Medical College, Doda, J&K.
Swati Sharma*	Resident, Department of Ophthalmology, Govt. Medical College, Doda, J&K. *Corresponding Author
Ravinder K. Gupta	Professor, Department of Ophthalmology, Maharishi Markandeshwar Medical College and Hospital, Solan, Himachal Pradesh, India.

ABSTRACT

Background : Diabetic Maculopathy is a common complication of diabetes mellitus, characterized by macular edema and frequently accompanied by lipid exudation. It is the major cause of loss of vision from diabetic retinopathy.

Purpose: To assess the changes in central macular thickness in diabetics with different stages of retinopathy and in non-diabetic controls.

Materials And Methods: This retrospective observational study was conducted in the Department of Ophthalmology in Maharishi Markandeshwar Medical College & Hospital, Solan, H.P,India. It was conducted on 100 eyes of 50 diabetics and non-diabetics each and the data records of 50 random patients of diabetic retinopathy, on whom FFA for studying the severity of diabetic retinopathy as well as OCT (Cirrus HD-OCT 500) for macular thickness was performed .Comparison of central macular thickness with increasing severity of diabetic retinopathy was done.

Results : The mean age of patients and the mean central macular thickness in the study population was found to be 55.7 ± 9.05 years and $297.12 \pm 95.8 \mu\text{m}$. Whereas in the control group the mean central macular thickness was calculated to be $211.06 \pm 7.6 \mu\text{m}$. Central macular Thickness was found to be directly proportional to increasing stage of Diabetic Retinopathy.

Conclusion: OCT is a very sensitive tool for detection of macular oedema even in the stages when there is no suspicion of clinically significant macular oedema. It can be used in the regular follow up and monitoring of patients with diabetic retinopathy.

KEYWORDS : Central Macular Thickness, Diabetic Macular oedema, OCT

INTRODUCTION

Diabetes mellitus is a common metabolic disorder secondary to lack, diminished efficacy or both of endogenous insulin. As per the World Health Organization (2011) it is estimated that about 50.8 million people in India are affected with diabetes mellitus. Among the various manifestations of Diabetes Mellitus, diabetic retinopathy is the most common cause of legal blindness between ages of 20 and 65 years¹. Diabetic Retinopathy is a microangiopathy primarily affecting pre capillary venules, although larger vessels may also be involved. Retinopathy exhibits features of both microvascular occlusion and leakage, and is by far the most frequent and potentially blinding ocular manifestation of diabetes mellitus. Involvement of macula by oedema has a high incidence and is present in about 10% of diabetics. Presence of hard exudates or ischaemia known as diabetic maculopathy is the most common cause of visual impairment in diabetic patients, particularly those with type 2 diabetes. Approximately 25% of all diabetics have some form of retinopathy. The incidence and severity increase consistently over duration of diabetes so that more than 90% diabetics develop retinopathy at some time during their lives.

Diabetic Maculopathy is a common complication of diabetes mellitus, characterized by macular edema and frequently accompanied by lipid exudation. It is the major cause of loss of vision from diabetic retinopathy.

In 10% of the overall diabetic population and 25% of those with 20 or more years after onset, background retinopathy progresses to macular edema, which is the leading cause of visual impairment in diabetic patients². Diffuse retinal edema is caused by extensive capillary leakage, and localized oedema by focal leakage from microaneurysms and dilated capillary segments. Diabetic maculopathy is classified into following groups:-

1. Focal maculopathy- characterized by well circumscribed

retinal thickening associated with complete or incomplete rings of hard exudates.

2. Diffuse maculopathy- characterized by diffuse retinal thickening which may be associated with cystoid changes. Landmarks are obliterated by severe retinal oedema which may render localization of fovea impossible.

3. Ischaemic maculopathy- the signs are variable and the macula may look relatively normal despite reduced visual acuity. In other cases pre-proliferative diabetic retinopathy may be present.

4. Mixed maculopathy- frequently there is combined pathology particularly of diffuse edema and ischaemia.

Although fluorescein angiography is highly sensitive for the qualitative detection of fluid leakage which causes macular edema, measurement of retinal thickness may correlate better with areas of retinal dysfunction than does the amount of fluorescein leakage. Optical Coherence Tomography (OCT) enables the clinician to show accurately sub clinical retinal changes in the absence of clinically significant macular edema (CSME). OCT is more sensitive than stereoscopic fundus photography or biomicroscopy for the detection of DME and also allows a more objective assessment of the extent of macular edema³. Thus, OCT is being increasingly utilized in the diagnosis and treatment of DME. Prior studies on macular thickness dimensions in diabetics obtained using OCT and other instruments such as the retinal thickness analyser have stated variable findings³. Some studies^{4,5,6} in past informed significantly thinner peri-central macular thickness in patients with stage 1 Diabetic Retinopathy. The hypothesis behind this is that in earlier stage neuronal loss causes significant thinning in macular region. Macular edema is the most common cause of moderate visual loss in non proliferative diabetic retinopathy. This decreased vision is caused by an increase in extracellular fluid within the retina distorting the retinal architecture and frequently taking on a pattern of cystoid macular edema. This fluid accumulates

within the retina because of the breakdown of the barriers within the retinal blood vessels and possibly the retinal pigment epithelium This study was conducted to assess the changes in central macular thickness in diabetics with different stages of retinopathy and in non-diabetic controls.

MATERIALS AND METHODS

This retrospective observational study was conducted in the Department of Ophthalmology in Maharishi Markandeshwar Medical College & Hospital, Solan, H.P, India, in the month of November 2018. It was conducted on 100 eyes of 50 diabetics and non-diabetics each. Known cases of diabetes mellitus coming to the OPD for screening of Diabetic Retinopathy and patients referred from other departments or peripheral hospitals were included in the study. For our study we used the data records of 50 random patients of diabetic retinopathy, on whom FFA for studying the severity of diabetic retinopathy as well as OCT (Cirrus HD-OCT 500) for macular thickness was performed. Patients were divided into five groups according to the International Clinical Diabetic Retinopathy Disease Severity Scale⁷, and macular thickness in correlation to the severity of diabetic retinopathy was studied in each group.

- Grade 1- Diabetics with no apparent Retinopathy
- Grade 2- Diabetics with Mild Non proliferative Diabetic Retinopathy
- Grade 3- Diabetics with Moderate Non proliferative Diabetic Retinopathy
- Grade 4- Diabetics with Severe Non proliferative Diabetic Retinopathy
- Grade 5- Diabetics with Proliferative Diabetic Retinopathy

All the data recorded from the patients were entered into Microsoft Excel (Microsoft Corporation, Redmond, WA, USA) and reviewed for any correlations.

Inclusion Criteria

1. Diabetic patients with CSME as described on Slit lamp biomicroscopy and FFA
2. Diabetic Patients of either sex with age 30-70 years

Exclusion Criteria

1. Patients with prior laser treatment for diabetic macular edema or proliferative retinopathy.
2. Any other macular pathology like macular dystrophy, macular degeneration, or macular hole.
3. Patients with age <30 years
4. Patients with hazey media in whom OCT wasn't done

RESULTS

Out of all the patients studied the maximum no. of patients (23) were present in the age group of 50-60 years, followed by 14 patients in the age group 60-70 years. The least no. of patients (4) were in the age group of 30-40 years. The mean age of patients in the study population was found to be 55.7±9.05 years. The mean central macular thickness in the study population was calculated as 297.12±95.8 μm, whereas in the control group it was calculated to be 211.06±7.6 μm. A statistically significant difference was observed in the mean central macular thickness between the two groups (p<0.05) using unpaired Student's t-test. The highest value of central macular thickness recorded in our study was 793 μm whereas the lowest value was 181 μm.

On comparing the values of central macular thickness among the various grades of diabetic retinopathy, we found out the mean central macular thickness was maximum in PDR subgroup (490.42 ± 138.65 μm) and the least was recorded with subgroup having no signs of Diabetic retinopathy (227.63±13.59 μm)

The mean central macular thickness in different grades of retinopathy is shown in Table 1.

Table 1. Showing Central Macular Thickness And The Mean Ages Of The Patients In Different Grades Of Diabetic Retinopathy

Grade of diabetic Retinopathy	Mean age of patients in years	Mean central macular thickness in μm
Grade -1	46.75±7.57	227.63±13.59
Grade -2	52.95±9.04	260.77±15.51
Grade-3	58.09±7.24	266.03±21.03
Grade -4	55.18±8.36	303.77±22.06
Grade -5	61.8±7.09	490.42±138.65

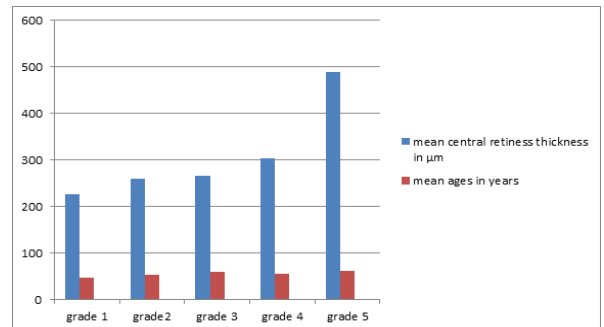


Fig. 1 Depicting Variation Of Central Macular Thickness With Grades Of Diabetic Retinopathy

DISCUSSION

Macular oedema is the most important cause of decreased vision in Diabetic Retinopathy. OCT can be used to quantitatively measure macular thickness for diagnosis and management of macular oedema and also to detect subclinical macular thickening in Diabetic Retinopathy⁸. Central macular Thickness is directly proportional to increasing stage of the disease as well as the age of the patient (as evident in table 1).

These results are similar to those observed in previous studies done by various researchers. The increase in mean macular thickness in diabetics as compared to non-diabetic controls can be explained by the pathophysiology of Diabetic Retinopathy. Alterations in glucose metabolism lead to changes in the capillary walls of retinal vessels, leading to breakdown of blood retinal barrier causing haemorrhages and seepage of exudates, which in turn present as detectable retinal thickening on OCT^{9,10,11}. Some researchers have reported early macular thickening in diabetic eyes, however, the difference was not statistically significant^{12,13,14,15}.

Our study didn't report any such finding. On comparing mean Central Macular Thickness in different grades of diabetic retinopathy subgroups, it was found to be progressively increasing with increasing stage of Diabetic retinopathy (Fig. 1). The mean Central Macular Thickness values in different subgroups of our subjects are in concordance with previous studies^{16,17}. The increased macular thickness with progressively increasing retinopathy can be explained by alterations in vascular permeability of peri-foveal and macular capillaries in diabetics eyes. To sum up, our study found out that there is a modest relationship between central macular thickness and severity of retinopathy. The changes in macular thickness can be found out on OCT despite having normal findings on slit lamp biomicroscopy.

CONCLUSION

OCT is a very sensitive tool for detection of macular oedema even in the stages when there is no suspicion of clinically significant macular oedema. It can be used in the regular follow up and monitoring of patients with diabetic retinopathy.

Acknowledgements: Nil

Conflicts Of Interest: None declared

REFERENCES

1. Bhavsar AR, Drouilhet JH, Atebara NH, et al: Diabetic Retinopathy. 2014, <http://emedicine.medscape.com/article/1225122-overview#a0156>
2. Klein R, Klein BE, Moss SE, et al. The Wisconsin epidemiologic study of diabetic retinopathy: XVII. The 14-year incidence and progression of diabetic retinopathy and associated risk factors in type 1 diabetes. *Ophthalmology* 1998;105(10):1801-1815.
3. Congdon N, O'Colmain B, Klaver CC, et al. Causes and prevalence of visual impairment among adults in the United States. *Arch Ophthalmol* 2004;122(4):477-485.
4. Wild S, Roglic G, Green A, et al. Global prevalence of diabetes: estimates for the year 2000 and projections for 2030. *Diabetes Care* 2004;27(5):1047-1053.
5. Bialosterski C, van Velthoven ME, Michelis RP, et al. Decreased optical coherence tomography-measured pericentral retinal thickness in patients with diabetes mellitus type 1 with minimal diabetic retinopathy. *Br J Ophthalmol* 2007;91(9):1135-1138.
6. Browning DJ, McOwen MD, Bowen Jr RM, O'Marah TL. Comparison of the clinical diagnosis of diabetic macular edema with diagnosis by optical coherence tomography. *Ophthalmology* 2004; 111(4): 712-715.
7. Supplement 1. American diabetes association: clinical practice recommendations 2000. *Diabetes Care* 2000;23(Suppl 1):S1-116.
8. Yang CS, Cheng CY, Lee FL, et al. Quantitative assessment of retinal thickness in diabetic patients with and without clinically significant macular edema using optical coherence tomography. *Acta Ophthalmol* 2001;79(3):266-270.
9. Schaudig UH, Glaefke C, Scholz F, et al. Optical coherence tomography for retinal thickness measurement in diabetic patients without clinically significant macular edema. *Ophthalmic Surg Lasers* 2000;31(3):182-186.
10. Brown JC, Solomon SD, Bressler SB, et al. Detection of diabetic foveal edema: contact lens biomicroscopy compared with optical coherence tomography. *Arch Ophthalmol* 2004;122(3):330-335.
11. Sanchez-Tocino H, Alvarez-Vidal A, Maldonado MJ, et al. Retinal thickness study with optical coherence tomography in patients with diabetes. *Invest Ophthalmol Vis Sci* 2002;43(5):1588-1594.
12. Kanski JJ, Bowling B, Nischal KK, et al. Retinal vascular disease. In: *Clinical ophthalmology: a systematic approach*. 7th edn. London: Elsevier Saunders 2011:534-543.
13. Massin P, Erginay A, Haouchine B, et al. Retinal thickness in healthy and diabetic subjects measured using optical coherence tomography mapping software. *Eur J Ophthalmol* 2002;12(2):102-108.
14. Sander B, Larsen M, Engler C, et al. Early changes in diabetic retinopathy: capillary loss and blood-retina barrier permeability in relation to metabolic control. *Acta Ophthalmol* 1994;72(5):553-559.
15. Oshitari T, Hanawa K, Adachi-Usami E. Changes of macular and RNFL thickness measured by stratus OCT in patients with early stage diabetes. *Eye* 2009;23(4):884-889.
16. Nussenblatt RB, Kauffman SC, Palestine AG, et al. Macular thickening and visual acuity. Measurement in patients with cystoid macular edema. *Ophthalmology* 1987;94(9):1134-1139.
17. Massin P, Erginay A, Haouchine B, et al. Retinal thickness in healthy and diabetic subjects measured using optical coherence tomography mapping software. *Eur J Ophthalmol* 2002;12(2):102-108