VOLUME - 10, ISSUE - 04, APRIL - 2021 • PRINT ISSN No. 2277 - 8160 • DOI : 10.36106/gjra

Original Research Paper

General Surgery

SPONTANEOUS PERFORATION OF MECKEL'S DIVERTICULUM: A CASE REPORT AND REVIEW OF LITERATURE

Prof Dr.B.Santhi	Government Kilpauk Medical College And Hospital
Dr.Subhashini .A	Government Kilpauk Medical College And Hospital
Dr.Preethi.V*	Government Kilpauk Medical College And Hospital *Corresponding Author

ABSTRACT

Meckel's diverticulum is the commonest congenital abnormality of the gastrointestinal tract. Hemorrhage obstruction and inflammation are the three main categories of complications resulting from Meckel's diverticulum. Spontaneously perforation of Meckel's diverticulum is very rare and mimics acute appendicitis. We report a case of 65 year-old female, who presented since 2 days worsening abdominal pain predominantly in the right iliac fossa associated with high grade fever and nausea. On physical examination her abdomen revealed diffuse tenderness, more over the right iliac fossa and the hypogastric region with guarding in the right iliac fossa. A provisional diagnosis of appendicular perforation was made. Our patient had an emergency laparotomy, where a perforated Meckel's diverticulum and advanced peritonitis were discovered. A resection of ileum with meckels diverticulum with end to end anastomosis of ileal loops were performed. Heterotopic mucosa of diverticulitis was confirmed on histopathology. The patient made an uneventful recovery postoperatively . This case report is an interesting and unusual case of Meckel's diverticulum complications and highlights the importance of considering Meckel's diverticulum as a differential diagnosis in every patient presenting with acute abdomen.

KEYWORDS :

INTRODUCTION

Meckel's diverticulum (MD), first described in 1808, results from failure of complete obliteration of the vitelline duct. It is a common anomaly of the small intestine that occurs in approximately 2% of the population, often found incidentally at the time of abdominal exploration. The complications associated with MD include inflammation, perforation, hemorrhage, intussusception, volvulus, intestinal obstruction, and malignant transformation. The total lifetime complication rate has been reported to be around 4%.MD is the most prevalent congenital anomaly of the gastrointestinal tract, affecting approximately 2% of the general population. A 3:2 male to female ratio has been reported. Meckel's diverticula are designated true diverticula because their walls contain all of the layers found in normal intestine. Their location varies among individual patients, but they are usually found in the ileum within 100cm of the ileocecal valve. Approximately 60% of Meckel's diverticula contain heterotopic mucosa, of which over 60% consist of gastric mucosa [2-4].Other pancreatic mucosa (5%) and less commonly colonic mucosa, endometriosis, hepatobiliary tissue, which are responsible for other complications like hemorrhage, chronic peptic ulceration and perforation. Majority of the meckel's diverticulum remain silent and are diagnosed incidentally during small bowel contrast study, laparoscopy or laparotomy done for unrelated conditions, or until complications arise from the diverticulum.

A commonly quoted "rule of 2s"also applies:

- 2% of the population has the anomaly
- it is approximately 2 inches in length
- It is usually found within 2 feet of the ileocecal valve
- it is often found in children less than 2 years of age
- affects males twice as often as females
- These are good general guidelines, they are not based on accurate data. The overall lifetime complication rate is approximately 4% The most common presentation associated with symptomatic Meckel's diverticula is bleeding, followed by intestinal obstruction, diverticulitis, intussusceptions and neoplasm [2]. Here we provide an illustrative presentation, outlining one of the rarecomplications Of Meckel's diverticulum in adults.

CASE REPORT

A 60-year-old female, who presented 2 days ago, a history worsening abdominal pain associated with fever and nausea.On her admission, patient was toxic, but his vital signs were within normal range. A physical examination demonstrated tenderness and guarding over the right iliac fossa. His blood analysis revealed slight elevated blood count, his white blood cells (WBC) were 14,200/□l (normal values 4.6 to 10.2 × 103/mL) and 88% of them were neutrophils (normal values 40 to 75%). The rest of the routine preoperative blood tests and his erect chest and abdominal X-rays were unremarkable. CECT abdomen and pelvis revealed possibility of Meckels diverticulitis sealed ileal perforation. Initial management included intravenous fluid resuscitation and antibiotic coverage. After our patient gave her written consent, she was taken to the operating theatre and under epidural anaesthesia; a midline laparotomy incision was performed. A normal appearing appendix was identified, which did not have any remarkable sign of inflammation that could explain the contraction and the peritoneal irritation. During the operation, about 30ml of pus drained in right iliac fossa region and 150ml toxic fluid drained. Omental caking was found in the right iliac fossa region.

On examination of the small bowel revealed a Meckel's diverticulum at 60cm proximal to the ileocecal valve at the antimesentric border and adherent to the omentum and distal small bowel loops. The Meckel's diverticulum was inflamed and perforated at its base with a perforation size of 0.5*0.5cm. A segmental resection of ileum with meckels diverticulum with end to end anastomosis of ileal loops were performed. Abundant peritoneal toilet was done. Heterotopic mucosa of diverticulitis was confirmed on histopathology. The patient made an uneventful recovery postoperatively. Clinical follow up over the next two months was unremarkable

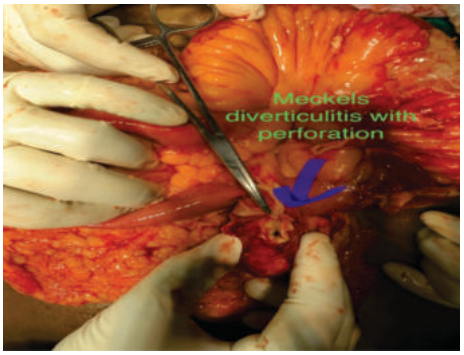

Figure 1: Preoperative view of perforated Meckel's diverticulum before excision

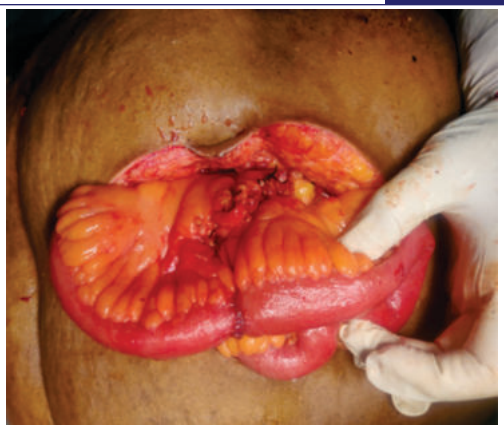

Figure 2: post segmental resection of the ileum with meckel's diverticulum with end to end anastomosis of ileal loops.

DISCUSSION

Meckel's diverticulum is a congenital anomaly found in approximately 2% of the general population. Complications develop in only 4% of patients with this malformation, with most cases presenting in childhood [2]. Complications of Meckel's diverticulum include hemorrhage, bowel obstruction, inflammation, perforation, intussusception, volvulus and malignant transformation.The pre-operative diagnosis of a patient with Meckel's diverticulum often presents a challenge to the clinician in both children and adults, because presenting symptoms can be non-specific and the differential diagnosis broad [5]. We report a complicated and unusual case of a patient with a spontaneous perforated Meckel's diverticulum who presented with acute abdomen. The patient required an open laparotomy for definitive diagnosis and management. Complications in patients with Meckel's diverticulum are rare; most patients remain asymptomatic for life [6]. The perforation of a Meckel's diverticulum may mimic acute appendicitis and present as an acute abdomen [7]. The perforation of a Meckel's diverticulum is either caused by; foreign body due to irritation of foreign body and pressure necrosis of the diverticulum wall, or spontaneous perforation due to progressive inflammation of Meckle's diverticulum wall as our case which produced peritonitis. Rarely, cases of perforation following blunt abdominal trauma have been reported, the first being by Park and Lucas in 1970. Four such cases have been reported in the medical literature. Ekwunife et al report the first from Africa [8]. A preoperative diagnosis of a complicated MD may be challenging because of the overlapping clinical and imaging features of other acute surgical and inflammatory conditions of the abdomen. A more specific diagnosis, however, will lead to greater recourse to a laparoscopic approach in its treatment [9].

CONCLUSION

Meckel's diverticulum complications are uncommon and challenge to diagnose. Early diagnosis and timely operative intervention must occur in order to provide the best outcome for these patients. Spontaneous perforated MD often presents as acute abdomen and its preoperative diagnosis is difficult. To patients with sudden abdominal pain mimic acute appendicitis accompanied by a past medical history of bloody stools and/or chronic recurrent abdominal pain, perforated MD should be kept in mind as a differential diagnosis.

COMPETING INTERESTS

The authors declare no competing interest.

Authors' contributions

All authors have contributed to realize this study and they have read and approved the final manuscript.

REFERENCES

1. Ding Y, Zhou Y , Ji Zh , Zhang J , Wang Q. Laparoscopic Management of Perforated Meckel's Diverticulum in Adults. Int J Med Sci. 2012; 9(3):243-7. PubMed | Google Scholar
2. Dimitriou I, Evaggelou N, Tavaki E, Chatzitheoklytos E. Perforation of Meckel's diverticulum by a fish bone presenting as acute appendicitis: acase report. J Med Case Rep. 2013 Oct 2; 7:231. PubMed | Google Scholar
3. Sharma RK,Jain VK. Emergency surgery for Meckel's diverticulum.World J Emerg Surg. 2008 Aug 13; 3:27. PubMed | Google Scholar
4. Dumper J, Mackenzie S, Mitchell P, Sutherland F, Quan ML, Mew D.Complications of Meckel's diverticula in adults ; Can J Surg. 2006 Oct;49(5):353-7. Google Scholar
5. Bemelman WA, Hugenholtz E, Heij HA, Wiersma PH, Obertop H. Meckel's diverticulum in Amsterdam: experience in 136 patients. World J Surg. 1995 Sep-Oct;19(5):734-6; discussion 737. PubMed | Google Scholar
6. Park JJ, Wolff BG, Tollefson MK, Walsh EE, Larson DR. the Mayo Clinic experience with 1476 patients (1950-2002). Ann Surg. 2005 Mar;241(3):529-33. PubMed | Google Scholar
7. Bani-Hani KE, Shatnawi NJ. Meckel's diverticulum: comparison of incidental and symptomatic cases.World J Surg.2004 Sep; 28(9):917-20. PubMed | Google Scholar
8. Christopher N Ekwunife, Tobechi N Mbadugha and Udonna N Ogbue. Isolated Meckel's diverticulum perforation as a sequel to blunt abdominal trauma: a case report . J of Medical Case Reports. 2014; 8:111. PubMed | Google Scholar
9. Quarrie R, Lindsey D and Bahner DP. Review of the Incidence and Management of Meckel's Diverticulum. Austin J Surg. 2014;1(3): 1015. PubMed | Google Scholar