VOLUME - 10, ISSUE - 08, AUGUST- 2021 • PRINT ISSN No. 2277 - 8160 • DOI : 10.36106/gjra

Original Research Paper

Plastic Surgery

FOUR UNUSUAL AND EXTENSIVE CASES OF "ACNE KELOIDALIS NUCHAE", SUCCESSFULLY MANAGED BY EXCISION AND PRIMARY SKIN GRAFTING.-A REVIEW.

Dr.Anji Reddy Kallam

MS(Gen.surgery) MS (Plastic surgery), Medical Director, & Consultant Plastic Surgeon, Alluri Sitaramaraju Academy Of Medical Sciences (ASRAM) ELURU, Wt.Godavari, ANDHRA PRADESH-534005.INDIA.

ABSTRACT

Acne keloidalis nuchae (AKN) is a chronic, idiopathic,inflammatory condition most commonly occurring in young dark skinned males and represents nearly 0.45% of all dermatoses affecting black skinned patients. The male to female ratio is 20:1.It is initially characterized as firm skin colored papules and pustules on the occipital region of the scalp and posterior aspect of the upper part of the neck. These lesions later coalesce and may ultimately develop into tumor-like masses giving the appearance of keloidal plaques with destruction of hair follicles and loss of hair.Intracutaneous abscesses and sinus tracts with purulent discharge appear in advanced cases.In long standing cases these lesions give an appearance of Linea Cutis Gyrata because of its resemblance with the surface of the brain.While the pathogenesis remains uncertain, precipitating factors include localized trauma, chronic irritation, seborrhea, and androgen excess.In this article I review my experiences in four patients with extensive lesions. Two of the patients are brothers in the same family and discuss the advantages of management by electrosurgical excision followed by primary skin grafting in extensive cases involving the nape of the neck,extending to the occipital region of the scalp.

KEYWORDS : Acne keloidalis- Acne keloidalis nuchae-Folliculitis keloidalis.

CASE REPORTS

CASE-ONE,Sobhan babu,M/39 YRS

A 39 year old obese individual, dark skinned, presented with multiple Papulo Pustular lesions with thick scar formation in the nape of the neck giving the appearance of Linea Cutis Gyrata.

The lesion started 6 years back with isolated lesions and over the last 6 months they are increasing in size & extent and troubling with pain,itching,discharge with foul smell and feeling uncomfortable to go for his regular Office duties.

There is superficial excoriation with discharge and loss of hair.

He had taken treatment from several Surgeons,Physicians & Dermatologists at Tenali,Guntur & Vijayawada and also Homeopathy treatment over nearly 6 yrs. without any benefit.Spent more than Rs. 3 lacs over the period of 5 yrs.

He is an employee in the state government at tenali and was referred by the local MLA.for necessary medical help.

He was admitted at NRI MEDICAL COLLEGE HOSPITAL for treatment on 14-02-2012.He was operated on 21-02-2012.Excision and primary skin grafting was done.

He is comfortable and happy without any recurrence as per the feedback on 05-06-2017 (5 yrs 4 months postop).

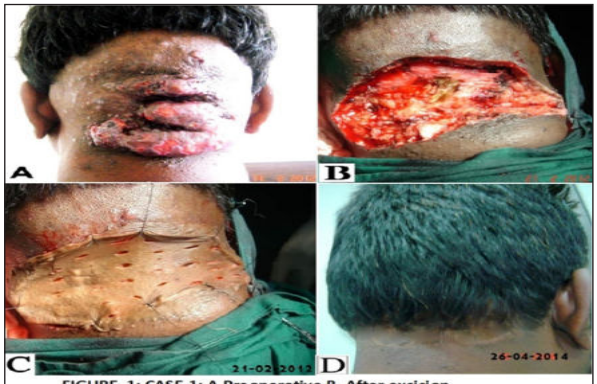

FIGURE 1: CASE-1: A.Preoperative B. After excision C.After skin grafting D. Two years postop

Photo -1 a)preop.b)excision defect c)primary skin graft d)postop after 2 yrs 3 months

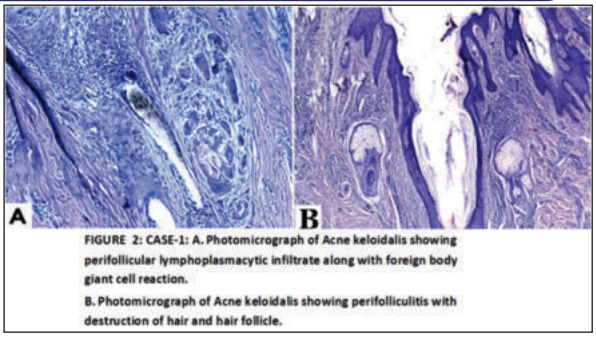

FIGURE 2: CASE-1: A. Photomicrograph of Acne keloidalis showing perifollicular lymphoplasmacytic infiltrate along with foreign body giant cell reaction.
B. Photomicrograph of Acne keloidalis showing perifolliculitis with destruction of hair and hair follicle.

Photo-2 a) & b) photomicrographs

CASE:-TWO,S.Ravindranadh Tagore M/37 yrs

A 36 years old male,with dark complexion,obese,younger brother of 1st patient developed papulo pustular lesions in the nape of the neck 4 years back. He took several antibiotics and local application of ointments as prescribed by physicians and dermatologists without any result. Over the last 3 months the lesions were increasing in size, itching and painful with tumor formation and loss of hair over the lesions.

He was unable to attend to his work as state govt. employee.
He was admitted at ASRAM MEDICAL COLLEGE HOSPITAL ,Eluru on 10-04-2014.Excision and primary skin grafting was done after due preparation on 19-04-2014

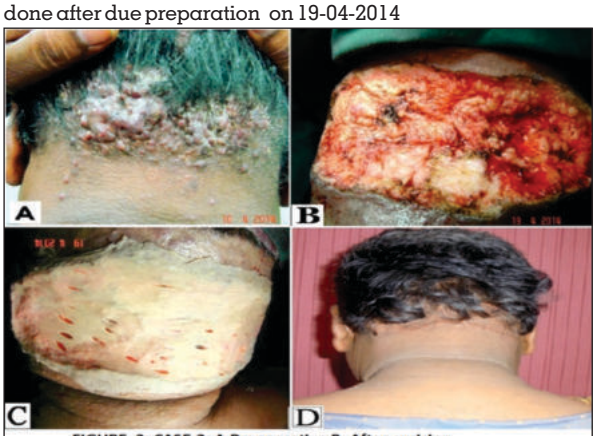

FIGURE 3: CASE-2: A.Preoperative B. After excision C.After skin grafting D. Four years postop

Photo-3 case-2 a) preop b)excion defect c)skin grafting d)postop 4 years.

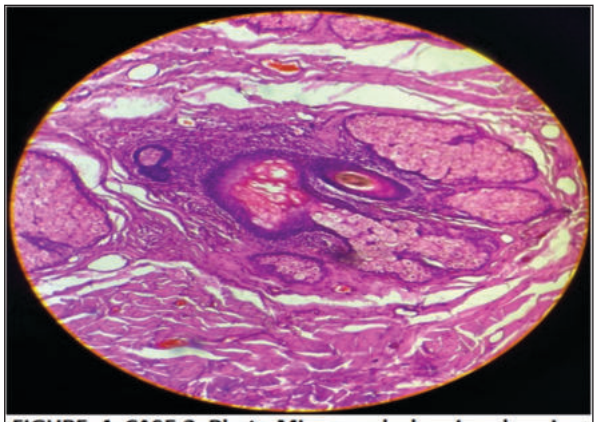

FIGURE 4: CASE-2: Photo Micrograph showing chronic inflammatory reaction

Photo-4 Photomicrograph

Case: Three

A.Kedareswara Swamy/Male /26 YRS/Agricultural Labourer.

Admitted in ASRAM Hospital ON 23-12-2019 & Operated on 24-12-2019(Excision and primary skin grafting was done)

Papulo-pustular lesions in the occipital region extending on to the nape of the neck over the last 4 years.

Had treatment by several physicians and dermatologists with antibiotics and local applications.He had no relief.

He also had homeopathic treatment without any relief.

The lesions were inreasing and formed into thick scar in the occipital region of scalp with superficial excoriation with discharge and lot of discomfort.

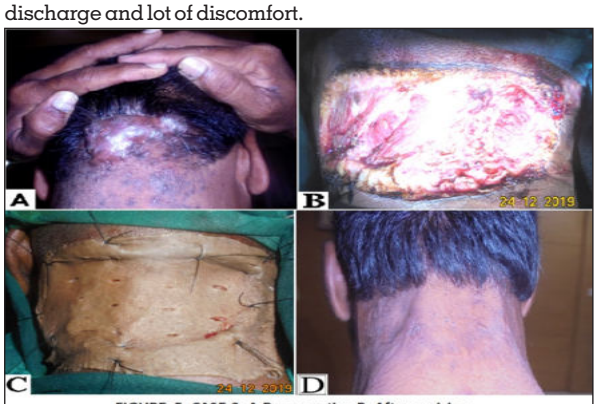

FIGURE 5: CASE-3: A.Preoperative B. After excision C.After skin grafting D. One year postop

Photo-5 case-3 a) preop b)post excision defect c)skin grafting d)postop after 1 year

Case-Four

K.Pentaiah/Male 26 Yrs,Masonory worker with Swelling Scalp-since childhood,gradually increasing in size with occasional seropurulent discharge with pain.

First attended general surgery outpatient dept..on 01-12-2020 u/s scanning was done

Opined as neurofibroma or fibroma.
Advised excision
Patient Attended plastic surgery op on 30-12-2020
Clinically diagnosed as acni keloidalis nuchae due to clinical features

Advised admission for surgical excision and skin grafting. After routine investigations

Admitted on 2-1-2021

Operated on 4-1-2021 under GA/prone position

Excision and primary skin grafting was done.HP report-Acne keloidalis nuchae.

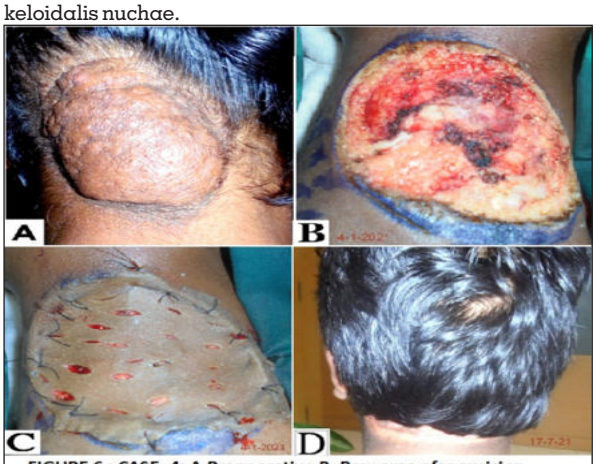

FIGURE 6 : CASE -4: A.Preoperative B. Raw area afer excision C.After skin grafting D.7 months postop

Photograph-6- case-4)-a) preop b)post excision defect c)skin grafting d) 7 months postop.

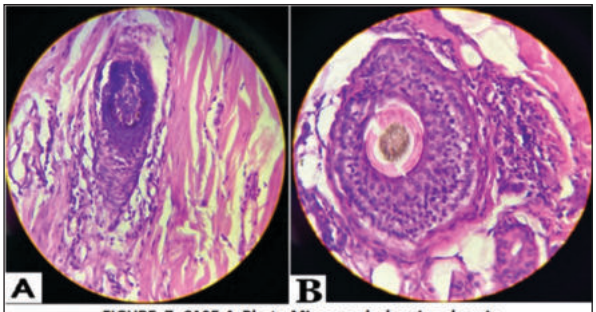

FIGURE 7: CASE-4: Photo Micrograph showing chronic inflammatory reaction A. Low power B. high power

Photo 7) a & b-photomicrograph

Treatment:

After necessary local preparation all the patients were operated under general endotracheal anesthesia, keeping the patient in prone position. The entire lesion was excised, with horizontal elliptical incision using electro surgical cautery going up to the deep dermis ensuring complete removal of the lesion. Bleeding was minimal and estimated, less than 200 ml for the entire procedure. The raw area was covered primarily by single sheet of meshed split skin graft of medium thickness, harvested from posterior or lateral aspect of thigh. Soft medium sized cervical collar was given to restrict the movements of the neck. The graft took up completely when primary dressing was done after 5 days and the patient was discharged from the hospital on 7th postoperative day.The diagnosis was confirmed by histopathology They are followed up regularly every month and they returned to their work within 2 weeks after surgery. First patient who came for follow up after one month and after 2 years 3 months showed no evidence of recurrence and extremely happy without any symptoms and the grafted area did not pose any cosmetic problem.Second patient followed one year after operation and the grafted site completely healed and doing his regular work and has no cosmetic problem. Other two patients also had complete recovery.

DISCUSSION

Kaposi first described this lesion in 1869 and described as dermatitis papillaris capilliti. [1] Bazin in 1872 first named this lesion as Acne Keloidalis. [2]This idiopathic inflammatory

condition is most commonly seen in young African-American men after puberty, representing approximately 0.45 percent of all dermatoses affecting African Americans. [3]The male-to-female ratio is approximately 20:1, and these cases are rarely reported in women. [4]

The cause of this lesion is unknown and is not a true keloid and has no relationship with Acne Vulgaris.Many have proposed an etiology similar to that of pseudofolliculitis barbae, implicating the action of hairs curving into the skin leading to a foreign body inflammatory reaction. [5] Close shaving of hair in the low neck area with the curved, coarse type of hair that is typically seen in black patients has been proposed as an etiological factor in 90 percent of AKN cases. [6] But such an appearance is not seen in our patients.

Additional proposed etiological factors include constant irritation from shirt collars,wearing helmets and chronic low-grade folliculitis. [7] In a small case series, four patients with AKN were found to have an associated acanthosis nigricans, suggesting that acne keloidalis may represent a cutaneous sign for the metabolic syndrome. [8] Cases of acne keloidalis occurring in Caucasian patients after cyclosporin use following organ transplantation have also been reported. [9], [10] The development of this disease in brothers of same family as our first two cases needs further probe regarding role of any hereditary factor.

The clinical spectrum of AKN is broad. Initial lesions are small, firm, discrete, follicular papules and pustules on the occipital scalp and posterior neck. With time, the papules coalesce into horizontal hairless keloidal plaques, which may be fringed with tufted hairs. In the most extreme forms, disfiguring tumor-like masses or abscesses exuding odiferous pus may be present. Although many cases of AKN are asymptomatic, patients may complain of pruritus or pain, and the lesions are often a cause of tremendous cosmetic concern.

PATHOLOGY:

Histologically, in early stages there will be dense follicular and perifollicular infiltration consisting of neutrophils and lymphocytes. In advanced cases disrupted and broken hair follicles are surrounded by granulomatous inflammation, perifollicular abscess formation and fibrosis. The dermal fibrosis resembles collagen in scar formation and differs from that seen in true keloids.

MANAGEMENT

The choice of therapeutic modality largely depends on the clinical stage of disease. Papulopustular lesions may respond to topical therapies, intralesional therapy, or physical modalities, while larger plaques and tumors generally require surgical excision. Topical therapies include corticosteroids, antibiotics, retinoids, and immune modulators, used as monotherapy or in combination.

Class I or II topical corticosteroids applied twice daily may be efficacious and a recent open-label study found topical clobetasol propionate foam to be effective in improving mild-to-moderate lesions. When pustules or other evidence of infection are present, topical clindamycin or erythromycin is warranted to decrease inflammation. Combination antibiotic and corticosteroid preparations are quite popular. Imiquimod cream prescribed daily for five consecutive days for a total of eight weeks has been successful in a few patients. (11)

For mild-to-moderate cases not responsive to topical therapy, intralesional corticosteroids, usually triamcinolone acetonide, may be injected at three- to four-week intervals. Laser therapy (carbon dioxide or neodymium-doped yttrium aluminium garnet) and cryotherapy have also been proven successful in some patients.

The late lesions with discharging keloidal masses are refractory to topical medication and intralesional injections of Triamcinolone. Surgical excision is the mainstay in proper management of these late and advanced cases as seen in both of our cases. Several options are proposed like staged excision, excision with primary closure, excision and leave the raw area for secondary healing and excision followed by primary skin grafting. Regardless of the type of closure chosen, the affected tissue must be excised to a depth extending at least to the base of the hair follicles in order to prevent recurrences.(12)

Different modalities were described by different authors for excision like use of laser and cryo but the electrosurgical excision is quite convenient, with less of bleeding and ensuring complete excision without the possibility of local recurrence.Each method has its own advantages and disadvantages.(13)

Our experience in these Four cases showed electrosurgical excision with primary skin grafting of the raw area gives excellent results and satisfaction to the patients, as seen by our patients followed for 1 to 2 years. Gloster opined excision with skin grafting is generally an inferior option as the cosmetic outcome is poor. Split-thickness skin grafts are typically atrophic, depressed, and do not match the surrounding skin in color, texture, or thickness. (14)

Excision and primary layered suture is not possible in such extensive defects, since there is no redundant skin over the nape of the neck and forceful closure may result in dehiscence, restricted movements of the neck and recurrence. [15]

Excision followed by secondary healing is troublesome to the patients, takes very long time for several months and more expensive and inconvenient and has to be away from regular work for long time. Nashida et al reported excision with secondary intention healing is an effective option in the treatment of extensive AKN that fails to respond to medical treatment or minor surgical intervention. Although the average time for wound healing is 6 to 8 weeks, this approach offers good cosmetic results as the wound often retracts to form a scar that is much smaller and flatter than the original one. Cosmesis is further improved when the excision is a horizontal ellipse of the posterior hairline and posterior aspect of the scalp, resulting in a more natural-appearing hairline. In addition, recurrences may be fewer with secondary intention healing.[16].

Staged excision at intervals is not recommended in such extensive lesions with infection and discharge. Considering all the pros and cons of these alternative methods, we are of the opinion,electrosurgical excision followed by primary skin grafting gives very good results with short recovery time,pain and suffering and less cost of treatment and in all our four cases the patients are 100% satisfied without any cosmetic problem who were followed for more than 2 years postoperatively.

Adjuvant therapy is not routinely recommended following surgical excision of AKN, but can be useful if an elevated scar develops after complete healing. In these two cases, flat scar was present following electrosurgical excision, negating a need for adjuvant therapy.Minor recurrences are generally due to inadequate removal of hair follicles within the affected tissue. [17]

Tissue expansion is a valuable procedure in large lesions to avoid skin grafting.We should properly select the suitable case for success of the procedure since there is chronically infected tissues with gross fibrosis(18).In selected cases this procedure gives good result even though it takes more time and more expensive.

CONCLUSIONS

Four cases were treated by this technique in extensive cases of Acme Keloidalis Nuchae in the years 2012,2014,2019 and 2020 and all the cases were well documented histologically and followed from one year to 9 years.All gave excellent results without recurrence and patients were extremely happy.Out of the four patients the first operated two patients are brothers from the same family and we have to further probe the possibility of hereditary factor in the causation of this condition. Both are dark skinned and obese. In all the four cases we found the following advantages for complete excision and primary skin grafting.

1) Electro surgical cautery was used for excision thus ensuring complete excision up to subcutaneous level reducing the chances of recurrence.

2) The blood loss is minimal with less than 200 ml in both the cases and operation could be completed in less than 45 minutes.

3) Comfortable postoperative period, early recovery with short hospital stay (Both are discharged within one week).

4) They could return back to their duties within 2 weeks and productive man hours are saved since both are employees.

5) They do not have any cosmetic problem as seen from all the patients when they came for follow up regularly.

6) Even though excision with subsequent skin grafting has also been described in the treatment of AKN, usual objections are that the skin grafts are often atrophic, does not match surrounding skin in color, texture or thickness and that the graft site is significantly depressed below the level of the surrounding skin.

But our experiences in these four cases revealed that the color match is not a problem, since they are dark skinned, medium thickness skin graft, there is not much of difference from the surrounding skin and at the site in the upper part of the neck with hair covering, and they did not feel any cosmetic problem. The advantages outweigh any minor disadvantages. The postop results shown in the figure (8) and the highly satisfactory levels to the patients ranging from 9 yrs,7,yrs,1yr and 7 months postop, shows the excellent outcomes of this procedure in selected cases.

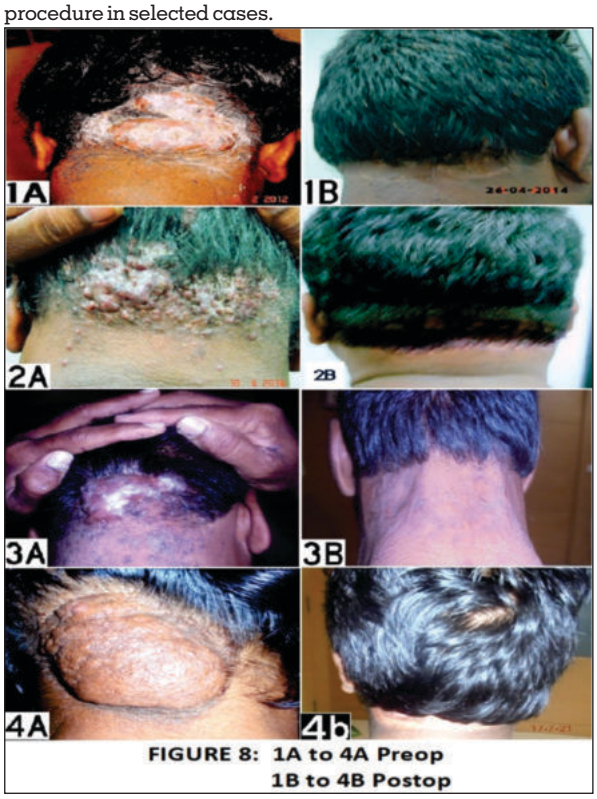

Figure-(8) All 4 cases pre & postop 1A,B TO 4A,B

ACKNOWLEDGEMENTS:

I acknowledge with thanks the help extended by Department of Pathology, NRI Medical College, Chinakakani, for histopathological study with first patient, who was operated in that institute by the author while working at that time.Dept of Pathology,ASRAM for excellent histopathology study and diagnosis &,Dept of Anaesthesiology for excellent anesthetic management in 3 cases operated at ASRAM medical college hospital.

REFERENCES:

1. Kaposi M. [Ueber die sogennante framboesia und mehrere andere arten von papillaren neubildungen der haut.] Arch Dermatol Syph. 1869; 1:382–423.
2. Cosman B, Wolff M. Acne keloidalis. Plast Reconstr Surg.1972; 50:25–30.
3. Ogunbiyi A, George A. Acne keloidalis in females: case report and review of literature. J Natl Med Assoc. 2005; 97:736–738.
4. Dinehart SM, Tanner L, Mallory S. Acne keloidalis in women. Cutis. 1989; 44:250–2.
5. Kelly AP. Pseudofolliculits barbae and acne keloidalis nuchae. Dermatol Clin. 2003; 21:645–653.
6. Salami T, Omeife H, Samuel S. Prevalence of acne keloidalis nuchae in Nigerians. Int J Dermatol. 2007; 46:482–4.
7. Halder R. Hair and scalp disorders in blacks. Cutis. 1983; 32:378–380.
8. Verma SB, Wollina U. Acne keloidalis nuchae: another cutaneous symptom of metabolic syndrome, truncal obesity, and impending/overt diabetes mellitus? Am J Clin Dermatol. 2010; 11(6):433–6.
9. Azurdia RM, Graham RM, Weismann K, Guerin DM, Parslew R. Acne keloidalis in Caucasian patients on cyclosporine following organ transplantation. Br J Dermatol. 2000; 143:465–7.
10. Carnero L, Silvestre JF, Guijarro J, Albares MP, Botella R. Nuchal acne keloidalis associated with cyclosporine. Br J Dermatol. 2001; 144:429–430.
11. Vasily DB, Breen PC, Miller F. Acne keloidalis nuchae: report and treatment of a severe case. J Dermatol Surg Oncol. 1979; 5:228–230.
12. VD, Young CM, Haverstock CL, Carroll CL, Feldman SR. An open label study of clobetasol propionate 0.05% and betamethasone valerate 0.12% foams in the treatment of mild-to-moderate acne keloidalis. Cutis. 2005; 75:317–321.
13. Kanthak FF, Cullen ML. Skin graft in the treatment of chronic furunculosis of the posterior surface of the neck (folliculitis keloidalis). South Med J. 1951; 49:1154–7.
14. Gloster HM., Jr The surgical management of extensive cases of acne keloidalis nuchae. Arch Dermatol. 2000; 136:1376–9.
15. Glenn MJ, Bennet RG, Kelly AP. Acne keloidalis nuchae: treatment with excision and second-intention healing. J Am Acad Dermatol. 1995; 33:243–6.
16. Nashida Beckett, Christina Lawson, George Cohen. Electrosurgical Excision of Acne Keloidalis Nuchae with Secondary Intention Healing. J Clin Aesthet Dermatol. Jan 2011; 4(1): 36–9.
17. Bajaj V, Langtry JAA. Surgical excision of acne keloidalis nuchae with secondary intention healing. Clin and Exper Dermatol. 2007; 33:53–5.
18. Gutierrez-GomezC,valdez-Diaz B.Treatment of acne keloidalis nuchae.cir Plast.2020;30(3):156-159.