VOLUME - 10, ISSUE - 11, NOVEMBER - 2021 • PRINT ISSN No. 2277 - 8160 • DOI : 10.36106/gjra

Original Research Paper

Obstetrics & Gynaecology

ROLE OF HYSTEROSCOPY IN EVALUATION OF POST MENOPAUSAL BLEEDING

Dr. K Aravinda* Associate professor , Dept.of.OBG, Viswabharathi medical college. *Corresponding Author

Dr. Vaheda Professor, Dept.Of.Obg, Viswabharathi Medical College.

ABSTRACT

Aim: The present study was carried out to evaluate role of hysteroscopy in evaluating the causes of bleeding in women with postmenopausal bleeding and to determine their prevalence in our population. **Methods:** This was a prospective observation study, comprising of total number of 100 postmenopausal women attending gynae OPD at department of obstetrics and gynecology, at viswabharathi medical college . The data obtained for the purpose of study was fed into computer using Microsoft excel 2017 software. **Results:** A total of 100 women with complaints of postmenopausal bleeding were enrolled in the study. Maximum number of women had achieved menopause between age 45 and 52 years. On hysteroscopy 10 women had benign cervical polyps, 30 women had benign endometrial polyps,fibroids were detected in 10 members, atrophic endometrium in 20 members and diffuse polys and fluffy endometrium were found in 30 members. **Conclusion:** Hysteroscopy is safe and effective for detecting endometrial pathologies in patients with PMB.

KEYWORDS : Post menopausal bleeding, menopause, Endometrial malignancy, Hysteroscopy.

INTRODUCTION

Menopause is defined according to WHO as the permanent cessation of menstruation resulting from the loss of ovarian follicular activity.[1] Bleeding after menopause is an abnormality and is termed as postmenopausal bleeding (PMB). It is defined as bleeding that occurs from the genital tract after one year of amenorrhoea, in a woman who is not receiving hormone replacement therapy (HRT).[2] Postmenstrual bleeding is a common complaint among patients visiting a gynecologists and comprises nearly 5-10% of total patient turnover to a gynaecology clinic.[3]

Postmenopausal bleeding may be caused by the following:

- hormone (oestrogen) therapy
- atrophy of the vagina or uterus
- uterine or cervical polyps
- endometrial hyperplasia
- cancer of the uterus, cervix, or vagina

Vaginal bleeding in post-menopausal women is an alarming symptom. It is estimated that postmenopausal women with vaginal bleeding have a risk of endometrial carcinoma of approximately 10%.[4]

Dilatation and curettage (D and C) was the only option available in the past for evaluating a case of PMB. However focal lesions may be missed on D and C as it is a blind procedure.

With the introduction of hysteroscopy, the chances of getting a correct diagnosis have enhanced tremendously. Hysteroscopy enables to directly visualize the uterine cavity completely and in case of any abnormal visualization, the representative tissue can be collected for histopathological examination.

Hysteroscopy is an easy to perform office procedure that can be done in a short period of time without causing discomfort to patients and their attendants. It is a widely recognized diagnostic modality in the evaluation of abnormal uterine bleeding in premenopausal, perimenopausal and post-menopausal cases with high accuracy. It is highly accurate for diagnosing endouterine lesions such as polyps, submucous myomas, endometrial adenocarcinoma and hyperplasia, i.e., the conditions associated with postmenopausal bleeding.

Considering the high accuracy of hysteroscopy in evaluation of postmenopausal bleeding, the present study was carried out with an aim to evaluate hysteroscopic findings in women with postmenopausal bleeding in order to assess the various causes of PMB and to determine their prevalence in our population. With Hysteroscopy, Detailed evaluation of enocervical and endometrial cavity lesions can be done. Biopsy can be taken in the same sitting from suspicious areas.

AIM:

The aim of this study is to evaluate the efficacy of hysteroscopy in women with postmenopausal bleeding; and to detect intracavitary abnormalities in women with postmenopausal bleeding which are easily missed out in D&C.

Methods:

This was a prospective study conducted in Department of Obstetrics and Gynecology at Viswabharathi Medical College for 1 year (1 December 2017-30 November 2018). Number of cases were 100.

Inclusion Criteria

Postmenopausal women with complaint of per vaginal bleeding.

Exclusion Criteria

Diagnosed cases of endometrial cancer, cervical cancer
Patients with infections(uti,vaginal and cervical infections)
Patients with abnormal pap smears
Patients not willing for study.
Women on any kind of harmonal pills

All postmenopausal women with PMB were included in the study after taking consent. Demographic data, detailed history of patients were noted.

Detailed examination was done Hysteroscopy was performed routinely in all patients under local anaesthesia with 4mm, 30 degree rigid telescope. Cervical canal and uterine cavity were explored with hysteroscope. Curettage was done, and endometrial tissue was sent for histopathological examination.

RESULTS :

Out of the 100 patients evaluated the age distribution is tabulated below

Table :1

Age range	number	percentage
45-50	10	10
50-55	40	40
55-60	30	30
60-70	20	20

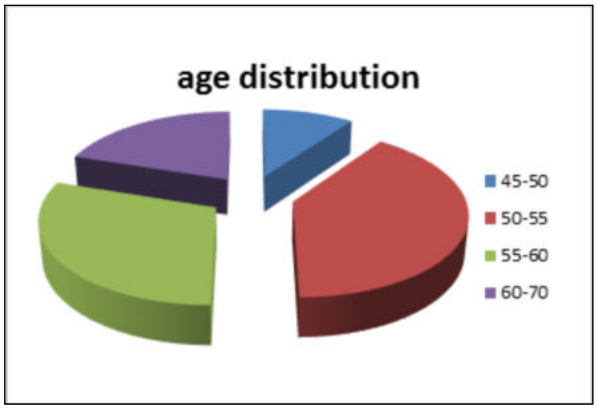

Figure :1 Pie Diagram Showing Age Distribution

Table 2 Hysteroscopy Findings

Hysteroscopic findings	Number	Percentage
Cervical polyp benign	10	10
Benign endometrial polyp	30	30
Fibroids	10	10
Atrophic endometrium	20	20
Diffuse polyp	30	30

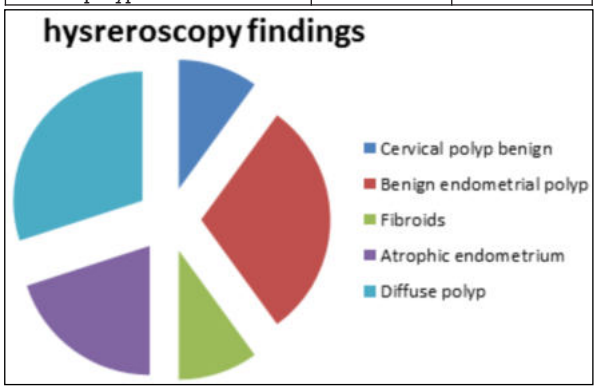

Figure: Pie Diagram Showing Hysteroscopic Findings

Table 3 Showing Histopathological Findings

HPE findings	Number	Percentage
Benign polyp	25	25
Leomyoma	10	10
Atrophic endometrium	15	15
Secretory endometrium	1	1
Proliferative endometrium	9	9
Simple hyperplasia without atypia	6	6
Simple hyperplasia with atypia	4	4
Complex hyperplasia without atypia	4	4
complex hyperplasia with atypia	6	6
Malignancy	20	20

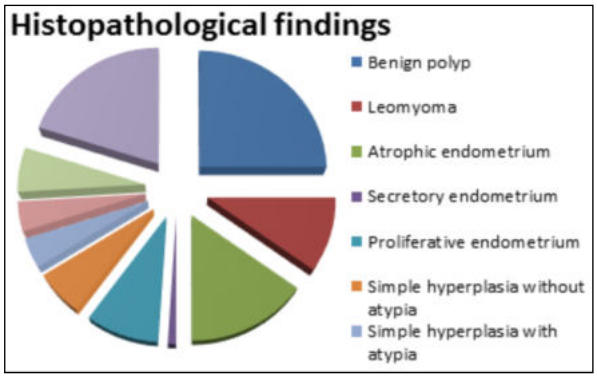

Figure :3 Pie Diagram Showing Histophathological Findings

DISCUSSION :

Age of patients with postmenopausal bleeding in the current study ranged between 45years and 70 years with a mean age of 55.96 years (Table 1). This age is much lower than the mean age 64 year by Kaur M et al and 63.6 year by Dawood NS et al.[5,6]

Table 4. Hysteroscopic Findings In Postmenopausal Bleeding Cases In Some Of The Contemporary Studies.

Author (year), location	No. of cases	characteristics	Hysteroscopic findings
Ribero [7]et al, Brazil	510	mean age 61.1±2.0 years	Polyps (67.5%), cancer/hyperplasia (8.7%), myomas (7.3%), normal (4.5%), others (11.9%)
Tandulwadkar [8]et al, India	60	81.6% >50 years	Atrophy (65%), hyperplasia (6.67%), polyp (11.7%), submucous fibroid (1.7%), endometrial carcinoma (11.7%)
Pop-Trajkoviü-Diniü, [9] Serbia	148	mean age 69 years	Normal (26.2%), endometrial polyp (29.6%), cervical polyp (16.5%), submucous myoma (5.51%), endometrial hyperplasia (7.58%), atrophy (12.5%), endometrial cancer (2.06%)
Gupta [10] et al, India	70	50 peri, 20 postmenopausal	Normal (42.85%), endometrial polyp (11%), fibroid (27.14%), endometrial hyperplasia (20%)
Sarvi [11]et al, Turkey	110	mean age 57 years, 67-AUB, 43 thickened endometrium	Normal (15.5%), polyp (48.2%), myoma (18.2%), hyperplasia (14.5%), carcinoma (3.6%)
Sharma and Tiwari, [12]Nepal	50	Peri and post-menopausal aged 45 to 64 years	Normal (34%), hyperplastic (36%), atrophy (18%), endometrial polyp (6%), cervical polyp (2%), endometrial carcinoma (4%)
Junnare [13] et al, India	98	87 aged <60 years	Normal (36%), atrophy (19%), hyperplastic (30%), endometrial polyp (13%), posterior wall growth (1%)
Sudhir Mansingh [14] et al,india	50	mean age 58.42 years	Unhealthy cervix/normal (14%), atrophy (16%), polyp (50%), fibroid/ myoma (10%), hyperplasia (2%), endometrial cancer (6%), degenerative changes not otherwise classified (2%)
Present study	100	Mean age 55.96 years	Benign cervical polyp (10%),benign endometrial polyp (30%) fibroids (10%), atrophic endometrium (20%), diffuse polyps/ Fluffy endometrium (30%).

As such after ruling out different physiological and hormonal reasons, and a suspicious TVS finding, the focus was mainly towards finding out a pathological cause of postmenopausal bleeding. For the screening hysteroscopy was done. On hysteroscopy Benign cervical polyp (10%),benign endometrial polyp (30%) fibroids (10%), atrophic endometrium (20%), diffuse polyps/ Fluffy endometrium (30%). Hysteroscopic findings in different case series have shown wide diversity. Table 4 shows

the hysteroscopic findings in postmenopausal bleeding cases in some of the contemporary studies.

An overview of Table 4 above shows a dominance of normal, atrophic and polyps in almost all the series. The rate of detection of endometrial carcinoma in different series ranges from 0% (Gupta et al) to 11.7% (Tandulwadkar et al) In present series, it was 20%. In present study, rate of fibroid/myoma detection was only 10%, however, some other workers detected it to be much higher, viz. Sarvi et al, detected it in 18.2% cases while Gupta et al, detected in 27.14%. However, some other workers like Sharma and Tiwari and Junnare et al, did not report it in any of their cases. Similarly, hyperplasia was reported in only 20% of this study cases, whereas Junnare et al, found it in 30% of their cases. The wide diversity in different pathologies in different studies could be owing to diversity in samples as well as sample size. Given a number of endometrial pathologies involved in postmenopausal bleeding, series with smaller sample size could have incidental rather than actual proportional representation.

In present study, final diagnosis was done by clinic-histopathological correlation the hystopathological findings were benign polyp 25%, leiomyoma 10%,atrophic endometrium 15%,secretory endometrium 1%, proliferative endometrium 9%, simple hyperplasia without atypia 6%, simple hyperplasia with atypia 4%, complex hyperplasia without atypia4%, complex hyper plasia with atypia 6 %, endometrial carcinoma 20%.

However, Junnare et al, in their study found a major change in proportion of hyperplasia cases which were diagnosed in 30% cases hysteroscopically but were finally confirmed in only 11% cases. However, Tandulwadkar et al, showed excellent correlation between hysteroscopy and histopathology. Pop-Trajkoviü-Diniü on the other hand, found underdiagnosis of normal endometrium and endometrial polyp by hysteroscopy but an overdiagnosis for hyperplasia and atrophy as compared to histopathology. Sarvi et al, on the other hand found overdiagnosis of carcinoma in 2 out of 3 cases which were proven to be complex or atypical hyperplasia on histopathology. Although hysteroscopy is generally comparable to the final diagnosis in most of the cases, however, the advantage of the hysteroscopy lies in the fact that it allows endometrial biopsy through which the diagnosis could be confirmed histopathologically.

CONCLUSION

Post-menopausal bleeding is one of the most common reasons for visit to a gynaecologist by a woman who has attained menopause.

Hysteroscopy is an office procedure, that can be performed as a day care procedure, provides a better view of various structural pathologies and in case of a doubtful pathology helps in obtaining endometrial sample to confirm the diagnosis.. Along with endometrial biopsy it is considered to be highly accurate in identification of endometrial neoplasia and its precursors. It has been considered to be the method of choice for evaluation of women with postmenopausal bleeding especially those aged 45 years or above.

The present study was carried out to evaluate hysteroscopic findings in women with post-menopausal bleeding in order to ascertain various causes of PMB and to determine their prevalence in our population.

Final diagnosis was established with the help of clinic-histopathological work-up. The findings of present study suggested that hysteroscopy has a useful role in evaluation of postmenopausal bleeding especially in the diagnosis of polyps and fibroids and endometrial carcinoma and premalignant lesions.

REFERENCES

1. Research on the menopause in the 1990s: report of a WHO scientific group. WHO Tech Report Series. 1996;866:1-107.
2. Brand AH. The woman with postmenopausal bleeding. Aus Fam Physic. 2007;36(3):116.
3. Astrup K, Olivarius NDF. Frequency of spontaneously occurring postmenopausal bleeding in the general population. Acta Obstet Gynaecol Scand. 2004;83:203-7
4. Smith-Bindman R, Kerlikowske K, Feldstein VA, Subak L, Scheidler J, Segal M, et al. Endovaginal ultrasound to exclude endometrial cancer and other endometrial abnormalities. JAMA. 1998;280(17):1510-7.
5. Kaur M, Singh R, Sharma M. Endovaginal sonographic evaluation of postmenopausal uterine bleeding. J Clin Diagn Res. 2010;4(2):2175-82.
6. Dawood NS, Peter K, Ibrar F, Dawood A. Postmenopausal bleeding: causes and risk of genital tract malignancy. J Ayub Med Coll Abbottabad. 2010;22(2):117-20.
7. Ribeiro CT, Rosa-E-Silva JC, Silva-de-Sá MF, Rosa-E-Silva AC, Poli Neto OB, Candido Dos Reis FJ, et al. Hysteroscopy as a standard procedure for assessing endometrial lesions among postmenopausal women. Sao Paulo Med J. 2007;125:338-42.
8. Tandulwadkar S, Deshmukh P, Lodha P, Agarwal B. Hysteroscopy in postmenopausal bleeding. J Gynecol Endosc Surg. 2009;1(2):89-93.
9. Pop-Trajkoviü-Dinic S, Ljubic A, Kopitovic V, Antic V, Stamenovic S, Pjevic AT. The role of hysteroscopy in diagnosis and treatment of postmenopausal bleeding. Vojnosanit Pregl. 2013;70(8):747-50.
10. Gupta S, Sanyal P, Dasgupta S, Sarkar D, Das T, Mandal DD, et al. The ideal investigative method for evaluation of abnormal uterine bleeding in peri and post-menopausal women. J Evolut Med Dent Sci. 2015;4(17):2878-84.
11. Sarvi F, Alleyassin A, Aghahosseini M, Ghasemi M, Gity S. Hysteroscopy: a necessary method for detecting uterine pathologies in post-menopausal women with abnormal uterine bleeding or increased endometrial thickness. Turk J Obstet Gynecol. 2016;13(4):183-8.
12. Sharma J, Tiwari S. Hysteroscopy in abnormal uterine bleeding vs ultrasonography and histopathology report in perimenopausal and postmenopausal women. J Nepal Med Assoc. 2016;55(203):26-8.
13. Junnare KK, Desai GJ, Shekhawat GS. Hysteroscopy: an effective tool in post-menopausal bleeding. Int J Reprod Contracept Obstet Gynecol. 2019;8(1):159-64.
14. Mansingh S et al., Hysteroscopic evaluation of postmenopausal bleeding patients and its correlation with histopathological examination, Int J Reprod Contracept Obstet Gynecol. 2020 Aug;9(8):3215-3222.