VOLUME - 11, ISSUE - 08, AUGUST - 2022 • PRINT ISSN No. 2277 - 8160 • DOI : 10.36106/gjra

Original Research Paper

Pathology

BONE MARROW PLASMACYTOSIS- REACTIVE OR MALIGNANT? A DIAGNOSTIC CHALLENGE TO A NOVICE PATHOLOGIST.

Jyoti Mishra	Associate Professor, Department of Pathology, School of Medical Sciences and Research, Sharda University, Greater Noida.
Salony Mittal	Associate Professor, Department of Pathology, School of Medical Sciences and Research, Sharda University, Greater Noida.
Vatsala Gupta	Assistant Professor, Department of Pathology, School of Medical Sciences and Research, Sharda University, Greater Noida.

ABSTRACT Plasmacytosis can be due to both reactive causes as well as monoclonal proliferation. Reactive plasmacytosis is seen in infections, malignancy, iron deficiency, megaloblastic anemia, hemolytic anemia , liver cirrhosis, Castleman's disease and streptokinase treatment. Plasmacytosis in elderly patient can be a diagnostic confusion especially in absence of one or more of hypercalcemia, Renal insufficiency, anemia and bone lesions (CRAB). We encountered a similar case of elderly person whose final diagnosis was made after thorough radiological and pathological evaluation.

KEYWORDS :

INTRODUCTION:

Bone marrow plasmacytosis can be due to both benign and malignant causes. The reactive causes[1] include infections, malignancy, iron deficiency, megaloblastic anemia, hemolytic anemia , liver cirrhosis, Castleman's disease and streptokinase treatment.

CASE:

A 60year old gentleman presented with off and on fever along with loss of appetite for 4 months. There was no significant past history, personal or family history. His complete blood count revealed moderate degree of normocytic normochromic anemia. Erythrocyte sedimentation rate was high 100mm/hr. Renal function tests revealed high blood urea nitrogen (76mg/dl) and high creatinine level (1.9mg/dl). The liver function tests were within normal limits. For further evaluation of anemia, his iron studies, Vitamin B12 and folate assays were done and were within normal limits. A provisional diagnosis of anemia of chronic disease was made. His anemia improved on transfusing 2 units of packed RBCs, but only for a couple of days. So, bone marrow aspiration was done which showed increased number of only mature plasma cells reaching upto 25% of non-erythroid nucleated cells. And many binucleate to multinucleate forms including Mott cells were seen (Figure 1). Morphological diagnosis of plasmacytosis was suggested and the complete work up for multiple myeloma was advised which included High resolution serum electrophoresis, urine electrophoresis, immunophenotyping for kappa, lambda, CD19, CD20, CD38, CD138 for plasma cells and search for CRAB lesions. The serum electrophoresis was found to be normal and the patient had no hypercalcemia and bone lesions. However, the CT whole abdomen showed a retroperitoneal mass measuring 5cm in largest dimension. Its biopsy was done and histopathology revealed malignant tumor in glandular pattern, tubules and few dispersed cells. These tumor cells were markedly pleomorphic, with vesicular nucleus, inconspicuous nucleoli, and abundant vacuolated cytoplasm. At places, signet ring like cells were seen. Fair number of bizzare cells were also noted. The surrounding stroma showed mild chronic inflammatory infiltrate. The histomorphological diagnosis of metastatic poorly differentiated adenocarcinoma was rendered. And immunohistochemical markers CK7, CK20, MUC1, MUC2, MUC5A, CDX2 were advised to search for the primary tumour. The ultrasonography of abdomen also showed a well-defined round lesion of 1.87x1.96cm in the right lobe of liver. So, the case was finally concluded to be metatstatic poorly differentiated adenocarcinoma deposit in retroperitoneum with bone marrow reactive plasmacytosis.

DISCUSSION:

Reactive plasmacytosis[2] (RP) can be caused by infections[3,4,5], autoimmune conditions, anaemias. It may also present as a paraneoplastic syndrome associated with Hodgkin's lymphoma, Non-Hodgkin's lymphomas, epithelial malignancies and in post chemotherapy patients. This case showed increased number of plasma cells (25%) with presence of binucleate to multinucleate forms including Mott cells. The serum electrophoresis report was negative for plasma cell dyscrasia. This caused a great diagnostic dilemma. Furthermore, the presence of retroperitoneal mass also added to the difficulty. It was only after the histopathology of retroperitoneal mass, the bone marrow plasmacytosis could be explained. In RP, BM plasma cells constitute 10%–20% of marrow nucleated cells and may reach upto 50%.This may cause a diagnostic dilemma especially in elderly patients. Thus, it is essential to differentiate RP from plasma cell dyscrasias. Through this case we intend to highlight the fact that bone marrow plasmacytosis can also be due to non-hematological malignancies especially carcinomas.

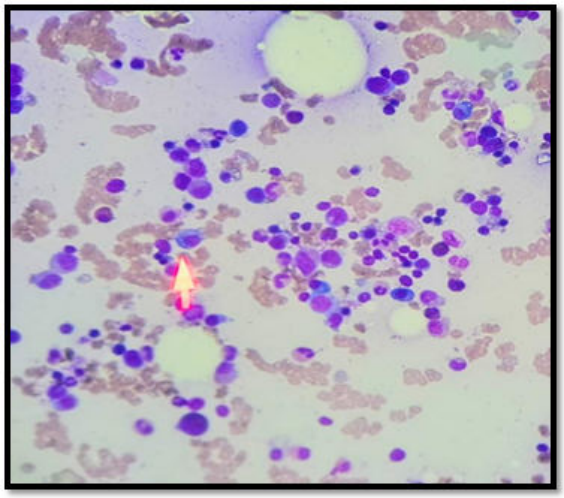

Figure 1: Leishmans stained bone marrow aspirate smears (10x) shows many mature plasma cells, the arrow indicates Mott cells (plasma cells with cytoplasmic vacuoles containing immunoglobulins)

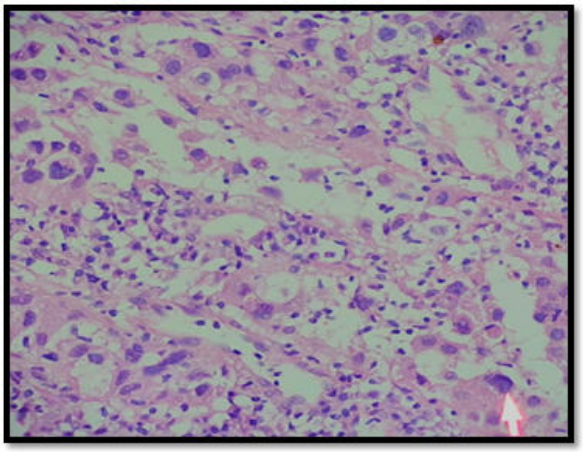

Figure 2: H&E stained sections (40x) showing atypical to bizzare cells indicated by arrow, forming vague glandular structures in adenocarcinoma

REFERENCES:

1. Batool S, Misra S, Kumar V, Ahuja A, Marwah S, Baweja G, et al. Reactive bone marrow plasmacytosis: A common denominator with diverse etiology. Hamdan Med J 2022;15:33-8.
2. Batdorf B, Kroft S, Olteanu H, Harrington A. Reactive Bone marrow plasmacytosis: An update for the modern era. Am J Clin Pathol 2014;142:A102.
3. Thai KT, Wismeijer JA, Zumpolle C, de Jong MD, Kersten MJ, de Vries PJ. High incidence of peripheral blood plasmacytosis in patients with dengue virus infection. Clin Microbiol Infect 2011;17:1823-8.
4. Wada T, Maeba H, Ikawa Y, Hashida Y, Okumura A, Shibata F, et al. Reactive peripheral blood plasmacytosis in a patient with acute hepatitis A. Int J Hematol 2007;85:191-4.
5. Zhang J, Yan X, Li Y, Gao R, Wang P, Mo W. Reactive plasmacytosis mimicking multiple myeloma associated with SFTS virus infection: Areport of two cases and literature review. BMC Infect Dis 2018;18:528.