VOLUME - 11, ISSUE - 08, AUGUST - 2022 • PRINT ISSN No. 2277 - 8160 • DOI : 10.36106/gjra

Original Research Paper

Cardiology

RIGHT ATRIAL MASSES – A SERIES OF THREE CASES

Shilpa Jayaprakash	MD,DM, Associate Professor,Department of Cardiology,Sri Jayadeva Institute of Cardiovascular Sciences and Research, Bangalore.
Varun Marimuthu	MD,DM, Assistant Professor, Department of Cardiology, Sri Jayadeva Institute of Cardiovascular Sciences and Research, Bangalore.
Balaraju Doddaiah*	MD,DNB, Associate Professor, Department of Cardiology, Sri Jayadeva Institute of Cardiovascular Sciences and Research, Bangalore. *Corresponding Author
Prabhavathi Bhat	MD, DM, Professor, Department of Cardiology, Sri Jayadeva Institute of Cardiovascular Sciences and Research, Bangalore.
Shankar Somanna	MD, DM, Professor, Department of Cardiology, Sri Jayadeva Institute of Cardiovascular Sciences and Research, Bangalore.
Manjunath Cholenahalli Nanjappa	MD,DM, Director, Sri Jayadeva Institute of Cardiovascular Sciences and Research, Bangalore.

ABSTRACT Cardiac masses are rare, and they pose an interesting diagnostic and therapeutic challenge. The differentials vary from tumours – both primary and secondary, thrombus, infective vegetations, artifacts to cysts. They can present with obstructive symptoms, embolisation, constitutional symptoms or pericardial effusions. Multimodality imaging with echocardiogram, computed tomography (CT) and magnetic resonance imaging (MRI) help in diagnosis. Complete surgical resection is often the modality of choice in cases of tumours. Thrombolysis or surgical extraction is suitable in cases of thrombus in the right heart.

KEYWORDS : Myxoma, Sarcoma, Pulmonary embolism, Pericardial effusion, Thrombolytic therapy

INTRODUCTION

Cardiac masses are rare, and they pose significant clinical and therapeutic challenges. The differential diagnosis ranges from tumours, thrombus, valvular vegetations, cysts, to imaging artifacts. Often detected incidentally in asymptomatic patients, they become known when patients develop symptoms due to the underlying disease. These masses can cause hemodynamic consequences due to obstruction of cardiac chambers, can cause embolism, have positional dyspnea, arrythmias, pericardial effusion or have constitutional symptoms. Incidence of primary cardiac tumours is 1:2000, on autopsy studies (1). Most are benign and few have malignant potential. Secondary cardiac tumours are far more common with an incidence of 1:100 (1). Although they can arise from any cardiac chamber, masses in the right atrium (RA) are rarer and have heterogenous differentials. We describe three such cases of RA masses in this series and discuss the presentation and emergent management.

Case 1

A 60 year old female, was evaluated for progressive dyspnea over six months duration. She had bipedal edema and intermittent fever. On examination, she was hemodynamically stable. She had right sided third heart sound. She was started on intravenous diuretics and oxygen and was stabilised. Chest Xray (CXR) showed cardiomegaly and right pleural effusion. Transthoracic echocardiogram (TTE) showed dilated RA and right ventricle (RV) with a calcific tricuspid valve (TV) and severe tricuspid regurgitation (TR). There was a calcified mobile mass attached to the interatrial septum (IAS) which was prolapsing to the RV causing obstruction in diastole. (Figure 1). While the TTE was classical of a RA myxoma, Cardiac computed tomography (CT) and cardiac magnetic resonance imaging (MRI) were performed, and that confirmed the mass as a calcified RA myxoma, with extent from the RA to the suprahepatic inferior vena cava (IVC) inferiorly and into the RV through the TV anteriorly. Coronary angiogram (CAG) was normal, but cinefluoroscopic imaging during the CAG revealed the calcific mass in the RA to its full extent (Figure 1). She was referred to surgery and the myxoma was excised completely, and the TV was repaired. She recovered and is on follow up.

Case 2

A 50 year old gentleman presented with exertional shortness of breath worsening for one month. He had no prior cardiovascular comorbidities and was otherwise in good health. On examination, he was tachycardic, had borderline hemodynamics but cardiac examination was unrevealing. ECG had low voltage complexes. TTE was performed and it showed a large pericardial effusion with tamponade. Emergency pericardiocentesis was performed via the subxiphoid approach and 500ml of hemorrhagic fluid was aspirated. Subsequently, once he stabilised, TTE and TEE was performed. Both showed a large, heterogenous mass in the RA, almost filling the cavity. The IVC and the superior vena cava (SVC) were normal, and no filling defects were seen. Contrast CT of the chest revealed extensive metastatic involvement of the lung parenchyma, a result of tumour seeding the downstream pulmonary tissues. The mass was surgically resected, and biopsy was suggestive of a spindle cell sarcoma (Figure 2). The patient succumbed to the advanced metastatic malignancy soon after discharge.

Case 3

A 55 year old lady presented to our outpatient department with shortness of breath, which was rapidly progressing over the last two weeks. She was tachycardic at the time of evaluation. TTE showed dilated RA, RV, and moderate TR. There were multiple masses attached to the IAS in the RA (Figure 3). The pulmonary arteries were dilated but had no filling defects. CT pulmonary angiogram was suggestive of pulmonary

embolism. Due to the multiple masses in the RA, the patient was started on thrombolysis with streptokinase (STK) for 24 hours and later heparin was continued. Workup for malignancy was negative and pelvic and lower limb venous doppler was normal. Hypercoagulopathy workup was done, and antiphospholipid syndrome (APLA) was confirmed. She was continued on oral anticoagulation and made a full recovery. Follow up TTE after 3 months showed complete resolution of the RA mass confirming it to be a thrombus with normal pulmonary artery (PA) pressures.

DISCUSSION

Among the cardiac tumours in adults, myxomas are the commonest and they frequently arise from the LA. Around 15% of myxomas arise from the RA, and familial syndromes often lead to myxomas arising from multiple sites (2). The myxomas are benign but require treatment as they cause hemodynamic symptoms due to inflow or outflow obstruction to cardiac chambers. Tumours of the right heart tend to cause obstruction of venous blood flow and can cause symptoms of right heart failure such as pedal edema, ascites, congestive hepatomegaly and can also lead to pulmonary embolism (PE).

In case 1, the patient had florid symptoms of right heart failure and there was no evidence of PE on CT. The tumour also had compromised the tricuspid valve and was causing significant tricuspid regurgitation. Myxomas can also invade myocardium and can cause arrythmias, pericardial effusion and ventricular dysfunction (3). MRI did not reveal any such infiltration. Cinefluoroscopic imaging was fascinating in this patient as it revealed a stony calcific tumoral mass in the right atrium extending into the IVC. Treatment is with complete, prompt surgical excision of the tumour as there is a risk of embolization or sudden death (4). The results of surgery are very good with a mortality rate of 5% (5). Recurrent and multicentric myxomas may require cardiac transplantation. Post operatively patients can have recurrence or development of new lesions (1). Although our patient had a successful cardiac outcome, she is under follow up for recurrence and worsening of right ventricular failure post tricuspid valve repair. Recurrence is common with multicentric and familial tumours.

In case 2, the patient was diagnosed with a spindle cell sarcoma. Primary malignant tumours of the heart arise from the mesenchymal structures, are quite rare and often soft tissue sarcomas. The common malignant neoplasms of the heart are angiosarcomas, rhabdomyosarcoma, fibrosarcoma, osteosarcoma and fibrous histiocytoma. While metastatic sarcomas are common in the right side of the heart due to the slow venous circulation, primary sarcomas are common on the left side (6). Cardiac sarcomas are extremely aggressive and behave poorly, and are often diagnosed late, when patients are in extremis. Complete resection or maximal debulking followed by chemotherapy have been tried in some patients, but inevitably the patients succumb soon after diagnosis (4,7). Spindle cell sarcoma is a rare primary malignancy of the heart, and patients in previous reports had grave outcomes (8,9).

In case 3, the patient had a thrombus in transit (TIT) to the pulmonary circulation from the right heart, and the thrombus was seen as multiple filling effects within the RA. TIT forms in the lower extremities and pelvic veins and invariably cause PE. TITs are classified into three types – Type A which has a long and worm like appearance, Type B is ovoid and forms within the cardiac chambers and Type C shares its morphology with types A and B (10). Our patient had a Type B RA clot. Controversy continues as to how they should be managed – surgical extraction, thrombolysis, or anticoagulation with heparin (11). In a retrospective analysis of 177 TIT cases by Rose and colleagues, the mortality rates with no therapy, anticoagulation, surgical extraction and thrombolysis respectively were 100%, 28.6%, 23.8% and 11.3% (12) with an overall mortality rate of 27.1% for all cases. The decision on treatment should be individualised. Vacuum assisted transcatheter clot extraction by newer systems like the Penumbra (Penumbra Inc, Alameda, USA) hold great promise in managing TIT, but cost and availability are major barriers (13). We treat many PE and patients with TIT at our institute with STK and our results are very satisfactory.

CONCLUSION

RA masses have heterogenous differentials and can have variable extent in the RA, often involving the TV and the IVC. Right heart failure can be florid, and the masses can interfere with right ventricular filling or cause PE. ECHO, CT, and MRI are essential for diagnosis, and fluoroscopy can identify calcific tumours. Early excision in cases of masses and systemic thrombolysis in cases of right heart thrombi can avoid right ventricular dysfunction and can portend a better prognosis.

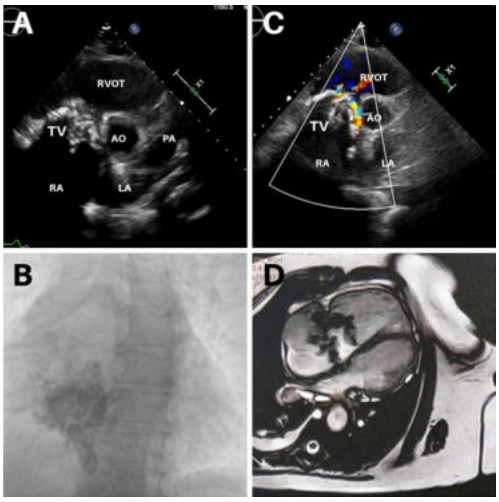

Figure 1:
A – PSAX view at the aortic valve level, showing the calcific mass and the calcific TV; B – Cinefluoroscopic image in the AP projection showing a calcific mass in the RA; C - PSAX view at the aortic valve level with colour doppler demonstrating inflow obstruction; D – CMRI image showing the calcific myxoma.

PSAX – Parasternal short axis view, TV – Tricuspid valve, RA – right atrium, LA – Left atrium, RVOT -Right ventricular outflow tract, AO – Aortic valve, PA – Pulmonary artery, AP – Anteroposterior, CMRI – Cardiac magnetic resonance imaging.

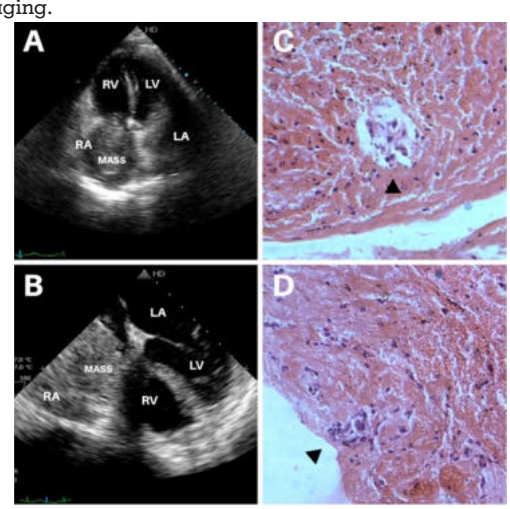

Figure 2:
A – A4C view of the heart, showing a mass filling the entire RA;

B – Mid esophageal 0^0 TEE view demonstrating the defect filling up the RA; C and D - H&E of the mass revealed it to be a spindle cell sarcoma. Black arrowhead – points to the spindle cells.

A4C – apical four chamber view, RA -Right atrium, LA – Left atrium, RV – Right ventricle, LV – Left ventricle, TEE – Transesophageal echocardiogram, H&E – Haematoxylin and Eosin stain

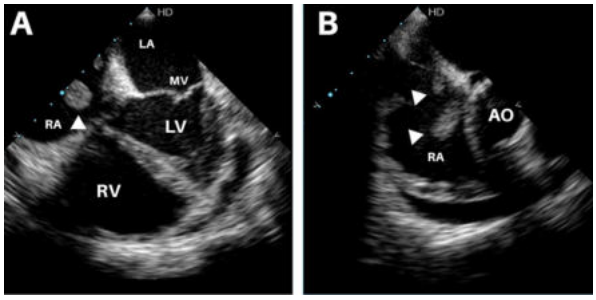

Figure 3
A - Mid esophageal 0^0 TEE view demonstrating an ovoid hyperechoic structure; B – More hyperechoic structures seen attached to the IAS in a modified mid esophageal TEE view. Black arrowhead – points to thrombus in transit in the RA.

RA -Right atrium, LA – Left atrium, RV – Right ventricle, LV – Left ventricle, AO – Aortic valve, TEE – Transesophageal echocardiogram, IAS – Interatrial septum

Consent
Written informed consent was obtained from all the patients or next of kin.

Author contributions
All authors equally contributed to this work.

Funding
None

Declaration of competing interest
No competing interests.

Acknowledgments
The authors would like to thank the patients and their relatives for consenting for publication.

REFERENCES
1. Basso C, Rizzo S, Valente M, Thiene G. Cardiac masses and tumours. Heart. 2016 Aug 1;102(15):1230–45.
2. D'Alfonso A, Catania S, Pierri MD, Matteucci SL, Rescigno G, Münch C, et al. Atrial myxoma: a 25-year single-institutional follow-up study. J Cardiovasc Med. 2008 Feb;9(2):178–81.
3. Attum AA, Johnson GS, Masri Z, Girardet R, Lansing AM. Malignant Clinical Behavior of Cardiac Myxomas and "Myxoid Imitators." Ann Thorac Surg. 1987 Aug;44(2):217–22.
4. Cina SJ, Smialek JE, Burke AP, Virmani R, Hutchins GM. Primary Cardiac Tumors Causing Sudden Death: A Review of the Literature. Am J Forensic Med Pathol. 1996 Dec;17(4):271–81.
5. Centofanti P, Rosa ED, Deorsola L, Dato GMA, Patanè F, Torre ML, et al. Primary cardiac tumors: early and late results of surgical treatment in 91 patients. Ann Thorac Surg. 1999 Oct 1;68(4):1236–41.
6. Neragi-Miandoab S, Kim J, Vlahakes GJ. Malignant Tumours of the Heart: A Review of Tumour Type, Diagnosis and Therapy. Clin Oncol. 2007 Dec 1;19(10):748–56.
7. Burke AP, Cowan D, Virmani R. Primary sarcomas of the heart. Cancer. 1992;69(2):387–95.
8. Mehra S, Ibrahim O, Moshiri M, Cahill J, Bhargava P. Spindle-cell sarcoma of the heart: A rare cause for a cardiac mass. Radiol Case Rep. 2015 Dec 7;7(4):792.
9. Park JH, Choe H, Jang W-I, Hur G. Primary pericardial spindle cell sarcoma mimicking left main coronary artery disease. Eur J Cardio-Thorac Surg Off J Eur Assoc Cardio-Thorac Surg. 2012 May;41(5):1179–81.
10. THE EUROPEAN WORKING GROUP ON ECHOCARDIOGRAPHY, KRONIK G. The European Cooperative Study on the clinical significance of right heart thrombi. Eur Heart J. 1989 Dec 1;10(12):1046–59.
11. Athappan G, Sengodan P, Chacko P, Gandhi S. Comparative efficacy of different modalities for treatment of right heart thrombi in transit: A pooled analysis. Vasc Med. 2015 Apr 1;20(2):131–8.
12. Rose PS, Punjabi NM, Pearse DB. Treatment of Right Heart Thromboemboli. Chest. 2002 Mar 1;121(3):806–14.
13. Basman C, Rashid U, Parmar YJ, Kliger C, Kronzon I. The role of percutaneous vacuum-assisted thrombectomy for intracardiac and intravascular pathology. J Card Surg. 2018;33(10):666–72.