VOLUME - 11, ISSUE - 08, AUGUST - 2022 • PRINT ISSN No. 2277 - 8160 • DOI : 10.36106/gjra

Original Research Paper

Surgery

SMALL BOWEL ADENOCARCINOMA: CAN IT BE FAMILIAL::A CASE REPORT

Rinki

Manoj Kumar

Abhijit Kumar Singha

Satish Dalal

ABSTRACT Small bowel adenocarcinoma (SBA) is extremely rare. The incidence of SBA is very low as compared to large bowel adenocarcinoma and it is diagnosed in advanced stages because of lack of specific signs and symptoms in its presentation. Small bowel adenocarcinoma can also run in families, even if there is no conclusive literature as is available for large bowel adenocarcinoma. We encountered a rare case of adenocarcinoma of jejunum in a 34years male which was diagnosed by CECT abdomen. His father also had adenocarcinoma of jejunum 16 years back. A high index of suspicion is required to make the diagnosis of small bowel adenocarcinoma in suspected cases.

KEYWORDS : small bowel adenocarcinoma, CECT abdomen.

Case Report

A 34-year, old male, presented in A&E department with multiple episodes of vomiting and diarrhea. On examination his blood pressure was normal; the patient was mildly dehydrated with mild tachycardia. The abdomen was distended with exaggerated bowel sounds. No mass was palpable on examination. The digital rectal examination (DRE) and the rest of the systemic examinations were unremarkable. Plain X-ray abdomen revealed multiple air fluid levels. Ultrasound abdomen revealed no significant finding. Subsequently CECT abdomen , was done which revealed local asymmetrical circumferential thickening maximum measuring 2.5cm in proximal bowel loops. So a diagnosis of small bowel growth was made on CECT abdomen.

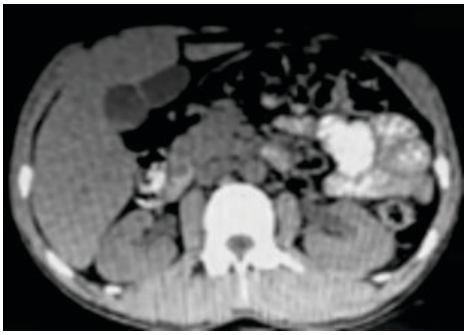

Fig-1 – CECT film showing local asymmetrical circumferential thickening in bowel loops.

This patient was managed with exploratory laparotomy with resection of growth in Jejunal segment with end-to-end jejuno-jejunal anastomosis.Intraoperative finding showed a jejunal growth of size 7×5cm extending into mesentry, 120cm from DJ junction. Mass was adherent to omentum which was also resected with involved bowel segment. Liver with rest of gut were normal suggesting no signs of metastasis.

The surgery was without complication and post-operative course was uneventful. Biopsy confirmed the growth as adenocarcinoma which was poorly differentiated, invading muscularis propria with immunohistochemistry markers as CDX2 positive, CK20 focal positive, CK7 negative.

On interrogation, during hospital stay, patient revealed that his father also had been operated for similar complaints in our hospital,6 years back. Records showed that he was having growth of small bowel near D-J which was associated with significant lymphadenopathy and metastatic deposits on sigmoid mesocolon. Histopathological examination revealed it to be moderately differentiated adenocarcinoma predominantely villous glands infiltrating into serosa.

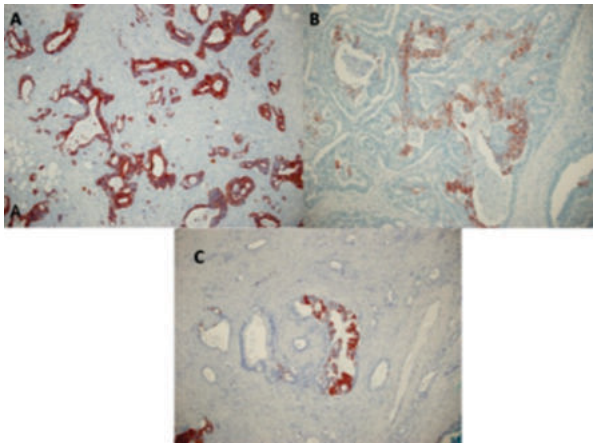

Fig-2– HPE film showing poorly differentiated adenocarcinoma with CDX2 POSITIVE, CK20 POSITIVE, CK7 NEGATIVE(2-ABC).

DISCUSSION

SBA is extremely rare. Despite a complete diagnostic workup, the correct diagnosis has been established preoperatively in only 50% of cases [5].the diagnosis is delayed because symptoms are non-specific and small intestine is not totally accessible to endoscopic examination. It usually manifests through complication like occlusion(40%) or bleeding(24%)[6]. Small bowel tumors are often not visualized by both upper GI endoscopy and colonoscopy in the first instance, and further investigations to visualise the small bowel are crucial, generally in the form of magnetic resonance enterography, CT colonography or wireless capsule endoscopy, which have all been shown to be effective in reaching the diagnosis. Though small bowel cancer normally occur in elderly patients, in this case, it was found in a 34-year-old man. The mass remained undetectable until he had complete small bowel obstruction. This was similar with studies, in which diagnosis of SBA was mainly obtained at advanced stages; where approximately 40 % of patients have lymph node metastasis (stage III), and 35 to 40 % have distant metastasis(stage IV) [7].

Recurrence at distant sites is the predominant reason of failure following a curative resection. To date, no standard adjuvant regimen has been rendered truly effective against SBA [8].

The incidence of SBA is very low as compared to large bowel adenocarcinoma and it is diagnosed in advanced stages because of lack of specific signs and symptoms in its presentation. Because of its lower incidence, the literature is diligent about its familial occurrence. Once diagnosed surgical exploration along wide resection is the mainstay of treatment.

CONCLUSION

Case is being reported for following reasons:

- SBA is extremely uncommon cause of small bowel obstruction. A high index of suspicion is required to make the diagnosis of SBA and early CECT abdomen is recommended in such cases.
- A familial incidence should also be looked for in such cases as it can have familial predisposition also.

Abbreviations:

SBA: small bowel adenocarcinoma

CECT: contrast enhanced computed tomography

Funding:

The authors received no specific funding for this work.

Competing interests:

The authors declare that they have no competing interests.

REFERENCES

1. E.DE.BREE.et.al(2018):the evolving management of small bowel adenocarcinoma ,Acta Oncologica,57:6,712-722.
2. Siegel RL, Miller KD, Jemal A. Cancer statastics,2016.CA cancer Clin.2016;66:7-30.
3. Bilimaria KY, Bentrem DJ, Wayne JD etal.small bowel cancer in the United states :changes in epidemiology,treatment,survival over last20 years. Ann Surgery,2009;249:63-71.
4. Schottenfeld D, Beebe-Dimmer JL, Vigneau FD.Tepidemiology and pathogenesis of neoplasia in small intestine. Ann epidemiol.2009;19:58-69.
5. R.Pereira et.al/journal of surgery case report,2021;4,1-3.
6. Kunizaki M,Hidaka S, Isomoto H, Takeshita H, Nanashima A, Sawai T, Yasutake T, and Nagayasu T:Diagnosis of small bowel metastasis of hepatocellular carcinoma by double ballon enteroscopy. Int J Surg Case Rep 3:263265,2012.
7. Dabaja BS, Suki D, Pro B, Bonnen M, Ajani J: Adenocarcinoma of the small bowel: presentation, prognostic factors, and outcome of 217 patients. Cancer. 2004, 101:518-526. 10.1002/cncr.20404
8. Varghese R, Weedon R: 'Metachronous' adenocarcinoma of the small intestine. Int J Clin Pract Suppl. 2005, 59:106-108. 10.1111/j.1368-504X.2005. 00070.x.