VOLUME - 11, ISSUE - 12, DECEMBER - 2022 • PRINT ISSN No. 2277 - 8160 • DOI : 10.36106/gjra

Original Research Paper | Paediatric Medicine

A RARE CAUSE OF HEPATOSPLENOMEGALY –MALIGNANT INFANTILE OSTEOPETROSIS

K. L. Sravani	Final Year PG, Department of Pediatrics, Guntur Medical college, Government General Hospital, Guntur
Brahmaiah	Assistant Professor, Department of Pediatrics , Guntur Medical college, Government General Hospital, Guntur
Mohan Chandran	Professor, Department of Pediatrics , Guntur Medical college, Government General Hospital, Guntur

ABSTRACT Osteopetrosis ("marble bone disease") is a descriptive term that refers to a group of rare, heritable disorders of skeleton characterized by increased bone density on radiographs. It is an uncommon disease of unknown cause. Osteopetrotic conditions vary greatly in their presentation and severity, ranging from neonatal onset with life-threatening complications such as bone marrow failure , to the incidental finding of osteopetrosis on radiographs . Osteopetrotic conditions vary greatly in their presentation and severity, ranging from neonatal onset with life-threatening complications such as bone marrow failure (e.g. classic or "malignant" ARO), to the incidental finding of osteopetrosis on radiographs (e.g. osteopoikilosis). The severe infantile forms of osteopetrosis are associated with diminished life expectancy, with most untreated children dying in the first decade as a complication of bone marrow suppression. A 4 month old male child presented with anemia and hepatosplenomegaly was diagnosed clinically and radiologically as Malignant Infantile Osteopetrosis.

KEYWORDS : Osteopetrosis, marble bone, osteoclasts, sandwich vertebra

INTRODUCTION

Osteopetrosis is a rare congenital disorder of osteoclast function and /or development characterized by impaired bone resorption and increased density of all bones [1-3].The dysfunctional osteoclasts that are observed in osteopetrosis result in bony overgrowth, leading to bones that are abnormally dense and brittle.Osteopetrosis is generally subdivided clinically into benign dominantly inherited form and malignant recessively inherited form.The most severe form of osteopetrosis is termed infantile (malignant) osteopetrosis is an autosomal recessive mode of transmission. This form is also called malignant osteopetrosis, not because of a relationship to cancer but because of the severity of the disease [4,5].This form present at birth or develops in early childhood, adolescence or young adult life.

If untreated, infantile osteopetrosis usually results in death by the first decade of life. The disease is severe and debilitating. Patients have symptoms of neurologic and hematological derangements, optis atrophy, severe anemia, bleeding, or infection, blindness, deafness, multiple fractures of the long bones with resulting deformity, hepatosplenomegaly, facial palsy, hydrocephalus, possible mental retardation and osteomyelitis. Increased bone density of cortical bone and club – shaped appearance of the long bones may be discovered incidentally on X-rays [3,6]. Autosomal recessive osteopetrosis also known as osteopetrosis congenita, is a rare disease of infancy to early childhood with a rate of 1/300000 birth worldwide with an exception of Costa Rica where the rate is much higher (3-4/100.000 birth).

Case Report |

4 months male child, born out of 3^{0}consanguineous marriage presented with

- Intermittent high grade fever -1month
- Abdominal distension – 10 days
- Increased work of breathing – 3 days
- Past, Family, Birth, Immunization histories are uneventful
- Baby weight – 5.5 kg appropriate for age with delayed mile stones
- Vitals – Febrile, Heart rate -150/ min, RR- 52 / min, Spo 2- 88% room air, 92% With O2

Clinical examination

- Pallor +,
- Hepatomegaly+,
- Splenomegaly grade III,
- Anterior fontanelle wide open

Investigations

Complete Blood Count	Hb 7gm TLC 24,000/mm3 (N-20% L-52% B-02% M-02% E-04%), Platelets 54 000/ulBand form 10%,Blast cells 8%, Myelocytes 8%,Metamyelocytes 15%
Peripheral smear	Anisopoikilocytosis , Leukoerythroblastic picture with thrombocytopenia 8
Direct coomb's	Negative
HB Electrophoresis	Abnormally low HbF with mildly raised HbF2
Serum iron profile	Normal
Serology & TORCH PROFILE	Normal

Infantogram

- Hyperinflation with increased bone density and prominence of costochondral junctions
- Increased bone density, Bone in bone appearance
- Sandwich vertebrae
- Fundus Examination – B/L Optic atrophy
- Acoustic reflux –absent
- BERA s/o B/L hearing loss . MRI Brain – Normal

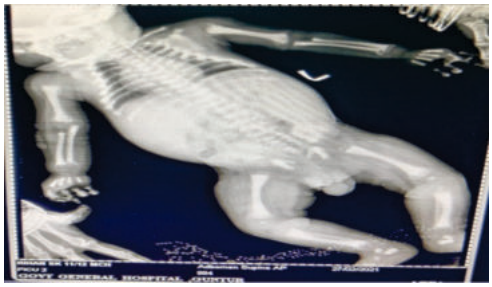

Fig. 1: Infantogram showed increased radiopacity of the skeletal bone of the chest and long bones

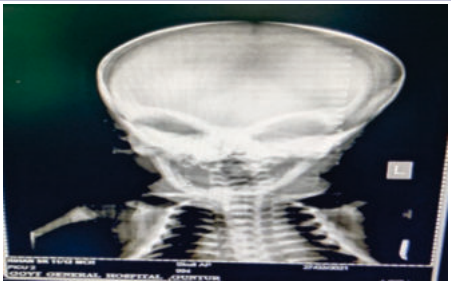

Fig. 2: Skull vault showed dense bone with narrowing of skull base and elongated head

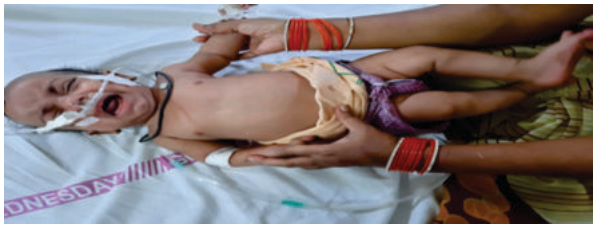

Fig3. 4 months male child with respiratory distress and abdominal distension

Final Diagnosis- MALIGNANT INFANTILE OSTEOPETROSIS
Genetic analysis – Homozygous variant of OSTM with loss of function variants

DISCUSSION

- MIOP usually manifests at birth or within early months infancy.
- This defect prevents the normal development of marrow cavities, the normal tubulation of long bones and the enlargement of osseous foramina [7.]
- In the present case report, the symptoms started at 3 months of age. Child had fever on and off, severe anemia, hepatosplenomagaly and elongated head. The radiographs showed generalized increased in bone density (Chalky white).
- A characteristic radiographic appearance of osteopetrosis has been termed bone-in-bone, in which the dense internal sclerosis appears as cortical bone inside the medullary cavity of the bone [9,10].
- The diagnosis is based on clinical, hematological and radiological parameters (increased bone density).
- In our case all criteria have met and later it was confirmed by genetic testing.

CONCLUSION

- MIOP is rare disease of infancy and if untreated it has fatal outcome.
- Patient should be properly examined and thoroughly investigated, MIOP to be as one of the differential diagnosis in infants with hepatosplenomegaly and to refer for SCT once confirmed the diagnosis.

REFERENCES

1. Del Fattore A, Cappariello A, Teti A. Genetics, pathogenesis and complications of osteopetrosis. Bone, 2008;42: 19-29.
2. Kilpatrick I. Osteopetrosis, In Damjanov I, et al. Anderson's Pathology, ed. 10. StLouis, losby, 1996; 2585, 2586.
3. Tolar I, Teitelbaum SL, Orchard PI. Osteopetrosis. N Engl J Med 2004, 351: 2839-2849.
4. Loria-Cortes R, Quesada-Calve E, Cordero-Chaverri C. Osteopetrosis in children. A report of 26 cases. J Paediatrics 1977;91:43.
5. Beighton P, Horan F, Hamersma H. A review of osteopetrosis. Postgrad Med J 1977;53:507.
6. Stuart C, Michael J. Textbook of oral radiology. Pharoah (4th ed), Mosby Company 2000;485-86.
7. Marks SC Jr. Morphological evidence of reduced bone resorption in osteopetroic (op) mice. Am J Anat 1982;163:157.
8. Mili Jain, Purvi Mittal. Osteopetrosis in twin infants mimicking leukemia, ABHH, 2017
9. Stoker DJ. Osteopetrosis Semin Musculoskelet Radical. 2002;6(4):299-305.
10. Resnick D, Bralow GW. Osteopetrosis Diagnosis of bone and joint Disorders.4 th ed. Philadelphia, PA:WB Saunders: 2002;4489-4491.