VOLUME - 11, ISSUE - 12, DECEMBER - 2022 • PRINT ISSN No. 2277 - 8160 • DOI : 10.36106/gjra

Original Research Paper

Radiology

ASSESSMENT OF PATIENTS WITH KNOWN CORONARY ARTERY DISEASE BY STRESS CARDIAC MRI.

Dr. Malik Masheerul Haq	MD, Department of Radiodiagnosis and Imaging, SKIMS
Dr. Naseer Ahmad Choh	Additional Professor, Department of Radiodiagnosis and Imaging, SKIMS
Dr. Yasir Hassan	MD, Department of Medicine, SKIMS.
Dr. Aamir Rashid	Assistant Professor, Department of Cardiology, SKIMS
Dr. Sehrish Shaheen*	MD, Department of Radiodiagnosis and Imaging, SKIMS *Corresponding Author

ABSTRACT

Background: Significant coronary artery lesions can be detected by evaluating regional myocardial perfusion by Cardiac MRI (CMR). This study aims to determine the usefulness of this technique in "known" patients of coronary artery disease (CAD). **Methods:** Our study aims at describing CMR features of CAD, including CINE and perfusion imaging. Stress perfusion imaging with pharmacologic stress (Adenosine) was performed on 22 patients with known CAD. These patients also underwent Catheter angiography (CAG). A total of 66 coronary territories were assessed for perfusion abnormalities and corresponding CAG findings. **Results:** Regional wall motion abnormalities were seen in 28(42.4%) coronary territories and regional myocardial thinning in 11(16%) territories. Hypokinesia (68%) was the most commonly observed wall motion abnormality. Wall motion abnormality was present in most (91%; n=20) of the infarcted territories and some (18.2%;n=8) of the non-infarct territories. Regional myocardial thinning was present in some of the infarcted (27%; n=6) territories and none of the non-infarcted territories. The mean wall thickness in infarct territories was 5.1mm±0.4 and in non-infarct territories was 7.1mm±0.6. T2/STIR hyperintensity was present in 5 (23%) infarct related coronary territories and none of the non-infarcted territories. In all 5 cases, MRI was done within 10 days of symptom onset. 32 (49%) coronary territories showed perfusion defect on stress imaging, with 23 (35%) of them showing a matched defect on rest perfusion and 9 (14%) showing stress inducible perfusion defect. No perfusion defect was seen in 34(51%) territories. All 22 patients underwent CAG. 15patients had significant disease (>70%) in a single vessel, 5 had in two vessels and none had in all the three vessels.2 patients had non-occlusive coronaries (MINOCA). Using CAG as gold standard, the sensitivity of stress perfusion CMR in detecting significant CAD in non-infarct territory in these patients was 70%, with a specificity of 94% and accuracy of 88.3%. **Conclusion:** Visual analysis of first-pass gadolinium CMR perfusion images to detect regional myocardial perfusion defect has a moderate sensitivity and high specificity for diagnosing significant obstructive CAD in non-infarct related coronaries, as compared to CAG.

KEYWORDS : Coronary Artery Disease, Cardiac Magnetic Resonance

INTRODUCTION

Cardiac MR is an emerging, noninvasive imaging modality for evaluating CAD. The assessment of regional myocardial perfusion is done by first pass perfusion imaging of the myocardium using gadolinium contrast1. Well perfused tissues show increased signal intensity. Myocardial perfusion defect is seen as a myocardial region that does not show this increase in signal.

The perfusion defect is often due to severe epicardial coronary stenosis, but may also be caused by regional microvascular bed involvement.2,3 Coronary microcirculatory dysfunction has a major role in the pathophysiology of CAD.4 CAG remains the gold standard for diagnosing CAD, but the degree of luminal narrowing of epicardial coronary lesions identified by CAG is a poor predictor of the lesion's functional severity.5

This study aims to determine the efficacy of first-pass gadolinium regional myocardial perfusion analysis, at rest and under pharmacological stress, to detect angiographically significant coronary lesions in non-infarct territories in known CAD patients. Significant CAD is the presence of a diameter stenosis of ≥ 70% in a major vessel or ≥ 50% in the left main, and usually results in referral for intervention.

MATERIALS AND METHODS

The study was performed in a tertiary care hospital of North India on 22 known CAD patients referred by the Department of Cardiology for viability assessment.

Detailed informed consent was taken from the patients before inclusion in the study.

Patients underwent Stress perfusion CMR and CAG.CMR findings were correlated with findings on CAG.

Study Design: Prospective study

Inclusion Criteria: Patients of known CAD, where viability was sought.

Exclusion Criteria:
Patients with contraindications to Adenosine -asthma, recent stroke (<1 month), bilateral carotid stenosis ,high degree AV blocks, arterial hypotension and patients with general contraindications to MRI.

Patient Preparation:

- 8 hours fasting.
- Caffeine containing foods were avoided for 24 hours.
- In patients on beta blockers, the last dose was skipped.
- Pre-procedure baseline vitals were checked (HR,BP,SpO2).
- 2 large bore, preferably 16 G cannulas were secured (one in either arm): one for contrast and one for adenosine.

CMR Protocol:

CMR was performed on 1.5T Magnetom Avanto (Siemens Healthcare). Our protocol included:

a) TRUFI based short-axis cine images from the mitral valve to the apex, 4-chamber and 3-chamber (LVOT views).
b) T2/STIR sequences in short axis.
c) TRUFI based dynamic first pass stress and rest perfusion: Perfusion imaging was performed using heavily T1 weighted saturation-recovery GRE sequences.
d) Delayed enhancement images (inversion recovery free breath/ breath hold sequences) were obtained 10 minutes after the administration of contrast (0.2 mmol/kg gadolinium-DTPA).

CINE Imaging: Global, regional wall thickness and functional assessment.

Stress Perfusion: Stress induced myocardial ischemia.

Rest Perfusion: Artefact assessment.

Delayed Enhancement: Myocardial infarct.

Timeline for Adenosine Stress Perfusion CMR:

1. Adenosine as pharmacological stress agent was administered as infusion @140mcg/kg/min for 6 minutes after functional CINE imaging.
2. First dose of contrast was injected after 2 minutes of adenosine administration for stress perfusion, contrast dose was 0.075-0.10mmol/kg body weight @4-5ml/sec followed by 30 ml saline flush at the same rate.
3. After 10 minutes, second dose of contrast was injected for rest perfusion as 0.1mmol/kg, after stress perfusion.

Interpretation and Reporting:

The American Heart Association recommended 17-segment model was used for reporting.6AHA divides the left ventricle into equal thirds: the basal, mid and apical. The basal and mid thirds have 6 segments each, the apical third has 4 and the true apex has 1. We visually graded each segment's left ventricular systolic function using a 5-point scale (normal wall motion to dyskinesis). Using ARGUS software, we derived quantitative measures of left ventricular function from the short-axis SSFP images. The left ventricular mass, end-diastolic volume, and end-systolic volume were derived from the standard method of manually outlining the contours of the ventricular borders (epicardial and endocardial), from which ejection fraction and stroke volume were calculated automatically.

We also visually graded the delayed enhancement (DE) images using a 5-point scale. For each segment, the area or transmural extent of hyperenhanced tissue was assessed. The DE images were interpreted with the immediately adjacent cine images, which provided a reference of the diastolic wall thickness of each region.

We scored stress and rest perfusion images for perfusion defects in 16 segments (apex - segment 17 was not well visualized). Then a systematic approach was used to detect the presence or absence of CAD. We used DE imaging to improve the accuracy of detecting CAD over perfusion imaging alone. A CMR stress test was labelled "positive for CAD" if myocardial infarction was present on DE-MRI OR if perfusion defects were present during stress MR, but absent at rest imaging ("reversible" defect) in the absence of infarction. The test was labelled "negative for CAD" if no aberrations were found (e.g. no MI and no stress/rest perfusion defects) OR if perfusion defects were seen at both stress and rest MRI ("matched" defect) in the absence of infarction. Matched defects were regarded as artifacts and not indicative of CAD. When both DE-MRI and stress perfusion MRI were abnormal, the test was deemed positive for ischemia if the perfusion defect was greater than the area of infarction.

OBSERVATIONS AND RESULTS

The study was conducted on 22 patients of known CAD (66 coronary territories).

CINE Imaging:

Regional wall motion abnormalities (hypokinesia/ akinesia/ dyskinesia) were present in 28 (42.4%) coronary territories (15 LAD, 7 LCX and 6 RCA) and regional myocardium thinning(LV end diastolic wall thickness ≤ 5.5 mm) in 11(16%) territories (7 LAD, 2 LCX and 2 RCA).

Table 1:CINE Imaging findings

Findings		Number of coronary territories	Percentage
Wall motion abnormality	Present	28	42
	Absent	38	58
Myocardial thickness	Maintained	55	84
	Thinned out	11	16

Hypokinesia (68%) was the most commonly observed wall motion abnormality. Wall motion abnormality was present in most (91%; n=20) of the infarcted territories and some (18.2%;n=8) of the non-infarct territories.

Regional myocardial thinning was present in some of the infarcted (27%;n=6) territories and none of the non-infarcted territories. The mean wall thickness in infarct territories was 5.1mm±0.4 and in non-infarct territories was 7.1mm±0.6.

T2/STIR hyperintensities:

These were present in 5 (23%) infarct related coronary territories and none of the non-infarcted territories. In all these 5 cases, MRI was done within 10 days of symptom onset.

Table 2: T2/STIR findings

	Number of territories	Percentage
Hyperintensity	5	23
No hyperintensity	61	77
Total	66	100

Dynamic first pass perfusion:

Visual assessment of regional perfusion defect was done and the corresponding coronary territories were compared with CAG findings.

Among the 66 coronary territories, 32(49%) showed perfusion defect on stress imaging, with 23 (35%) of them showing a matched defect on rest perfusion and 9(14%) showing stress inducible perfusion defect (5 in LAD , 2 in LCX and 2 in RCA territory). No perfusion defect was seen in 34(51%) territories.

Table 3: Dynamic first pass perfusion in known CAD patients

Stress and Rest		Number of territories	Percentage
Perfusion defect	Matched	23	35
	Reversible inducible	9	13
	No perfusion defect	34	52
	Total	66	100

Invasive coronary angiography:

All the 22 patients underwent CAG. 15patients had significant disease (>70%) in a single vessel (LAD in 9, LCX in 2, RCA in 4). 5 patients had significant disease in two vessels (LAD and RCA in 3, LAD and LCX in 1, LCX and RCA in 1). No patient had significant disease in all the three vessels. 2 patients had non-occlusive coronaries(MINOCA).

Table 4: CAG findings in known CAD patients

CAG: significant disease	Number	Percentage
Single vessel	15	23
Double vessel	5	15
None	41	62
Total	66	100

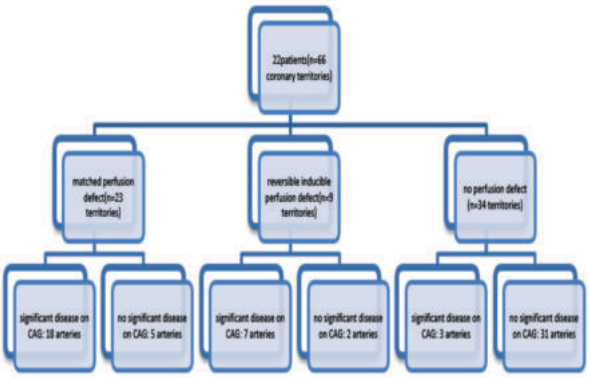

Flow-chart depicting the perfusion CMR and CAG findings:

CAG correlation:

The anatomic QCA (quantitative coronary analysis stenosis) was used as reference standard. Significant CAD was considered in the presence of a diameter stenosis of ≥ 70% in a major vessel or ≥ 50% in the left main.

The 23 coronary territories showing matched defect, on perfusion imaging demonstrated hyperenhancement at delayed-enhancement MR imaging (infarctions) were excluded.

Out of 9 coronary territories with stress inducible - reversible perfusion defect, 7(true positive) showed significant CAD and 2(false positive) showed non-significant CAD.

Out of 34 coronary territories without any perfusion defect, 31(true negative) showed no significant CAD and 3(false negative) showed significant CAD.

Using CAG as gold standard, the sensitivity of stress perfusion CMR in detecting significant CAD in non-infarct territory in these patients was 70%, with a specificity of 94% and accuracy of 88.3%.

Table 5: Diagnostic accuracy of adenosine stress perfusion MRI in diagnosis of significant CAD in non-infarct territories.

Variable	Value(%)	95% CI
Sensitivity	70	61.2-84.5
Specificity	94	89.15-98.23
PPV	77.8	69.15-86.23
NPV	86.1	81.2-91.5
Diagnostic accuracy	88.3	77.96-96.76

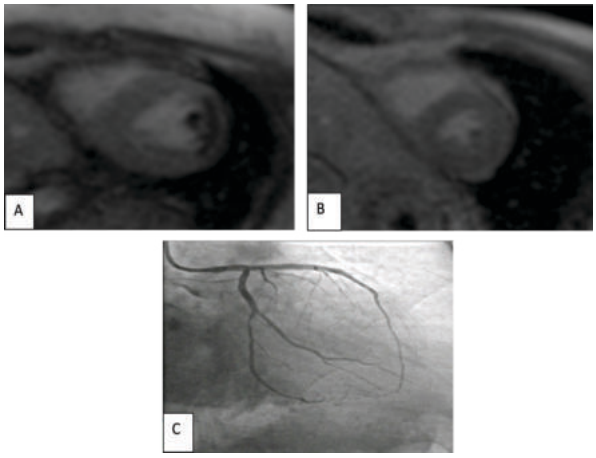

Figure 1: showing a subendocardial perfusion defect extending into myocardium (anterolateral) atmid-ventricular level (A), with no perfusion deficit under resting conditions(B). Corresponding CAG revealing 70-80% stenosis in mid-LCX ©.

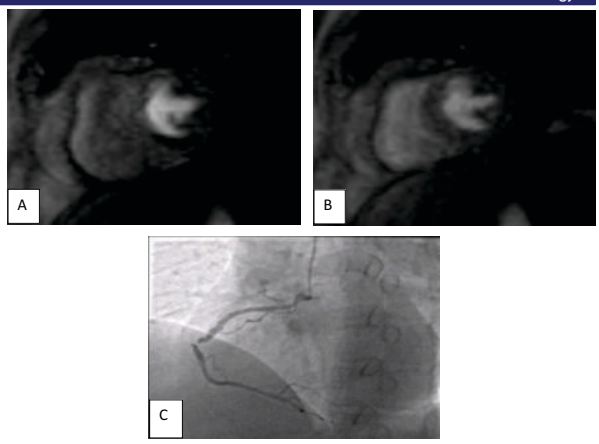

Figure 2: demonstrates a well-defined area of diminished perfusion in the inferior wall at the mid-ventricular level on stress perfusion imaging(A). This region appears normal on the rest perfusion imaging(B).

Corresponding CAG revealing 80% discrete lesion in distal RCA (C).

DISCUSSION

In our study, 22 patients with clinical, biochemical, electrocardiographic, echocardiographic features of CAD were studied for perfusion MR features and compared with CAG.

CINE Imaging: Ventricular wall motion and thickness:

The findings of our study were similar to the study done by Dipan J Shah et al. on 1055 patients with CAD undergoing CMR viability assessment, of which 599 (57%) were found to have wall motion abnormalities and 201 (19%) were found to have regional wall thinning. 7

The advantage of Cine MRI is that it accurately assesses the Left Ventricular contractile function in patients with poor acoustic windows i.e. patients poorly suited for echocardiography.

Regional wall motion thickness helps in viability assessment, as thin dysfunctional wall has a low likelihood of recovering function; however, weakness of this approach is its poor performance to predict recovery in dysfunctional segments with preserved wall thickness.

T2/STIR hyperintensities:

T2-weighted imaging technique (STIR) is an "edema-weighted" imaging, showing myocardial edema as bright while normal myocardium appears dark8,9. Myocardial edema is most apparent in the first days post-infarction and then slowly disappears due to infarct healing.

T2/STIR hyperintensity (myocardial edema) is present in acute infarcts and identifies myocardial Area at Risk.10,11,12 This includes the reversibly injured myocardium, which is capable of functional recovery (difference between T2 hyperintensity and LGE identifies salvageable myocardium).

With increasing ischaemia time, salvageable myocardium decreases at the expense of increasing infarct size, while the myocardium at risk remains constant. Thus, early reperfusion may result in complete myocardial salvage (i.e. aborted infarction). Myocardial salvage is independently associated with early ST-segment resolution and is an independent predictor of adverse ventricular remodelling and major cardiac events.13,14

Marcus Carlsson et al. in 2009demonstrated in 16 patients with first-time ST-segment elevation myocardial infarction

that T2-STIR imaging done within 1 week after reperfusion could precisely detect myocardium at risk.

Dynamic first pass perfusion:

Results analogous to our study were reported by Guillem Pons Lladó et al. who studied 32 patients with known CAD (96 coronary territories) and found fixed perfusion defects (at rest and under stress) in 35 (36%), reversible defects (not present at rest) in 16 (17%) and no perfusion defect in 45 (47%) territories.1

Stress perfusion CMR non-invasively evaluates the ischemic burden in non-infarct territories in known CAD patients. Assessing the severity of ischemia will be helpful to guide clinical decision-making regarding using CAG or intensifying the preventive and anti-ischemic therapy to reduce the patient's ischemic burden and improve clinical outcomes. Patients with residual ischemia on stress perfusion CMR will benefit from CAG and revascularisation procedures and those without ischemia will benefit from optimizing Medical Therapy.

CAG and Stress Perfusion CMR correlation:

Michael Fenchel et al. found comparable results to our study in 22 patients with CAG documented CAD, with the sensitivity and specificity of perfusion MRI to detect perfusion deficits as 81% and 89% respectively.

Compared to these studies, a high false negative rate could be the cause for relatively low sensitivity in our study group, and this may be due to insufficient pharmacological stress in some patients, a failed splenic switch-off. Splenic switch-off (the visual attenuation of splenic perfusion during adenosine stress perfusion MR compared with rest) is a simple potential indicator of stress adequacy, differentiating false negative from true negative results. A repeat perfusion CMR in these patients with failed splenic switch-off using higher dose adenosine 170 or 210 mcg/kg/min (thus ensuring adequate stress was achieved) would have reduced the false-negative findings in our study.

Summary

- Stress Perfusion Cardiac MR is a noninvasive method for diagnosing significant obstructive CAD in non-infarction territories, with moderate sensitivity, high specificity and excellent diagnostic accuracy in comparison to CAG.
- Stress perfusion CMR along with delayed enhancement imaging, serves as a one-stop shop non-invasive functional imaging technique, for assessment of the functional significance of coronary artery lesions. A negative adenosine stress MR perfusion study averts the necessity for revascularisation, as the negative study is associated with an extremely low risk for major adverse cardiac events in the year following the study.
- Although in routine clinical practice, CAG is the conventional technique to diagnose significant CAD, it is an imperfect reference standard due to its inability to assess the hemodynamic significance of a stenosis..
- The decision to go for coronary revascularization in known CAD patients must not be based on the coronary anatomy only, as is the usual clinical routine. Considering the oculostenotic reflex (propensity to overestimate the functional importance of intermediate coronary artery lesions), revascularisation should be reserved for patients with demonstrable myocardial ischemia, to prevent the overuse of revascularisation.

REFERENCES

1. Guillem Pons Lladó, Francesc Carreras, et al . Assessment of Myocardial Perfusion by Cardiovascular Magnetic Resonance: Comparison With Coronary Angiography.
2. Wilke N, Jerosch-Herold M, Wang Y, Huang Y, Christensen BV, Stillman AE, et al. Myocardial perfusion reserve: assessment with multisection, quantitative, first-pass MR imaging. Radiology 1997;204:373-84.
3. Sandstede JJW, Lipke C, Beer M, Harre K, Pabst T, Kenn W, et al. Analysis of first-pass and delayed contrast-enhancement patterns of dysfunctional myocardium on MR imaging: use in the prediction of myocardial viability. AJR Am J Roentgenol 2000; 174:1737-40.
4. Federico Vancheri, Giovanni Longo, , and Michael Henein. Coronary Microvascular Dysfunction , J Clin Med. 2020 Sep; 9(9): 2880. Published online 2020 Sep 6.
5. M Pakkal, V Raj, and G P Mccann, Non-invasive imaging in coronary artery disease including anatomical and functional evaluation of ischaemia and viability assessment, Br J Radiol. 2011 Dec; 84(Spec Iss 3): S280–S295.
6. Cerqueira MD, Weissman NJ, Dilsizian V, et al. Standardized myocardial segmentation and nomenclature for tomographic imaging of the heart: a statement for healthcare professionals from the Cardiac Imaging Committee of the Council on Clinical Cardiology of the American Heart Association. Circulation 2002;105:539–42.
7. Basil Al-Sabeq, MD, Faisal Nabi, MD, and Dipan J Shah, Assessment of myocardial viability by cardiac magnetic resonance imaging, Curr Opin Cardiol. 2019 Sep; 34(5): 502–509.
8. Tirza Springeling , Alexia Rossi , Cardiovascular MRI in acute myocardial infarction.
9. Friedrich MG. Myocardial edema—a new clinical entity? Nat Rev Cardiol 2010;7:292–6.
10. Anthony H. Aletras, Gauri S. Tilak, Retrospective Determination of the Area at Risk for Reperfused Acute Myocardial Infarction With T2-Weighted Cardiac Magnetic Resonance Imaging.
11. Aletras AH, Tilak GS, Natanzon A, et al. Retrospective determination of the area at risk for reperfused acute myocardial infarction with T2-weighted cardiac magnetic resonance imaging. Histopathological and displacement encoding with stimulated echoes(DENSE) functional validations. Circulation 2006;113:1865–70.
12. Marcus Carlsson , Joey F. A. Ubachs, Erik Hedström et al in 2009 demonstrated in Sixteen patients with first-time ST-segment elevation myocardial infarction that T2-STIR performed up to 1 week after reperfusion can accurately determine myocardium at risk . JACC : Cardiovascular Imaging 2009 by the American College of Cardiology Foundation.
13. Lockie T, Nagel E, Redwood S, Plein S. The use of cardiovascular magnetic resonance imaging in acute coronary syndromes. Circulation 2009; 119:1671–81.
14. Kim HW, Farzaneh A, Kim RJ. Cardiovascular magnetic resonance in patients with myocardial infarction. Current and emerging applications. J Am Coll Cardiol 2010;55:1–16.