VOLUME - 12, ISSUE - 01, JANUARY - 2023 • PRINT ISSN No. 2277 - 8160 • DOI : 10.36106/gjra

Original Research Paper

Plastic Surgery

COMPARATIVE STUDY OF PRIMARY REPAIR WITH OPEN MESHPLASTY V/S ABDOMINOPLASTY IN A TERTIARY CARE HOSPITAL IN ASSESSING THE OUTCOME OF INCISIONAL HERNIA

Dr. Narendra G Naik	Associate Professor in Dept. of General Surgery, Consultant Plastic surgeon - MGM Medical College, Navi Mumbai
Dr. Ashika R Mehta	Postgraduate Resident in Dept. of General Surgery - MGM Medical College, Navi Mumbai
Dr. Sukhdev V Adhikari	Tutor in Dept. of General Surgery - MGM Medical College, Navi Mumbai
Dr. Alauddin Tungekar	Assistant Professor in Dept. of General Surgery - MGM Medical College, Navi Mumbai

ABSTRACT

Incisional hernias are hernias which occur as a result of excessive tension and inadequate healing of a previous incision1. Incidence of these hernias is 9.9% worldwide. These hernias arise through a defect in the musculo-fascial layers of the abdominal wall in the region of a postoperative scar. They can enlarge over time, leading to pain, obstruction, incarceration and strangulation. With loss of domain, the natural rigidity of the abdominal wall becomes compromised and the abdominal musculature is often retracted. Treatment includes Meshplasty or Abdominoplasty. In meshplasty surgery, the abdominal contents are reduced and the defect is closed. Following this, an onlay or inlay mesh is placed which secures the primary repair as well as allows fibrosis of the anterior abdominal wall by capillary and fibroblasts neovascularization in the spaces between the mesh. The advantage of using a mesh is for closing large defects or for defects in which abdomen cannot be closed by primary intention. Infection of the mesh, seroma, abscess formation, recurrence, surgical site infection, changes or loss in the abdominal domain are a few complications associated with this surgery. Another method of repair of these incisional hernias in our study is by abdominoplasty. In Abdominoplasty, we will plicate the linea alba from xiphisternum to pubic symphysis after closure of defect. The biggest drawback of meshplasty which is infection, is prevented in abdominoplasty. Additionally, abdominoplasty can provide an added advantage of it being cost effective. Here in this study, we will to compare and evaluate Primary Repair with Open Meshplasty v/s Abdominoplasty in cases of incisional hernias, on the their surgical outcome on the basis of rate of infection, flap necrosis, rate of recurrence and post-operative cosmesis.

KEYWORDS :

INTRODUCTION

Incisional hernias are hernias which occur as a result of excessive tension and inadequate healing of a previous incision[1]. Incidence of these hernias is 9.9% worldwide [2].

It is important to treat these hernias as they can lead to pain, infection, edema and at a later stage lead to bowel incarceration or bowel obstruction/strangulation. The aim of the surgery for incisional hernia, is to achieve full restoration of abdominal wall function, including muscular support, prevention of visceral eventration, and adequate soft tissue coverage.[(3)] Here in this study we will describe about implementation of the surgical technique of abdominoplasty and comparing it with meshplasty.

AIMS AND OBJECTIVES

1. To compare Primary Repair with Open Meshplasty v/s Abdominoplasty in cases of incisional hernias
2. To evaluate patients on the basis of surgical outcome by comparing open meshplasty v/s Abdominoplasty.

METHODS AND MATERIALS

This is a prospective, comparative, randomized study, conducted on the patients who were diagnosed with Incisional Hernia. Patients who were admitted through Outpatient Department of MGM Medical College and Hospital, Navi Mumbai from October 2022 to December 2022, were included in the study after taking ethical clearance from Institutional Ethics Committee.

Complete clinical history and necessary pre-operative investigations were recorded in case proforma after taking due consent from the patient and the relatives. A total of 50 patients were included in the study. Patients fulfilling the inclusion criteria are allotted to either of the two groups (A or B) of 25 patients each by Randomization Method. Group A patients were treated by Meshplasty and Group B was treated with Abdominoplasty and their results were compared and assessed over the study time points (baseline, 1 week, 2 weeks and after 2 month).

Inclusion and Exclusion Criteria

Inclusion Criteria:

All patients above 18 years of age, diagnosed with incisional hernia on clinical and radiological examination and willing to give consent for participating in the study.

Exclusion Criteria:

1. Patients diagnosed with incisional hernia which is obstructed, incarcerated or strangulated.
2. Patients under the age of 18.
3. Patients not giving consent for participating in the study
4. All other abdominal hernia without previous abdominal surgery.
5. All recurrent hernias after meshplasty, are excluded from our abdominoplasty case study

OBSERVATION AND RESULTS

Table 1: Comparison between Regular meshplasty and Abdominoplasty

Particulars	Regular meshplasty % (Group A)	Abdominoplasty % (Group B)
Flap Necrosis	4%	8%
Infection without flap edge necrosis	16%	8%
Recurrence	8%	0%
Post- surgical Cosmesis	0%	100%

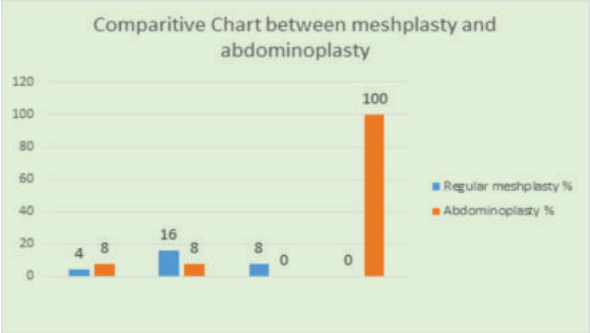

Figure I: Bar chart comparing meshplasty v/s Abdominoplasty to assess the complications

Table 2: Comparison between Mean duration of days of drain and suture removal (in days) for Regular meshplasty and Abdominoplasty

	Regular meshplasty	Abdomino plasty
Mean duration of suture removal	8 days	14 days
Mean duration of drain removal	5 days	14 days

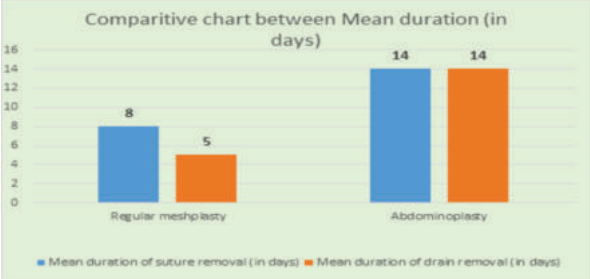

Figure II: Bar chart comparing meshplasty v/s Abdominoplasty to assess the duration of drain removal and suture removal

The observational study compared the following parameters – flap necrosis, infection without flap edge necrosis, recurrence and post-surgical cosmesis.

In both groups A and B, the edges of the raised flap during dissection, had developed necrosis which accounted to 4% and 8% respectively. This was treated by suitable dressing and secondary suturing. In group A cases, though there was flap edge necrosis, the mesh was covered by soft tissue hence, those cases selected were treated by secondary suturing. Due to wide dissection in group B cases, the chances of flap edge necrosis is more.

Group B showed that out of 25 patients operated for Abdominoplasty, only 2 patients (8%) developed post-operative infection which was treated by antibiotics.

Out of 25 patients operated for Meshplasty (Group A), 4 of them developed infection (16%). One of the patients, was treated by removal of mesh and others by suitable antibiotics. This caused increased hospital stay and economic burden on the cases.

In Group B cases, in which recurrent hernia was developed after previous meshplasty and as the removal of the mesh wasn't possible due to omental and bowel adhesions to the mesh and there were no signs and symptoms of obstruction, and hence those cases were treated by Abdominoplasty. (Fig III). There was no recurrence in any patient undergoing abdominoplasty.

Two cases out of 25 cases (8%) from study A (meshplasty) had recurrent hernia. The study period of our study was 3months and these patients were treated subsequently by abdominoplasty technique. But these 2 cases are not included in the study B.

The recurrent cases of Group A study, are excluded from Group B study. The recurrent hernia, previously treated by Meshplasty in Group B, are not included from Group A. Patients were advised pressure garment for 6 months to prevent recurrence.

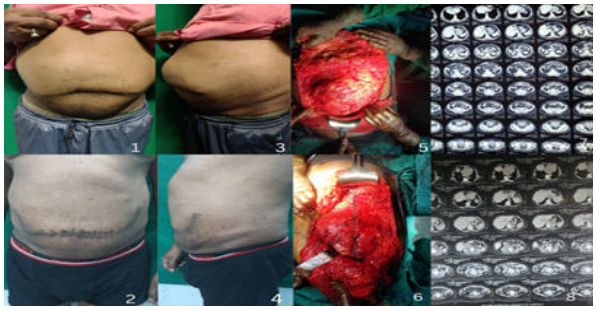

Figure III: case of 60year old male in group B, with recurrent incisional hernia with mesh in-situ. Patient was operated for abdominoplasty with primary closure and plication of the anterior rectus sheath without removal of the mesh.

Abdominoplasty, or 'Tummy-Tuck' is a surgery which reduces the abdominal girth to a great extent, and has promising results cosmetically. The scar of the abdominoplasty surgery lies in the resting-tension line and becomes almost invisible, once the patient wears pressure garments after coconut oil massage over the scar. Hence Group B patients had a 100% cosmetic result in view of body contouring and scar satisfaction (Fig IV, V) Compared with patients undergoing meshplasty (Group A), there was no cosmetic or scar satisfaction for the same as the primary aim of the surgery is to reduce the defect and prevent recurrence. Hence there was 0% cosmetic result satisfaction.

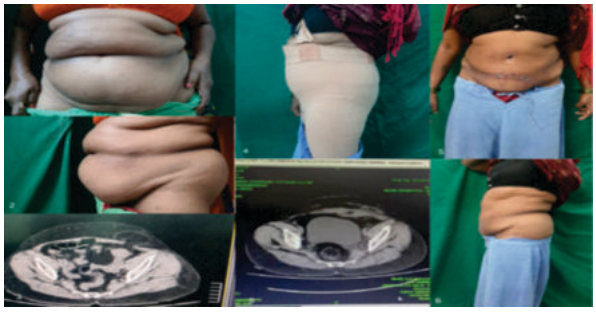

Figure IV: fig 1,2 showing clinical pre-op incisional hernia. Fig 3 shows defect over anterior abdominal wall with contents protruding outside. Fig 4 shows pressure garment application to prevent recurrence. Fig 5 shows plicated anterior abdominal wall with closure of defect and reduction of contents. Fig 6, 7 shows post op photos with creation of umbilicus.In Abdominoplasty surgery, delayed suture removal and Drain removal is required. The mean duration of drain and suture removal is around 2 weeks.

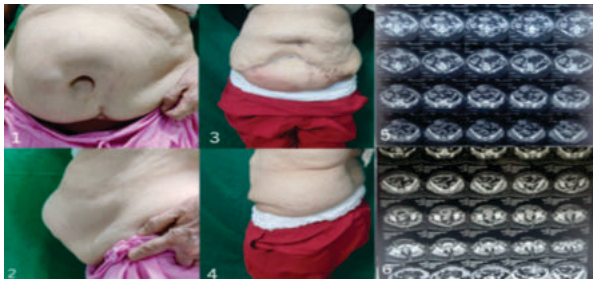

Figure V: Fig 1, 2 show pre-op photos of incisional hernia. Fig

3, 4 shows post op images after Abdominoplasty showing loss of abdominal girth and cosmetic improvement. Fig 5 shows pre-op CT scan with herniated abdominal contents with defect. Fig 6 showing Post op CT scan

DISCUSSION

Incisional Hernias arise through a defect in the musculofascial layers of the abdominal wall in the region of a postoperative scar. Thus they may appear anywhere on the abdominal surface. They are often associated with excess of skin and fat, laxity or muscle relaxation and abdominal shape deformity with hernia bulge and scars. Incisional hernias can enlarge over time, leading to pain, obstruction, incarceration and strangulation.

Incisional Hernia mainly develops due to inability to take proper post-operative care using abdominal binder, inability to get up from the bed in lateral position and improper surgical technique. Obesity, advanced age, twin pregnancy, manual labour, divarication of rectus muscle, COPD and other conditions which increase intra-abdominal pressure are other factors predisposing to development of incisional hernia.

Literature searches reveal post-laparotomy incisional hernia rates of 4-18%, with over 75% of these occurring within two years of the initial surgery[6].

Large incisional hernias can result in loss of abdominal domain, which occurs when the abdominal contents no longer reside in the abdominal cavity. With loss of domain, the natural rigidity of the abdominal wall becomes compromised and the abdominal musculature gets retracted.

Another reason for incisional hernia occurrence is laxity of the muscles of the anterior abdominal wall. The strength of the abdominal wall is based majorly on the strength of the anterior rectus sheath, and also on the type of incision during the previous surgery. Studies have shown the incidence of incisional hernia was higher for midline incisions compared with transverse incisions.

In Mshplasty there is primary repair with mesh placement. Here, the abdominal contents are reduced and the defect is closed (plication followed by closure of anterior rectus sheath). This allows reduction of the herniated contents. Following this, an onlay or inlay mesh is placed which secures the primary repair and also allows fibrosis of the anterior abdominal wall by capillary and fibroblasts neovascularization in the spaces between the mesh. The advantage of using a mesh is for closing large defects or for defects in which abdomen cannot be closed by primary intention. Infection of the mesh, seroma, abscess formation, recurrence, surgical site infection, loss in the abdominal domain are a few complications associated with this surgery. A major disadvantage of mesh repair is that the patient has to bear the cost of the mesh which causes economic burden on the patient. These complications cannot be ignored and ways to combat these complications is very essential.

A well-placed mesh should have good overlap around margins of the defect, at least 2-5cms. Mesh Plug operations are fast, but plugs can form a dense 'meshoma' of plug and collagen. Other complications include migration, erosion into adjacent organs, fistula formation and chronic pain[5]. The surgical procedure of meshplasty is selected, considering the abdominal tone around the hernia is adequate. But it is noticed that in any incisional hernia, there is generalised loss of strength of abdominal tone.

Another method of repair of these incisional hernias in our study is by abdominoplasty. It is a popular aesthetic operation. Laxity of the skin and fascia is one of the main indication for the surgery. This can be observed in multiparous women. Abdominal wall problems are frequently reported as a result of fascial laxity or diastasis. Traditional methods for conducting abdominoplasty involve making skin incisions all the way around the umbilicus, which causes the umbilicus to completely separate from the anterior abdominal flap. As a result, the umbilical stalk serves as the umbilicus's sole source of vascularity to the underlying fascial attachments. (Figure IV)

In Abdominoplasty, we plicate the linea alba from xiphisternum to pubic symphysis after closure of the defect. The biggest drawback of meshplasty which is infection, is prevented in abdominoplasty. Additionally, abdominoplasty can provide an added advantage of being cost effective.

Abdominoplasty approach includes using a transverse lower abdominal incision with or without extending it into an inverted-T incision. The hernial defect is then identified and isolated. Repair is obtained with primary fascial closure and plication, fascial approximation and reinforcement if needed with absorbable Vicryl mesh, or placement of permanent mesh with or without fascial approximation.

The preservation of the umbilical blood supply is crucial for abdominoplasty. It has been established that abdominoplasty and incisional hernia repair puts the umbilicus at risk for loss of its vascularity. Large incisional hernias can cause the skin and soft tissue to become thin and alter the normal anatomy of the front abdominal wall. To prevent umbilical ischemia, careful preoperative planning is necessary to identify the safe point of entry and plane of dissection. This preparation takes into account the hernia's size and placement in relation to the umbilical stalk. Also useful in preserving the perforating vessels are fascial incisions made away from the umbilical stalk [11]. Delayed or immediate reconstruction of the umbilicus is done in cases where umbilicus is excised along with the hernial sac in abdominoplasty surgery.

According to a report by J Douglas Robertson, he reviewed 123 patients with incisional hernia out of which 82 underwent abdominoplasty. 8 out of 82 of these hernias recurred. Most complications were minor and could be managed with local wound care only. Major complications included one enterocutaneous fistula, one occurrence of skin flap necrosis requiring operative debridement and skin grafting, and one delayed permanent mesh extrusion 2 years after repair [4]. In our study, two out of 50 patients, had necrosis of the lower margin of the skin incision. This was mainly due to obesity and lymphatic collection which occurred at a later date.

In a study conducted by Hughes et al. [7], he demonstrated that an abdominoplasty at the time of hernia repair reduces the incidence of wound infections and the possibility of hernia recurrence. Reid and Dumanian [8] demonstrated a reduction in the incidence of wound infection was proportional to the operative surgical time. The average surgical time for abdominoplasty surgery is around two and half hours.

In addition, many plastic surgeons would prefer not to implant meshes to support the anterior abdominal wall out of concern for infection, dehiscence, and extrusion, as well as the possibility of persistent pain that may result from the necessity to remove the mesh in the future.

Cooper et al. [9] demonstrated that abdominoplasty in the setting of an incisional hernia repair can improve patients satisfaction, particularly appearance, hygiene, and self-confidence.[9] Saariniemi et al. published a prospective study that concluded that abdominoplasty significantly improved quality of life, body satisfaction, effectiveness, sexual

functioning, self-esteem, and mental health for patients with incisional hernias.[10] In Our study also, there is promising cosmesis as there is scar reduction as well as decrease in the abdominal girth, resulting is patient satisfaction.

Similar outcomes was seen in our study with patients who had incisional hernias. As shown in the follow-up period, patients gave a feedback about improved incontinence and constipation, reduced back pain, improved local hygiene, easier dressing and walking, etc. Hence the simultaneous combination of abdominoplasty and hernioplasty in our study had a positive impact on the quality of life of these patients when compared to the isolated hernioplasty.

Comparing the two methods, it is observed that mesh repair is done only for the site of deficiency and the rest of the abdominal wall is not repaired. Whereas in Abdominoplasty, the site of defect as well as the rest of the surrounding abdominal wall is taken care of by plication of the entire anterior rectus sheath. Hence by abdominoplasty surgery, abdominal tone is improved by vertical and horizontal plication of anterior rectus sheath, with less morbidity.

Abdominoplasty is a major specialized surgery which is usually performed by a plastic surgeon, but with thorough knowledge, training, and basic understanding of the surgical technique, general surgeons can also perform this surgery with great efficiency.

CONCLUSION

This study concluded that, Abdominoplasty is one of the better modalities of treatment as compared to open Meshplasty for the treatment of Incisional Hernia, in view of cost effectiveness, less chances of recurrence as well as post-surgical cosmesis.

REFERENCES:

1. Mark A. Malangoni, Michael J. Rosen; Hernias: Sabiston Textbook of Surgery. The Biological Basis of Modern Surgical Practice, 20th Edition, 1600 John F. Kennedy Blvd, 2017
2. R. Le Huu Nho, Mege, M. Ouaïssi, I. Sielezneff, B. Sastrea, Incidence and prevention of ventral incisional hernia Journal of Visceral Surgery (2012) 149, e3—e14
3. Van Geffen, H. J. A. A., & Simmermacher, R. K. J. (2005). *Incisional Hernia Repair: Abdominoplasty, Tissue Expansion, and Methods of Augmentation. World Journal of Surgery, 29(8), 1080–1085.*
4. Robertson, J. D., de la Torre, J. I., Gardner, P. M., Grant, J. H., Fix, R. J., & Vásconez, L. O. (2003). *Abdominoplasty Repair for Abdominal Wall Hernias. Annals of Plastic Surgery, 51(1), 10–16*
5. Bruce Tulloh, Stephen J Nikson; Abdominal Wall, hernia and umbilicus: Bailey & Love's Short Practice of Surgery, 27th Edition; CRC Press; Taylor & Francis group : 2018
6. Skipworth J, Khan Y, Motson R, Arulampalam T, Engledow A (2010): Incisional hernia rates following laparoscopic colorectal resection. International Journal of Surgery, 8(6): 470-473.
7. Hughes KC, Weider L, Fischer J et al. (1996): Ventral hernia repair with simultaneous panniculectomy. Am Surg., 62: 678-681.
8. Reid RR, Dumanian GA (2005): Panniculectomy and the separation-of-parts hernia repair: a solution for the large infraumbilical hernia in the obese patient. Plast Reconstr Surg., 116:1006-1012.
9. Cooper JM, Paige KT, Beshlian KM, Downey DL, Thirlby RC (2008): Abdominal panniculectomies: high patient satisfaction despite significant complication rates. Ann Plast Surg., 61:188-196.
10. Saariniemi K, Salmi A, Peltoniemi H, Helle M, Charpentier P, Kuokkanen H (2014): Abdominoplasty improves quality of life, psychological distress, and eating disorder symptoms: a prospective study. Plastic surgery international, 2014: 197232.
11. McKnight CL, Fowler JL, Cobb WS, Smith DE, Carbonell AM (2012): Concomitant sublay mesh repair of umbilical hernia and abdominoplasty. Can J Plast Surg., 20(4): 258- 260.