VOLUME - 12, ISSUE - 01, JANUARY - 2023 • PRINT ISSN No. 2277 - 8160 • DOI : 10.36106/gjra

Original Research Paper

Urology

LAPROSCOPY ASSISTED PERCUTANEOUS NEPHROLITHOTOMY FOR TREATMENT OF RECURRENT RENAL STONE IN LARGE LUMBAR INCISIONAL HERNIA

Dr. Shams Tabrej	Dr. B.A.M. Hospital, CR, Byculla, Mumbai.
Dr. Varun Gunavathe	Dr B.A.M. Hospital, CR, Byculla, Mumbai.
Dr Sandeep Prakash Gaikwad	Dr. B.A.M. Hospital, CR Byculla, Mumbai.
Dr Saqib Shahab	R.D.J.M, Muzaffarpur.
Dr. Ashish Jatale	Dr. B.A.M. Hospital, CR, Byculla, Mumbai.
Dr. Ajay Jani	Dr. B.A.M. Hospital, CR, Byculla, Mumbai.
Dr. Manjunath	Dr. B.A.M. Hospital, CR, Byculla, Mumbai.

ABSTRACT the objectives of this case report is to highlight treatment of recurrent renal stone in patient of large incisional hernia in lumbar region by laproscopic assisted PCNL. A 58 years old lady presented with large incisional hernia at right lumbar region on further evaluation she is also diagnose with right partial staghore calculi measuring 2.8 cm ,renal stone were diagnosed with ultrasonography and CT-IVP, she is also having past history of stone disease. Due to large stone bulk and presence of bowel in hernia sac ESWL and flexible ureteroscopy was not done .Also PCNL has some limitation and challenge due to vascular injury and damage to internal organ. So we performed laproscopy assisted PCNL.

KEYWORDS : recurrent renal stone , lumbar hernia , laparoscopy-assisted, percutaneous nephrolithotomy

INTRODUCTION:

The lifetime prevalence of kidney stone disease is 1-15% varying at geographical location currently ESWL or Flexible ureteroscopy or PCNL or Open procedure are the common therapeutic methods recommended for renal stone management , PCNL is a preferred modality in treatment of renal stone that are larger than 20 mm in diameter, however PCNL approach could pose a serious complication due to injury to aberrant vessel , blood transfusion, thorasic complication and internal organ injury. Thus laproscopy assisted PCNL is great help in special case of renal stone with large hernia.

Case Presentation:

A 58 years old lady presented with large incisional hernia at right lumbar region since 3 years. She has past history of right renal stone disease 8 years back for which she underwent open pylolithitomy for stone surgery. On clinical and radiological evaluation with USG and CT IVP she is diagnose with large lumbar hernia with overlying previous surgery scar and 2.8 cm caluli with dilated pelvi calyceal system .

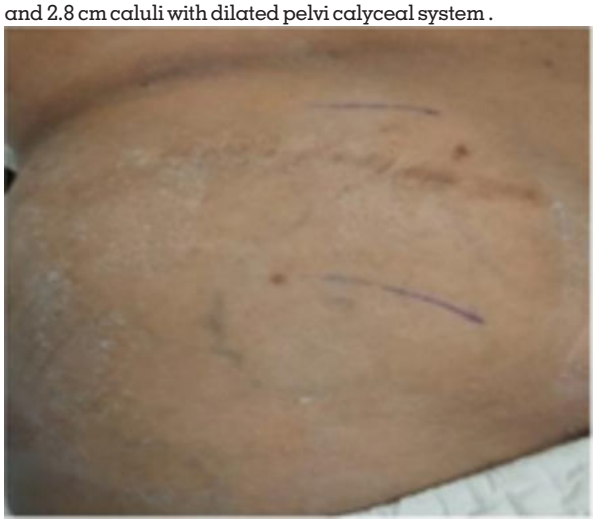

Figure 1: large right lumbar hernia

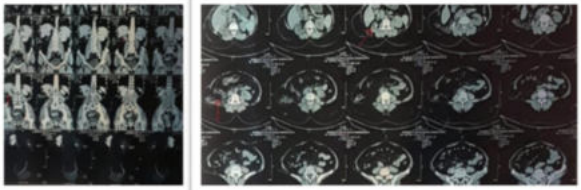

Figure 2: CT IVP Show Large Hernia With Renal Stone (red Arrow)

In this case possible treatment modalities is PCNL,ESWL, stage RIRS or Open surgery ,for large stone more than 20 mm size PCNL is best modality, howerever PCNL have limitation due to injury to aberrant vessel and internal organ. All procedure and complication related due to each procedure explain to patient and relative , finally we plan for laproscopic assited PCNL after taking informed consent. LA-PCNL was performed in general anaesthesia after anaesthesia 6 french ureteric catheter inserted in right ureter, then left semi flank position given 3 laproscopic port inserted one 10 mm just right lateral to umbilicus and two 5 mm in right pararectal muscle and subcostal region.

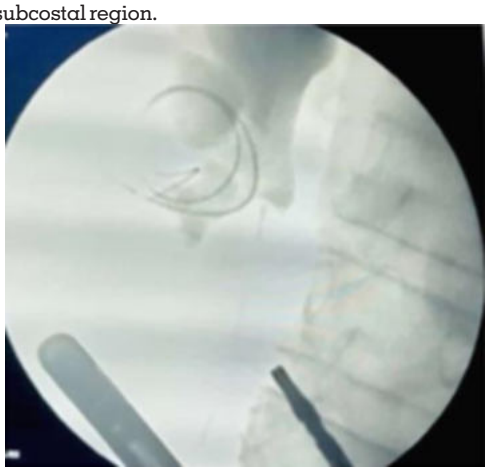

Figure 4: RGP with Guide wire in situ

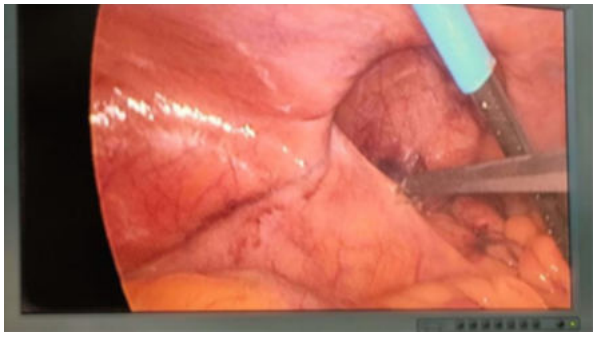

Figure 5: Hernia sac with amplaz sheath in situ(laproscopy view)

small bowel content from hernia sac reduce and right kidney expose, right RGP done and renal calyx delineated under fluoroscopy and lower calyx puncture under fluoroscopy and laproscopy assisted (figure 4 and 5) initial puncture needle inserted with external skin marking medial to posterior axillary line subcostal ,tract dilated upto 21 french amplaz sheat ,stone fragmented with lithoclast fragment removed and 6/26 dj stent inserted antegrade 20 french nephrostomy tube inserted, abdomen desufflated and port was closed with skin suture, there where no perioperative complication ,

Figure 6: Post Operative X-ray With DJ Stent In Situ With Nephrostomy Tube

postoperative control abdominal x-ray done with DJ stent and nephrostomy tube in situ (figure 6), patient was discharged on 3rd post operative days with normal laboratory value ,DJ stent removed after 21 days with normal sonography and renal function test.

Informed consent taken from patient about procedure and complication due to procedure and agreement to publication of this case report and image.

DISCUSSION:

the lifetime prevalence of renal stone disease is 1-15% however present of recurrent renal stone with large lumbar hernia due to previous pylolithotomy is rare, treatment modality in this case is PCNL,ESWL,flexible ureteroscopy and open surgery.PCNL is best option for stone larger thn 20 mm but PCNL have limitation due to complication and damage to internal organ.in our case we found that laproscopic assisted PCNL is safe and technically feasible procedure for treatment of renal stone with large lumbar hernia.

To the best of our knowledge this is the first report of laproscopy assisted PCNL in large lumbar hernia with prior history of open pyelolithomy.

CONCLUSION:

Laproscopy assisted PCNL seems to be safe and feasible minimal invasive technique of choice in special case of recurent renal stone with large lumbar hernia.

REFERENCES:

1. Etemadian M, Maghsoudi R, Abdollahpour V, Amjadi M. Percutaneous nephrolithotomy in horseshoe kidney: our 5-year experience. Urol J. 2013;10(2):856–860
2. Eshghi AM, Roth JS, Smith AD. Percutaneous transperitoneal approach to a pelvic kidney for endourological removal of staghorn calculus. J Urol. 1985;134(3):525–527. doi:10.1016/S0022-5347(17) 47274-0
3. Santos ARD, Rocha Filho DC, Tajra LC. Management of lithiasis in pelvic kidney through laparoscopy- guided percutaneous transperitoneal nephrolithotripsy. Int Braz J Urol. 2004;30(1):32–33; discussion 34. doi:10.1590/S1677-55382004000100007
4. Maheshwari PN, Bhandarkar DS, Shah RS, Andankar MG, Saple AL. Laparoscopy-assisted transperitoneal percutaneous nephrolithotomy for recurrent calculus in isthmic calix of horseshoe kidney. J Endourol. 2004;18(9):858–861. doi:10.1089/end. 2004.18.858
5. Wang X, Li S, Liu T, Guo Y, Yang Z. Laparoscopic pyelolithotomy compared to percutaneous nephrolithotomy as surgical management for large renal pelvic calculi: a meta-analysis. J Urol. 2013;190 (3):888–893. doi:10.1016/j. juro.2013.02.092.