VOLUME - 12, ISSUE - 01, JANUARY - 2023 • PRINT ISSN No. 2277 - 8160 • DOI : 10.36106/gjra

Original Research Paper

Epidemiología

MOHS SURGERY: NARRATIVE REVIEW

Steffany Andrea Meza Rengifo	MD. Universidad Cooperativa de Colombia
Jonathan David Linares	MD (E). Universidad Nacional de Colombia
Darío Fernando Ortega Vallejo	MD. Universidad del Valle
Zahyra Carolina Astudillo Díaz	MD. Fundación Universitaria Sanitas
Erika Alejandra Rodríguez Velásquez	MD. Fundación Universitaria Juan N. Corpas

ABSTRACT Mohs micrographic surgery (MMC) is a specialized surgical and anatomopathological procedure whose purpose is to eliminate skin cancer trying to preserve the greatest amount of healthy tissue while controlling the tumor margin; is the method of choice for the treatment of non-melanoma skin cancers such as basal cell carcinoma (BCC) or squamous cell carcinoma (SCC), however there is evidence that supports its use in less frequent tumor,, including those tumors that are not well defined clinically and have a high risk of recurrence due to their histology and anatomical location.

KEYWORDS : Mohs micrographic surgery, skin cancer.

INTRODUCTION

Mohs micrographic surgery (MMC) is a specialized surgical and anatomopathological procedure whose purpose is to eliminate skin cancer trying to preserve the greatest amount of healthy tissue while controlling the tumor margins (1); is the method of choice for the treatment of non-melanoma skin cancers such as basal cell carcinoma (BCC) or squamous cell carcinoma (SCC), however there is evidence that supports its use in less frequent tumors (2), including those tumors that are not well defined clinically and have a high risk of recurrence due to their histology and anatomical location. This technique has been shown to have high 5-year cure rates of 99% for primary basal cell carcinoma and 97% for primary squamous cell carcinoma (3).

METHODS

This narrative review was based on a search strategy that was carried out in databases such as PubMed/Medline, Lilacs and Redalyc, EBSCO. The MeSH and DeCS thesauri were used. Articles such as clinical trials, systematic reviews, topic reviews between the years of 1999 and 2022 were included (**Figure 1**).

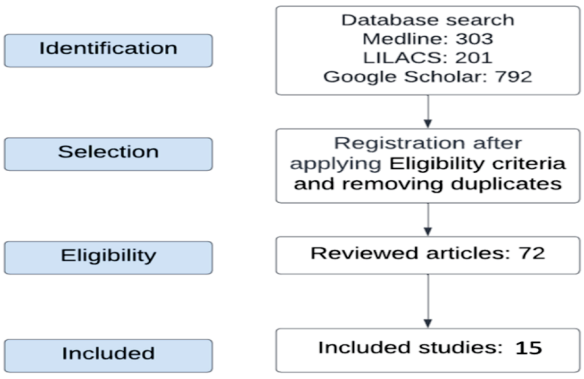

Figura 2. PRISMA

History

Initially called "chemosurgery" or "fixed tissue technique", it was developed by Dr. Frederick E. Mohs in 1932. This technique consists of applying zinc chloride paste to the tumor lesion 24 hours prior to surgical removal of the tumor. In order to perform the fixation and observation under the microscope, since this paste preserves the histological characteristics of the cells, which facilitates their microscopic analysis. If the persistence of tumor tissue was evident in the margins, zinc chloride was applied again 24 hours before perform the resection again(3), the same procedure was performed until the lesion was completely removed; however, one of the drawbacks involved in using this technique, in addition to the longer time required for total removal of the tumor, is the tissue necrosis caused by zinc chloride and consequently the complications in surgical reconstruction, due to this, Dr. Mohs thought about ci wound catrization by secondary intention, which has been shown to have an acceptable aesthetic result, especially on concave surfaces (1). Over the years, the zinc chloride fixation technique evolved into the fresh-frozen tissue technique currently used (2), which has better benefits as tumor resection can be done in a single day and reconstruction Surgery is immediate due to the absence of necrotic tissue because zinc chloride is not previously administered to the lesion.

Technique

This technique seeks the complete surgical removal of the tumor lesion through precise mapping that helps to preserve the greatest amount of healthy tissue through four fundamental pillars that are: surgical excision, histopathological examination, mapping and treatment of the wound (1).

Local anesthesia is used at the clearly demarcated surgical site, clinically evident tumor is excised with a scalpel or curette, the disc-shaped cut is made with notches for easy orientation and to create a tissue map by marking with ink the jagged edges, the sample is taken to a cryostat where it is

frozen and later the histopathological examination is performed with staining of hematoxylin-eosin or toluidine blue to analyze several thin sections of the bottom of the sample through the microscope; for this, a beveled cut is made in the surgical margin which ensures a complete analysis of the sample since it leaves the edges and the bottom in the same plane; on the other hand, the mapping must be precise and mark the tumor remnants in the lesion graph and repeat the excision of the tumor area if indicated, this procedure is repeated until the tumor is not detected microscopically; Lastly, the treatment of the wound can be closed surgically with an adequate reconstruction or healed by secondary intention, depending on the case (4).

Indications

In 2012, the American Academy of Dermatology and the American College of Mohs Surgery developed a report in which they described the criteria for appropriate use (CUA) of Mohs surgery according to the characteristics of the patient and the tumor, which They are intended to help guide decision-making for dermatological treatment, through the qualification of each indication where they can be considered as: appropriate if they have a score of 7 - 9, which suggests that they are accepted, uncertain if their score is between 4 - 6 which suggests that it can be accepted however it needs more investigation, and finally the rating of inappropriate that has a score of 1 - 3 that considers that it is not acceptable, this is because there is not enough data to categorize them and not because Mohs surgery is not appropriate (5).

Within the indications that are accepted to perform Mohs surgery in terms of tumor characteristics, it is taken into account if it is recurrent, if it is anatomically located in a high-risk area, such as: Area H, which refers to the central part of the face, eyelids, eyebrows, nose, lips, chin, ear, periauricular grooves, temples, anogenital region, hands, feet, nail units, ankles, and nipples/areolas; area M consisting of cheeks, forehead, scalp, neck, jaw and pretibial surface, if it is located in a previous scar, what is called "Marjolin's ulcer"; if they are large (>2 cm in diameter), have ill-defined borders, if they are fast-growing, if they are of an aggressive histological type; for CBCs that are morpheiform, basosquamous micronodular, or infiltrative, on the other hand, if the CECs are deeply penetrating, poorly differentiated, or undifferentiated, if they present small, clear, spindle cells.

Regarding the characteristics of the patient that were taken into account for the indications for performing Mohs surgery, those people who have been previously exposed to ionizing radiation, who present a condition that generates immunosuppression such as HIV, organ transplants, are taken into account., haematological malignancy or pharma cological immunosuppression; if you have underlying genetic syndromes such as xeroderma pigmentosa, basal cell nevus syndrome or Bazex-Dupré-Christol syndrome.

According to the National Comprehensive Cancer Network, in its treatment guidelines for non-melanoma skin cancer, they indicate that when deciding on mohs micrographic surgery as a treatment for the tumor, the risk assessment of this is taken into account since it is indicated in those tumors of "high risk" according to their location, either in the H zone or in areas where it is necessary to preserve tissue to maintain the possible physical and aesthetic function, in those that arose in irradiated skin or in a scar, those that have a diameter >20mm, have an aggressive histological pattern, poorly defined borders, rapid growth, those that are recurrent or poorly excised, if there is presence of neurological compromise. On the other hand, there are no absolute contraindications for MSC as a treatment; however, it is important to assess tolerance to the local anesthetic, the presence of conditions that require general anesthesia, and the presence of psychological and mental compromises, so it is advisable to individualize the patient. patient, since the circumstances of each one of them are different (6).

In Spain, there is a national registry of those patients who were evaluated and submitted to Mohs surgery, which is called the REGESMOHS registry, from which Ruiz et al. made a description of patients evaluated between July 2013 and October 2016 who were not considered suitable for the use of this treatment, since their tumors were primary, they were patients older than 70 years, tumors greater than 11 mm in the major axis and 10 mm in the minor axis, however, they determined that the main reasons for not performing the surgery were the presence of some medical contraindication and that the tumor was low risk (7).

Advantages and disadvantages

The use of this technique as a treatment favors the aesthetics of the patient since it has the ability to try to preserve the greatest amount of healthy tissue, in addition to not being necessary to use general anesthesia to perform the procedure, which makes it safer for the patient. and allows it to be performed on an outpatient basis, it also offers cure rates higher than traditional surgical excision (8); however, there is evidence that this procedure may have limitations, among which are: The possibility of not achieving complete removal of the tumor margins, especially when there is infiltration of underlying structures such as bone; the analysis of the samples on the slide may be more difficult in those patients diagnosed with chronic lymphocytic leukemia, there may be discrepancies in histopathological interpretations, the short knowledge on the part of medical personnel regarding the treatment of skin cancer makes it impossible to properly choose the surgical technique, finally the scarcity of cost-effective studies of the technique delimit its implementation in the health system, which makes access to this treatment difficult for people with low socioeconomic resources (6).

Adverse effects or complications

Intraoperatively complications are rare, however, they can occur, Murillo et al. analyzed the REGESMOSH registry and identified that vasovagal syncope, arterial hypertension, bleeding, hyperglycemia or unspecified arrhythmias can occur, most of these complications are resolved immediately (8). Mohs surgery is considered incomplete if the tumor margins continue positive, Oro et al. studied the data from the REGESMOHS registry of those patients who underwent incomplete Mohs surgery to define the risk factors for recurrence, which is expressed as the incidence rate.

In these cases, they were able to identify three predictive factors for recurrence, which are: increasing age, since for each year of age there was an increase of 6%, a short period between diagnosis and surgery, and the need for hospitalization; It was possible to conclude that the overall incidence rate is eight times higher in incomplete Mohs surgery than in complete MSC and it is probable that 24% of these patients undergo recurrence and require complementary therapies (9).

Complicated Mohs micrographic surgery is considered when more than three surgical stages are necessary for the removal of the tumor. When this technique is complicated, different variables influence it, such as the size of the defect, sex, the time elapsed after performing the MSC and the reconstruction. of the defect (10), for which reason it is difficult to know exactly when it can occur, due to this Nätterdahl et al. conducted a study where they analyzed prospective data from patients who underwent MSC between January 2009 and October 2020 in southern Sweden in order to identify risk factors for complicated Mohs surgery and thus better plan the intervention. Advanced age, prior treatment with cryotherapy

or Mohs surgery were found as risk factors, and tumor location and histopathological subtype were not associated with complications (11).

Postoperative complications are not frequent, they generally occur in 1-19% of cases (12), among which are: hematomas, infection, dehiscence of the suture and partial or total loss of the graft or flap, in which 2018 Miller et al. conducted a retrospective cohort study analyzing patients from a single institution who were diagnosed with BCC and SCC who underwent Mohs reconstructive surgery whose reconstructions were performed between 24 hours to 32 days after MSC between January 2012 and March 2017, the analysis of these data found no association between late reconstruction and risk of infection or flap necrosis, nor was it possible to relate the use of anticoagulants and antiplatelet drugs to post-surgical complications, however, a relationship was found between smoking, size and thickness of the defect, interpolated flaps with cartilage grafts or the use of composite cartilage with postoperative complications.

Perioperative management

In a review of the literature by Bittner et al. analyzed the perioperative management of Mohs surgery in different articles from which they manage to conclude the following considerations (13):

Antibiotic

Generally, prophylactic management with antibiotics is not required, however, in some cases it is indicated, such as in surgeries performed on the lower extremities and groin, when the excision is performed in a wedge in the ear or lip, when Nose flaps or grafts will be performed as it reduces the likelihood of surgical site infection, the risk of endocarditis, and the risk of prosthetic infection. If the antibiotic was not previously administered, it can be administered up to two hours after surgery. The antibiotics that are usually used are administered orally and are: Cephalexin 2 gr, and if you are allergic to cephalosporins and penicillins, use clindamycin 600 mg (13).

Miller et al. indicate that the prescription of antibiotics by dermatologists has increased between 2008 and 2016, however, the prescription of these is not found in practical management guides or scientific evidence. The American Academy of Dermatology does not make clear the use of antibiotics, so their prescription is made at the consideration of the treating physician; some authors do not advise the use of topical antibiotics (14).

Anticoagulant and antithrombotics

It is estimated that between 25 and 28% of the patients who will undergo this procedure are prescribed antithrombotics, especially warfarin and aspirin. There is evidence that clopidogrel is more likely to cause bleeding than aspirin; however, bleeding is not life-threatening and can be controlled, so it is recommended that if the patient has a history of thrombotic events and is on therapy antithrombotic as secondary prevention, the drugs should be continued, on the contrary, if they are used as primary prevention, it is recommended to suspend them 14 days before the procedure and resume it 1 week later, since it can affect the surgical result (13)(15).

Quality of life

A large part of the percentage of tumors removed with this technique are repaired with primary closure, which is associated with fewer complications and less postoperative pain, which favors the patient's quality of life at the time of recovery, in addition to seeking to preserve the greater amount of tissue, which maintains the functionality of the tissue and its aesthetics, in addition to low recurrence rates, since this technique completely studies the edges of the tumor, which favors its complete removal; however, we must remember that margins may remain that the success of the surgery depends on the expertise of the treating physician (13).

1. REFERENCES

1. Bolognia JL, Schaffer JV, Cerroni L, editores. Dermatología: Principales Diagnósticos Y Tratamientos. 4a ed. Elsevier; 2018.
2. Rodríguez-Jiménez P, Jimenez YD, Reolid A, Sanmartın-Jimenez O, Garces JR, Rodríguez-Prieto MA, et al. State of the art of Mohs surgery for rare cutaneous tumors in the Spanish Registry of Mohs Surgery (REGESMOHS). Int J Dermatol [Internet]. 2020;59(3):321–5. Disponible en: http://dx. doi. org/ 10. 1111/ijd.14732
3. Cortés-Peralta EC, Garza-Rodríguez V, Vázquez-Martínez OT, Gutiérrez-Villarreal IM, Ocampo-Candiani J. Cirugía micrográfica de Mohs: 27 años de experiencia en el Noreste de México. Cir Cir [Internet]. 2017;85(4):279–83. Disponible en: https://www.sciencedirect.com/science/article/pii/S0009741116301037
4. Tolkachjov SN, Brodland DG, Coldiron BM, Fazio MJ, Hruza GJ, Roenigk RK, et al. Understanding mohs micrographic surgery. Mayo Clin Proc [Internet]. 2017 [citado el 18 de diciembre de 2022];92(8):1261–71. Disponible en: https://www.mayoclinicproceedings.org/article/S0025-6196(17)303 129/ fulltext
5. Ad Hoc Task Force, Connolly SM, Baker DR, Coldiron BM, Fazio MJ, Storrs PA, et al. AAD/ACMS/ASDSA/ASMS 2012 appropriate use criteria for Mohs micrographic surgery: a report of the American Academy of Dermatology, American College of Mohs Surgery, American Society for Dermatologic Surgery Association, and the American Society for Mohs Surgery. J Am Acad Dermatol [Internet]. 2012;67(4):531–50. Disponible en: http://dx.doi. org/10. 1016/j.jaad.2012.06.009
6. Torres JV, Cabrera Correa FA, Molina M. Mohs micrographic surgery. Progress to 2020 [Internet]. Ciplastica.com. [citado el 29 de diciembre de 2022]. Disponible en: https://www.ciplastica.com/ojs/index. php/rccp/article/ viewFile/173/pdf
7. Ruiz-Salas V, Garcés JR, Alonso-Alonso T, Rodríguez-Prieto MA, Toll-Abelló A, Eusebio Murillo E, et al. Actas Dermosifiliogr [Internet]. 2018;109(4):346–50. Disponible en: http://dx.doi.org/10.1016/j.ad.2017.11.008
8. De Eusebio Murillo E, Martín Fuentes A, Ruiz-Salas V, Garcés JR, Miñano Medrano R, López-Estebaranz JL, et al. Actas Dermosifiliogr [Internet]. 2017;108(9):836–43. Disponible en: http://dx.doi.org/10.1016/j.ad.2017.04.018
9. Oro-Ayude M, González-Sixto B, Sanmartin-Jiménez O, Garcés JR, Rodríguez-Prieto MA, Ruiz-Salas V, et al. Incomplete Mohs surgery: a long-term, nationwide prospective cohort to describe recurrence rate and risk factors (REGESMOHS, Spanish Registry of Mohs Surgery). J Eur Acad Dermatol Venereol [Internet]. 2022;36(1):e35–7. Disponible en: http://dx.doi. org/10.1111/jdv.17597
10. Montero-Vilchez T, Rodriguez-Tejero A, Tercedor-Sanchez J. FR - Cirugía micrográfica de Mohs. ¿Cierre inmediato o cierre diferido? Actas Dermosifiliogr [Internet]. 2021;112(9):849–50. Disponible en: https://www. sciencedirect.com/science/article/pii/S0001731021001782
11. Nätterdahl C, Kappelin J, Persson B, Lundqvist K, Ahnlide I, Saleh K, et al. Risk factors for complicated Mohs surgery in the South Sweden Mohs Cohort. J Eur Acad Dermatol Venereol [Internet]. 2022;36(7):1113–7. Disponible en: http://dx.doi.org/10.1111/jdv.18124
12. Miller MQ, David AP, McLean JE, Park SS, Christophel J. Association of mohs reconstructive surgery timing with postoperative complications. JAMA Facial Plast Surg [Internet]. 2018;20(2):122–7. Disponible en: http://dx.doi.org/ 10. 1001/jamafacial.2017.1154
13. Bittner GC, Cerci FB, Kubo EM, Tolkachjov SN. Mohs micrographic surgery: a review of indications, technique, outcomes, and considerations. An Bras Dermatol [Internet]. 2021;96(3):263–77. Disponible en:https://www. sciencedirect.com/science/article/pii/S0365059621000763
14. Miller MQ, Stevens JS, Park SS, Christophel JJ. Do postoperative antibiotics affect outcomes in Mohs reconstructive surgery? Laryngoscope [Internet]. 2021;131(2):E434–9. Disponible en: http://dx.doi.org/10.1002/lary.28700
15. Nguyen TA, Rowe G, Harris K, Ko S, Ko M, Gharavi NM. Antibiotic use and surgical site infections in immunocompromised patients after Mohs micrographic surgery: A single-center retrospective study. Dermatol Surg [Internet]. 2022 [citado el 31 de diciembre de 2022];48(12):1283–8. Disponible en: https://journals.lww.com/ dermatologicsurgery/ pages/ articleviewer. aspx?year=2022&issue=12000&article=00004&type=Abstract