



## A CURIOUS CASE OF URETHRAL INTERCOURSE WITH A VAGINAL STONE: A CASE REPORT AND REVIEW OF LITERATURE

**Dr Gunjan Bahuguna\***

Obstetrics and Gynaecology, Grant Medical College, Mumbai, IND  
\*Corresponding Author

**Dr Dhananjay Sahstrabudhe**

Obstetrics and Gynaecology, Grant Medical College, Mumbai, IND

**Dr Shilpi Goel**

Obstetrics and Gynaecology, District Hospital Pauri, Pauri, Garhwal, IND

**Dr Nidhi Kurkal**

Obstetrics and Gynaecology, Grant Medical College, Mumbai, IND

**Dr Ashok Anand**

Obstetrics and Gynaecology, Grant Medical College, Mumbai, IND

### ABSTRACT

Urethral intercourse is rare and there have been a handful of cases described in literature. The various causes identified for urethral intercourse are obstructive genital anatomy where vaginal intercourse was not possible or social factors like ignorance of normal genital anatomy. Stone formation in the vagina is because of stasis of urine or blood along with superadded infection. This is an interesting case of urethral intercourse with an incidental finding of a vaginal stone in a patient who had been operated for a common cloaca in the past. The stone from removed from the vagina and she was counselled regarding safe sex practices resulting in successful vaginal sex.

**KEYWORDS :** female, sexual dysfunction, urinary incontinence, urethral coitus, urethral intercourse

### INTRODUCTION

Urethral intercourse is an extremely rare phenomenon and has been associated with Mullerian anomalies. Many women can present with dyspareunia, urinary complications like urinary incontinence and repeated urinary tract infections. Careful history-taking is important to find the associated urinary symptoms and a detailed urogynaecological examination can reveal a megalourethra with incontinence of urine [1]. Because of the pliability of the urethra sexual intercourse is possible and the integrity of the urethral sphincter is achieved back when the urethra is given rest and no further urethral intercourse is performed [2]. However, the incontinence of urine can persist and some of the patients may require sling surgery [1].

Primary vaginal stones are very rare. The pathophysiology behind stone formation is an obstruction to the flow of menstrual blood or urinary stasis with bacterial action [3]. Vaginal calculus has been seen in cases of complex urological and Mullerian anomalies, neuropathic bladder, uterovaginal fistulas, Protein C deficiency, and neurodegenerative disorders [4]. Cases usually present with recurrent vaginal infections, difficulty in having sexual intercourse. X-ray of the pelvis can delineate a calculus but it's difficult to know the exact location. Further, a CT of the pelvis or an MRI can tell us the location of the calculus and the associated urological or Mullerian anomalies. Management involves the removal of the stone which can be performed depending on the location and the associated anomalies. For instance, a vaginoplasty and a urethroplasty were performed for vaginal calculus in a patient with a urogenital sinus anomaly [5].

This case report describes an interesting case of urethral intercourse in a woman with a reconstructed vagina after having a congenital common cloaca and was incidentally found to have a foreign body in the vagina. Patient education, counselling and safe sex advice solved this case.

### Case Presentation

A 32-year-old lady presented to us with difficulty in having sexual intercourse. She also mentioned that she would have urinary incontinence during the act of sexual intercourse, and the act had been extremely painful. According to her husband penetration had been very difficult and she described probably her "vaginal opening as tiny". She recently had a

urinary tract infection and was treated with antibiotics. She had been recently married 2 months ago and her periods had been regular. She also described having on- and-off vaginal discharge for quite some time. Her past surgical history included that she was born with common cloaca and had phased reconstruction operations as a baby, which included a sigmoid colostomy initially, followed by a posterior sagittal approach for ano-recto-urethro-vaginoplasty (PSARUVP). She had post-operative anal and vaginal dilatation, followed by colostomy closure when she was about 6 months to 5 years of age. As a follow-up, she had a CT scan in a private hospital which showed a foreign body possibly in the vagina (image E).

On examination, she was of average build and had normal female secondary sexual characteristics. A pelvic examination showed a dilated and patulous urethral opening and a small vaginal opening (image A). After verbal consent and the presence of a chaperone, a gentle vaginal examination was performed, and the vaginal opening was found to be stenosed (image A). Gently, artery forceps was introduced inside the vagina and a kinking sound could be heard on striking the foreign body. A rounded foreign body measuring 3 cm x 2 cm approximately was identified and removed with the help of artery forceps and sent to the laboratory for culture and sensitivity (image C, D). Because the vagina was stenosed, the speculum could not be inserted, and the vaginal mucosa and cervix could not be visualised.

The patient and her husband were educated about female anatomy and counselled that probably sexual intercourse was carried out through the urethral opening rather than the vaginal opening. Taking the help of lubricants to aid in penetration was also discussed. She was given vaginal dilators to dilate the vaginal opening. On follow-up, the couple had been successful in having vaginal penetration and the patient was started on culture-sensitive antibiotics. On further follow-up in 2 months' time, the couple were happy and seemed satisfied.

### DISCUSSION

#### Background

The first case of urethral intercourse in a lady with a fibrotic hymen was published in the year 1965 by Zeigerman et al [6]. About 30 cases of urethral intercourse have been reported in the literature [2].

## Causes Of Urethral Intercourse

### Anatomical Causes

Most of them have been found associated with obstructive Mullerian anomalies including vaginal agenesis and abnormalities with hymen formation [2]. A rare case of urethral coitus with a microhymen was described by Donato et al [7]. An interesting case of urethral-vaginal fistula formation because of traumatic urethral intercourse in a patient with vaginal hypoplasia has been described by Verma et al [8] by a magnetic resonance fistulogram. A case of bowel evisceration following the rupture of the bladder in a paraplegic patient with a chronic indwelling Foley catheter has been described in the literature, here the urethra might have been enlarged to facilitate urethral intercourse [9].

### Other Causes

However, there have been cases described with normal pelvic anatomy [10] where ignorance might have been the cause. It was assumed that normal coitus was difficult or not achievable because ignorance of basic female anatomy might be one of the causes of urethral intercourse. Okeke et al [11] have described urethral laceration because of violent urethral intercourse in a rape survivor.

In our case, whether vaginal sexual intercourse was not performed because of the foreign body in the vagina or because of sexual ignorance is unclear. The reconstructed vaginal opening was stenosed and postoperative fibrosis was another attributable factor.

### Clinical Presentation

Most of the cases of urethral coitus presented with urinary incontinence, urinary tract infections, infertility, pelvic pain and sexual dysfunction. In our case, the main presenting symptom was painful sex with vaginal penetration not possible.

### Management Of Urethral Coitus

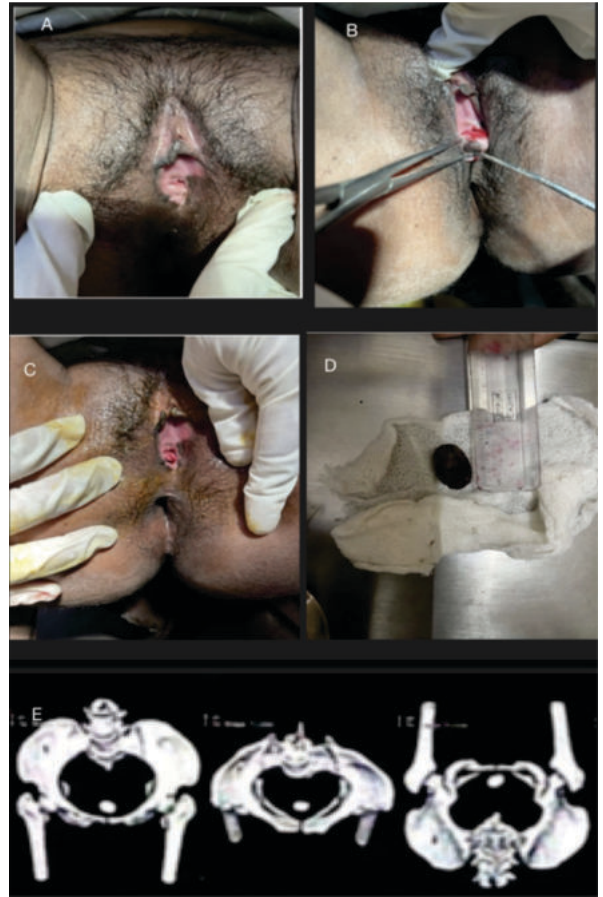
Management of urethral coitus revolves around knowing the cause and individualised treatment thereafter. In cases of absent vagina, it involves the creation of a neo-vagina [2]. Various types of vaginoplasties have been described in the literature involving flaps and the sigmoid colon. Post-operative counselling and vaginal dilation is required to keep the vagina patent and prevent stenosis of the neovagina.

Giving rest to the urethra helps in restoring the function of the urethra and maintaining sexual function through the vagina helps in some patients as shown in literature [12]; which is similar to our case.

Urethral plication to restore normal urethral anatomy and physiology has been described in some cases [12]. Urinary incontinence has been described in some studies to be treated with sling procedures [2]. However, in our case, the incontinence improved soon after urethral intercourse was refrained and the urethra was given rest.

### Vaginal Calculus

The incident finding of a vaginal foreign body which looked like a stone in our case was probably because of retention of blood with persistent vaginal infection possibly leading to stone formation. Vaginal calculus has been described in the literature with patients with urogenital tract anomalies where stasis of urine, along with urine infection paved stone formation [5]. A similar case has been described in the literature with vaginal stone formation by Ergun et al [13]. CT pelvis is very helpful in knowing the site of the calculus and planning the management [5]. CT was the modality of choice in our case as well, because she had already had genital reconstruction. CT was quicker and cheaper than an MRI in our case and was therefore preferred.



**FIGURE 1:** A Examination Showing Dilated Urethra, B Vaginal Calculus Removal, C Post Calculus Removal, D Vaginal Calculus 3cm X 2cm, E CT Suggestive Of Possible Calculus In The Vagina

### CONCLUSIONS

Even though urethral coitus is very rare, a patient presenting with urinary symptoms and sexual dysfunction with a background of Mullerian agenesis or genital reconstructive surgeries may point towards urethral intercourse. A detailed sexual history and thorough examination hold the key to the diagnosis. Patient counselling and safe sex education help in the understanding of urethral intercourse. The urethra can regain its normal function in due course of time when it's given rest.

### Additional Information

#### Disclosures

**Human Subjects:** Consent was obtained or waived by all participants in this study. **Conflicts of Interest:** In compliance with the ICMJE uniform disclosure form, all authors declare the following: **Payment/Services Info:** All authors have declared that no financial support was received from any organization for the submitted work. **Financial Relationships:** All authors have declared that they have no financial relationships at present or within the previous three years with any organizations that might have an interest in the submitted work. **Other Relationships:** All authors have declared that there are no other relationships or activities that could appear to have influenced the submitted work.

### REFERENCES

1. Bilim, V., Watanabe, et al.: Megalourethra and bladder foreign body in a female patient. *Clinical Case Reports*. 2023, 11:6. 10.1002/ccr3.7528
2. Djordjevic, M. L., Bizic, et al.: Treatment of Urethral Intercourse and Impact on Female Sexual Function. *Sexual Medicine*. 10. <https://doi.org/10.1016/j.esxm.2022.100534>
3. Jo, J, Lee, et al.: Huge vaginal stone: Case report and review of the literature. *Frontiers in Surgery*. 2022, 9:10.3389/fsurg.2022.937371

4. Dudhani, S., Sinha, et al.: Giant colpolithiasis in urogenital sinus anomaly with urethral duplication: A case report and review of literature. . *African Journal of Paediatric Surgery*. 2023, 0: 10.4103/ajps.ajps\_89\_22
5. Xu, Q., & Zou, et al.: Primary vaginal calculus in a woman with urogenital sinus anomaly: A case report. . *BMC Urology*. 2020, 20:1. 10.1186/s12894-020-00708-0
6. Zeigerman, J. H., & Gillenwater, J. Y. (n.d): Coitus per Urethram and the Rigid Hymen. .
7. Di Donato, V, Mancini, et al.: Urethral Coitus in a Patient with a Microperforate Hymen. *Journal of Minimally Invasive Gynecology*, 15, 642-643.
8. Verma, A., Vyas, et al.: Magnetic Resonance Fistulogram Demonstration of Urethrovaginal Fistula in a Case of Müllerian Agenesis Due to Traumatic Urethral Coitus. *Journal of Minimally Invasive Gynecology*. 19:259-261.
9. Brown, E. T., Koski, M. E., & Lacour, S. M. (2012): Bowel Evisceration Through the Bladder Neck in a Paraplegic Female Secondary to Urethral Coitus. *Journal of Sexual Medicine*. 9:1226-1228.
10. Aksakal, O. S., Cavkaytar, et al.: Urinary incontinence due to urethral coitus in a multiparous woman. *Female Pelvic Medicine and Reconstructive Surgery*, 21. 39-40. 10.1097/SPV.0000000000000166
11. Okeke, L. I., Aisuodionoe-Shadrach, O., & Ogbimi, A. I. (2007): Female urethral and bladder neck injury after rape: An appraisal of the surgical management. *International Urogynecology Journal*, 18, 683-685. . 10.1007/s00192-006-0193-8
12. Ryckman, J., Black, A., & Fleming, N. (2014): Adolescent urethral coitus: 2 Cases and review of the literature. . *Journal of Pediatric and Adolescent Gynecology*, 27.
13. Ergün, S. S., Babalioglu, et al.: Vaginal stones with a pinpoint hymenal opening. *Archives of gynecology and obstetrics*. 266:58-59.