



A RETROSPECTIVE STUDY ON THE EFFICACY OF DIAGNOSTIC HYSTERO-LAPAROSCOPY

Dr. Parvathy Prakash

Junior Resident, Department of OBG, KVG Medical College and Hospital Sullia, Dakshina Kannada.

Ravikanth G O

Additional Professor, Department of OBG, KVG Medical College and Hospital Sullia, Dakshina Kannada.

Geeta Jagannath Doppa

Professor and Head of Department, Department of OBG, KVG Medical College and Hospital Sullia, Dakshina Kannada.

ABSTRACT

Introduction: Infertility affects about 10-15% of reproductive age couples. The diagnosis and treatment of this disorder stands out as one of the most rapidly evolving area in medicine. Inability to conceive bears a social stigma which causes societal repercussion and personal suffering. The advent of hystero-laparoscopy have redefined the evaluation and treatment of infertile women. **Objective:** To assess the role of hystero-laparoscopy in the evaluation of female infertility. **Methodology:** A retrospective study of the 100 case who underwent diagnostic hystero-laparoscopy for infertility between June 2020 to June 2023 in the department of Obstetrics and Gynecology, K.V.G. Medical College & Hospital, Sullia. Women aged 20-40 years with normal hormone profile without male factor infertility were included. After taking thorough history, clinical examination, initial assessment and all necessary investigations, patients were advised to report postmenstrually in the proliferative phase for diagnostic hystero-laparoscopy. **Results:** Out of 100 infertile patients, 78(78%) women had primary infertility and rest 22(22%) women had secondary infertility. In primary infertility group, the most common abnormality found by laparoscopy was fibroid uterus in primary infertility group seen in 23 patients (29.48%) and fibroid uterus and endometriosis in secondary infertility group seen in 4 each (18.18%). The most common pathology seen in hysteroscopy was polyp/myoma in 19 cases (24.35%) followed by uterine anomaly in 16.66% cases in primary infertility. In secondary infertility 5 cases (22.72%) had polyp/myoma. **Conclusion:** From our study, it is concluded that the diagnostic hystero-laparoscopy is an effective and safe tool in evaluation of female infertility. It provides direct and magnified view of pelvic organs. It is an acceptable and feasible procedure, because it has the benefit of shorter hospital stay, less post operative pain and quick return of routine activity.

KEYWORDS : Hysteroscopy, Infertility, Laparoscopy

INTRODUCTION

Infertility is defined as failure to conceive during 1 year of unprotected frequent intercourse. It affects approximately 10–15 % of couples. Leading cause of infertility includes tubo-peritoneal disease (40–50 %), ovulatory disorders (30–40 %), uterine factor (15–20 %) and male factor infertility (30–40 %) ^(1,2). The prevalence of infertility in India ranges from 3.9% to 16.8%. ⁽³⁾

Conception depends on the fertility potential of both the male and female partner. Female factors contribute 40- 45% in aetiology of infertility ⁽⁴⁾. The common factors responsible for female infertility are tubal factors, anovulatory disorders, Endometriosis, uterine and cervical factors.

Major causes according to WHO on a global basis are malnutrition, pelvic tuberculosis and puerperal infections leading to tubal blockage. Laparoscopy is an essential step and a standard procedure in the investigation and evaluation of infertile females before initiating infertility treatment. In the absence of clinical signs and symptoms suggestive of a diagnosis laparoscopy offers an excellent means through direct visualization to elucidate the hidden pathology. It has got an advantage of direct visualization of the pelvic organs and the peri-tubal status resulting in greater information as compared to hysterosalpingography and ultrasonography.

The diagnosis and treatment of infertility stands out as the most rapidly evolving area in medicine ⁽⁵⁾. The advent of diagnostic hysteroscopy have redefined the evaluation and treatment of infertile women. Diagnostic hysteroscopy is a gold standard for diagnosing tubal, ovarian, peritoneal and uterine factors ⁽⁶⁾.

Aims and Objectives of Study

Role of Hystero-laparoscopy in the evaluation of female

infertility in a tertiary care centre

MATERIALS & METHODOLOGY

This study was conducted in the Department of Obstetrics and Gynecology in a tertiary care hospital from June 2021 to June 2023 retrospectively. All the infertile patients who underwent diagnostic hystero-laparoscopy in the above mentioned period fulfilling the following criteria were included in this study.

1. Women aged 19–40 years
2. Primary or secondary infertility as per WHO criterion
3. Normal ovulatory cycles and normal serum level of TSH, FSH, LH, prolactin
4. Normal seminogram.

The data collected were demographic factors such as age, duration and type of infertility, base line hormonal profile and records of male evaluation. Intraoperative finding, surgical interventions and complications during procedure were noted. The following parameters such as tubal occlusion, peritubal, periaidnexal and dense pelvic adhesions, endometriosis during laparoscopy and abnormality of cervical canal, uterine cavity, bilateral tubal ostium and endometrium during hysteroscopy were noted.

RESULTS

- 100 patients were selected and admitted for hystero-laparoscopy. Of them, 78 (78%) patients were of primary infertility and 22 (22%) patients were of secondary infertility.
- Age is an important factor in cases of infertility. In our study, maximum number of patients 31 (39.74%) belonged to 26-30 years in primary infertility group and 13 (59%) patients belonged to 26-30 years in case of secondary infertility group.
- In our study, majority of patients had duration of infertility

of about 2-5 years accounting for 51.2% in primary infertility and 45.45% in secondary infertility group.

- Most of our patients were asymptomatic accounting 68 (68%) and came for treatment of infertility only. The most common complaint was irregular menses which was seen in 38 (48.71%) patients in primary infertility group and in secondary infertility group the most common complaint was chronic pelvic pain in 13(59.09%) patients. In present study, 58.97% in primary infertility group and 77.27% in secondary infertility group had abnormal DHL findings.
- The most common causative factor in both primary and secondary infertility was No pathology in 37 cases (37%) followed by uterine factors in 23 cases (23%) and the least accounting for peritoneal factors in 3 cases (3%).
- In our study, the most common abnormality found by laparoscopy was fibroid uterus in primary infertility group seen in 23 patients (29.48%) and fibroid uterus and endometriosis in secondary infertility group seen in 4 each (18.18%). 5 patients (6.4%) had Endometriosis in primary infertility group.
- The most common pathology seen in hysteroscopy was polyp/myoma in 19 cases (24.35%) followed by uterine anomaly in 16.66% cases in primary infertility. In secondary infertility 5 cases (22.72%) had polyp/myoma.

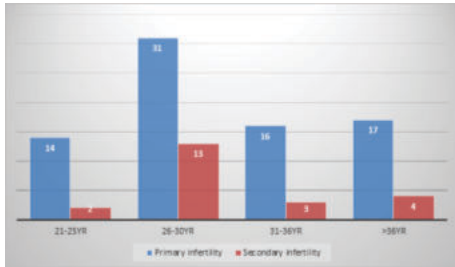


Fig 1: Age Distribution Of Patients

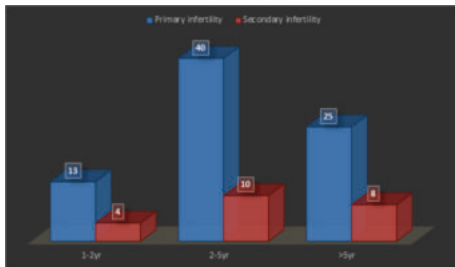


Fig 2: Duration Of Infertility

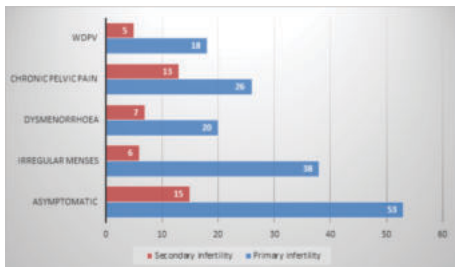


Fig 3: Presenting Complaints.

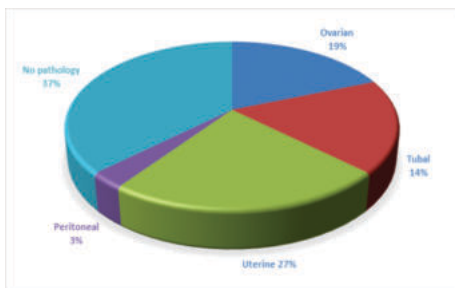


Fig 4: Causative Factors Of Infertility.

Table 1: Laparoscopic Findings

Lap findings	Primary infertility (n=78)	Secondary infertility (n=22)
Normal	32(41.02%)	5(22.7%)
PCOS	7(8.9%)	3(13.63%)
Endometriosis	5(6.4%)	4(18.18%)
Tubal block	5(6.4%)	3(13.63%)
Hydrosalpinx	5(6.4%)	1(4.5%)
Fibroid uterus	23(29.48%)	4(18.18%)
PID	1(1.28%)	1(4.5%)
Peritubal adhesions	0	1(4.5%)

Table 2: Hysteroscopic Findings

Hysteroscopic findings	Primary infertility (n=78)	Secondary infertility (n=22)
Normal study	42(53.84%)	15(68.18%)
Uterine anomaly	13(16.66%)	0
Polyp/Myoma	19(24.35%)	5(22.72%)
Synechiae	4(5.12%)	2(9.09%)

DISCUSSION

The distribution of primary infertility in our study is 78% and of secondary infertility is 22%. Usmani et al, in Rawalpindi reported 62% patients with primary infertility and 38% of patients with secondary infertility.^[7]

Age is an important factor in cases of infertility, in our study 39.74% women belonging to age group 26 – 30 years presented as primary infertility and 59% as secondary infertility. Parihar BC et al.^[8] study, maximum number of patients 39% belonged to 26-30 years in primary infertility group and 40% patients belonged to 31-36 years in case of secondary infertility group.

In our study duration of infertility among primary and secondary infertility is 2-5 years. Parihar BC et al.^[8] 54% in both primary and secondary infertility group duration of infertility accounts for 2-5 years.

The gold standard technique for diagnosing tubal and peritoneal factors of infertility is laparoscopy, which is a better predictor of future spontaneous pregnancy in infertile couples with unexplained infertility. In our study tubal and peritoneal pathology account for the 17% of infertile couples. In Kabadi et al.^[9] study 34.9% of infertile female accounts for tubal and peritoneal factors. Jayakrishnan et al.,^[10] from India detected pelvic pathology in 26.8% cases of infertile patients by laparoscopic evaluation.

Uterine pathologies are another cause of infertility in as many as 27% of couples in our study seeking treatment. 15% of infertile women was diagnosed with uterine myomas as per Nayak, et al.^[11] study. Myomas might adversely affect fertility include cornual myomas that involve or compress the interstitial segment of the tube, dysfunctional uterine contractility interfering with ovum or sperm transport or embryo implantation, and poor regional blood flow resulting in focal endometrial attenuation or ulceration

Developmental uterine anomalies have long been associated with pregnancy loss and obstetric complications, but the ability to conceive is generally not affected. Fibroid uterus was the most common intrauterine abnormality in our study, which was diagnosed by prior ultrasonography.

Laparoscopy plays an important role in visualization of peritoneal cavity and external aspect of pelvic structures. It aids in the diagnosis of pelvic – anatomic relationship, resulting from leiomyoma, Ovarian tumor, endometriosis, pelvic adhesions, fallopian tube obstruction and other rare peritoneal pathologies. The pelvic anatomic relationship is obscured by leiomyomas and ovarian tumors cannot be detected radiologically Laparoscopy is clearly the diagnostic

method of choice in these conditions.

Diagnostic hysteroscopy is also a proven method for investigating the cause of female infertility. Diagnostic hysterolaparoscopy is an "definitive daycare procedure" in evaluation of infertility. It helps in the diagnosis of specific causes of infertility, which is not diagnosed by other investigations like hormonal study, USG and HSG. It is an acceptable and feasible procedure, because it has the benefit of shorter hospital stay, less post operative pain and quick return of routine activity. Diagnostic hysterolaparoscopy can be used as an "ONETIME APPROACH" by evaluation and therapeutic procedures can also be done in the same sitting as needed.

CONCLUSION

Hysterolaparoscopy is a very useful tool that can detect various structural abnormalities in multiple sites like uterus, tubes, ovaries and peritoneal cavity in the same sitting. When done by experienced hands and proper selection of patients, hysterolaparoscopy can be considered as a definitive investigative procedure for evaluation of female infertility.

With the view of the low complication rate, minimal time requirements, dealing the abnormal finding therapeutically at the same sitting, a negligible effect in the postoperative course and significant advantage over HSG, hysterolaparoscopy should be considered as a definitive day care procedure for evaluation and treatment of female infertility.

REFERENCES

1. Jahan S. Role of laparoscopy in infertility: review article. *BIRDEM Med J.* 2012;2:99-103.
2. Howkins J, Bourine GL. The pathology of conception. In: Howkins J, Bourine GL, editors. *Shaw's text book of gynaecology.* 13th ed. New York: Elsevier; 2004.
3. Adamson PC, Krupp K, Freeman AH, Klausner JD, Reingold AL, Madhivanan P. Prevalence and correlates of primary infertility among young women in Mysore, India. *The Indian J Med Res.* 2011;134(4):440.
4. Vaid K. Pan endoscopic approach hysterolaparoscopy as an initial procedure in selected infertile women. *J Clin Diagn Res.* 2014;8:95-8.
5. Bosteels Bosteels J, Van Herendael B, Weyers S, D'Hooghe T. The position of diagnostic laparoscopy in current fertility practice. *Hum Repro Update.* 2007;13(5):477-85.
6. Yucebilgin MS, Aktan E, Bozkurt K, Kazandi M, Akercan F, Mgoyi, et al. Comparison of hydrososonography and diagnostic hyseroscopy in the evaluation of infertile patients. *Clin Exp Obstet Gynaecol.* 2004;31(1):56-8.
7. Usmani AT, Shaheen F. Laparoscopic evaluation of female infertility. *Pak Armed Forces Med J.* 1995;45(2):62-5.
8. Parihar BC et al. *Int J Reprod Contracept Obstet Gynecol.* 2019 Dec;8(12):4955-4959.
9. Khabadi YM, Harsha B. *The Journal of Obstetrics and Gynecology of India* (September-October 2016) 66(S1):S478-S481.
10. Jayakrishnan K, Koshy AK, Raju R. Role of laparohysteroscopy in women with normal pelvic imaging and failed ovulation stimulation with intrauterine insemination. *J Hum Reprod Sci* 2010;3:20-4.
11. Nayak, P et al. (2013) 'Role of diagnostic hystero-laparoscopy in the evaluation of infertility: A retrospective study of 300 patients', *Journal of Human Reproductive Sciences*, 6(1), p. 32. doi:10.4103/0974-1208.112378.