



UNEXPLAINED WATERING MIMICS AS CENTURION SYNDROME: RARE CASE REPORT

Dr Vinitkumar Mahajani*

Consultant and Pediatric Ophthalmologist, Shahu Maharaj Lions Pride Eye Hospital (CSMLP) Ichalkaranji, Kolhapur. *Corresponding Author

Dr Anas Khan

MS (Shalakyta tantra), S.V.N.H.T' s Ayurvedic Medical College and Hospital Rahuri, Ahmednagar, Maharashtra (India)

Optom Prathmesh Yadav

Bsc Clinical Optometry, Bharti Vidhyaapeeth College of Optometry (Sangli -Miraj Road), Miraj, Maharashtra, India.

ABSTRACT

Background: Centurion syndrome is a concealed and infrequent medial canthal tendon (MCT) anomaly where the patient mostly came with history of watering from both eyes. **Aim:** To narrate clinical signs, symptoms and management in a patient with Centurion syndrome. **Case History:** A 26 yr old female patient came to our OPD with history of epiphora from both eyes since more than five years. The lower eyelid outward malposition towards inferior punctum was noted. MCT abnormality seen. Medical and surgical management was advised. **Result:** Patient was less satisfied with medical treatment and refused to take surgical treatment. **Conclusion:** Centurion syndrome is very rare etiology for watering in young patient. The reduction of signs and symptoms mostly after surgical intervention like MCT set free with or without dacryocystorhinostomy (DCR).

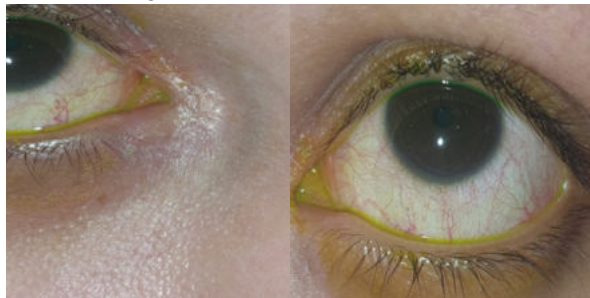
KEYWORDS : Centurion syndrome, Dacryocystorhinostomy (DCR), Epiphora, Management, Medial canthal tendon (MCT), Watering.

INTRODUCTION:

Watering may result from variation of surrounding conditions consist lacrimal hyper secretion, eyelid abnormality or irregularity of lacrimal passage. Plenty of patients who had history of epiphora due to medial canthal tendon abnormality also called as beak sign and punctum malposition. Sullivan et al in 1993 described a centurion syndrome is an idiopathic and rare medial canthal tendon abnormality where patient came with unexplained watering. The term centurion is obtaining from Roman soldier who had alike aspect. As this condition is rare and mostly unable to identify. [1] [2]

CASE REPORT:

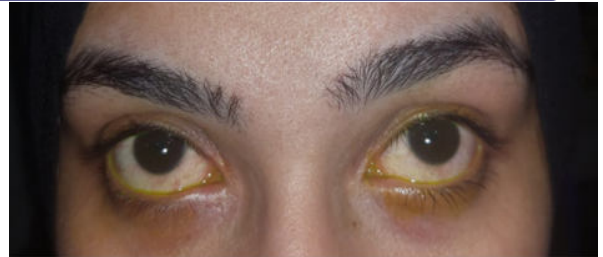A 26 year old female patient who attended outpatient department (OPD) of Lions pride eye hospital diagnosed as having centurion syndrome. She had history of on and off watering of the eyes from more than five years. The intensity of epiphora has increased with their age and has becomes continuous. There is no history of trauma, thyroid proptosis, diabetes, hypertension and discharge or regurgitation on pressure over lacrimal apparatus system (ROPLAS). On examination best corrected visual acuity (BCVA) were 6/6. The tear film height s increased. The normal height of tear meniscus (TMH) in the human eye is between 0.2 and 0.5 mm. fluorescein dye disappearance test (FDDT) shows grade 3. [3] She had a mild prominent nasal bridge; the lower eyelid punctum shows malposition and outward beak. Anterior and posterior segments are normal. We advised surgical option to patient but she refused to undergo surgery and satisfied with medical management.



A

B

Photograph A and B shows lower eyelid malposition (Beak sign)



C

Colored photograph C shows increase tear meniscus with delayed FDD test

DISCUSSION:

Centurion syndrome also called as idiopathic anterior displacement of medial canthus was first defined by T.M. Sullivan in 1933. [1] The main cause of this syndrome explained by two theories a. first is medial canthal tendon (MCT) malposition which requires surgery b. second is anatomical difference between orbit and its contents which require complicated surgical treatment. [4] R. Murthy et al [5] explained 'Beak sign' due to angulation of MCT. He also shows enophthalmos is one of the etiological factor for centurion syndrome. Different management options like MCT release, punctoplasty, medial spindle procedure, conjunctivoplasty and lower eyelid retractor plication etc.

Y Sujantha et al [6] in his study explained there is high success rate in centurion syndrome after MCT release operation. Ma'luf et al (2003) high pointed the significance of globe backward displacement occurred after MCT released, so posterior placcation is essential.[7] Chang and O Donnel (2006) described objective of surgery is to replace the eyelid and globe apposition and to reduce epiphora. The MCT is disinserted from periosteum over lacrimal sac and common canaliculi it is then suture to anterior lacrimal crest [8]. If the medial ectropion is mild, MCT release should be done first. In patients with recurrent lacrimal outflow obstruction, dacryocystorhinostomy is performed combined with release of anterior crus of MCT.

CONCLUSION:

Centurion syndrome is rare etiology of watering in young patient mostly not identified. Detail examination of punctum,

eyelid position, lacrimal pump system and nasal anatomy required to identify this case. Surgery is simple and aims at restoring eyelid globe apposition by medial canthal tendon (MCT) release alone or combined with conjunctivoplasty or punctoplasty.

Financial Support: Nil

Conflict Of Interest: None

Manuscript Category: Case report

Manuscript Presented In Other Meetings Or Conference –
No

Informed Consent: was taken from patient and parents.

REFERENCES:

1. Sullivan TJ, Welham RA, Collin JR. Centurion syndrome. Idiopathic anterior displacement of the medial canthus. *Ophthalmology* 1993; 100:328-333
2. G. S Ramesh kumar. Centurion syndrome. *International Journal of Science and Research (IJSR)*. ISSN (online):2319-7064. Paper ID :SUB151040.Volme 4, Issue 2, February 2015.
3. Zappia RJ, Milder B. Lacrimal drainage function. 2. The fluorescein dye disappearance test. *Am J Ophthalmol* 1972; 74:160-2.
4. *Lacrimal Drainage Surgery* by Suresh D. Isslor, page no: 51, first edition (2014)
5. Murthy R, Honawar S, Naik M, Menon V, Bhaduri A, Das S. Centurion syndrome: clinical presentation and surgical outcome. *Orbit* 2009. 28:269-74.
6. Sujatha Y, Sathish S, Stewart WB. Centurion syndrome and its surgical management. *Ophthal Plast Reconstr Surg* 1999; 15:243-4
7. Maluf RN, Bashshur ZF, Novredden BN. Anterior canthal tendon release for correction of the centurion syndrome. *Ophthal Plast Reconstr. Surg.* 2003; 19:446-8
8. Chang JH, O'Donnell BA. Medial canthal tendon release and lower eyelid retractor placement for Centurion syndrome. *Clin Experiment Ophthal* 2006; 34:2844-287.