



METAPLASTIC CARCINOMA BREAST - A CASE REPORT

Dr Goutam Koushal Assistant Professor Surgical Oncology

Dr Ahmed Shakil Department Of Oncosurgery, Srg Hospital And Medical Collage Jhalawar .

ABSTRACT

Metaplastic carcinomas of the breast are rare and interesting, yet confusing neoplasm, representing less than 1% of all breast cancers. It has been reported that these tumours are more likely to occur in women older than 50 years .Here we present a case report of metaplastic carcinoma breast in a young female.

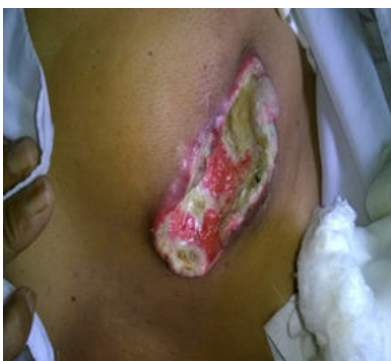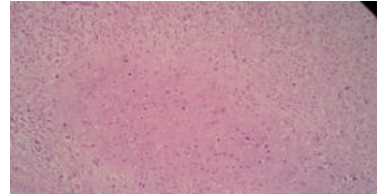
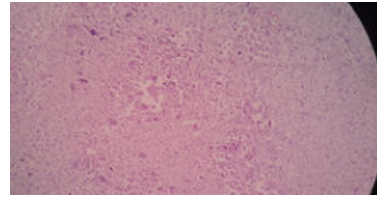
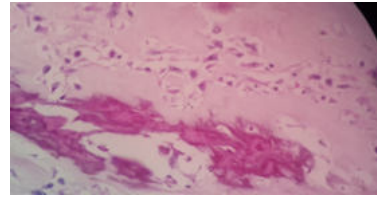
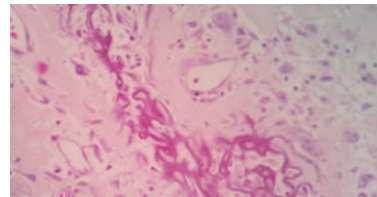
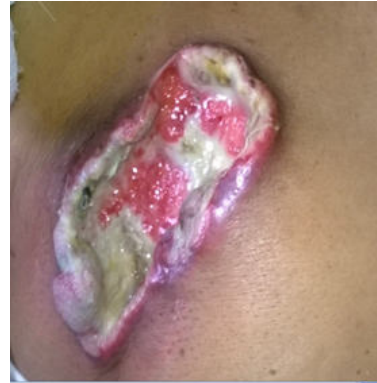KEYWORDS :

INTRODUCTION

Metaplastic breast cancer (MBC) is a malignancy characterized by the histologic presence of two or more cellular types, commonly a mixture of epithelial and mesenchymal components. The major criterion for a diagnosis of metaplastic carcinomas of the breast is the presence of overt carcinomas that are composed largely of squamous and spindle cells, and those with a sarcoma-like growth pattern including heterogeneous elements such as bone and cartilage^[1,2,5-9].

Case Report

A 35 years old female presented in surgical oncology department of srg hospital and medical collage jhalawar. with a fungating lump in left breast for last 6 months. Patient was married and have two live child both child had complete breast feeding ,menstrual cycle is regular ,On clinical examination there is 7 x 6 cms fungating mass in left breast. Patient was married and had two children. There was no family history of breast cancer .Her preoperative investigation was TLC :9500/cmm, HB:7.7gm/dl at admission and comes to 10.1gm/dl after 2 unit pcv transfusion ,other blood investigation was normal, MAMMOSONOGRAPHY of right breast not done due to fungating mass, while that of left breast is normal , on sonography of both axilla there is malignant nodes in right axilla with matted mass left breast shows few axillary nodes, USG abdomen was normal. Chest x ray was normal. Preoperative biopsy report shows epithelial cells with focal squamous differentiation and areas showing malignant spindle cells with chondromyxoid stroma and necrosis features suggestive metaplastic carcinoma breast / matrix producing carcinoma .After the diagnosis patient plan for palliative mastectomy. Intra and postoperative course of patient was uneventful .Postoperative histopathology report shows metaplastic carcinoma right breast, tumour involve all quadrant of right breast 8.5 x 8 x 4.5 cm in diameter ,two distinct areas are identified one is apocrine carcinoma and other is high grade sarcoma with osteoid cartilage and osteoclast type giant cells abudent lymphovascular and perineural invasion was seen. Matted mass in right axillary region and five out of eight lymph nodes show metastasis with perinodal extension.IHC shows triple negative status.



DISCUSSION;

Metaplastic carcinoma of the breast is a rare type of breast cancer accounting for 0.2 to 1% of breast malignancy^{1,4,6}. The term metaplastic carcinoma first introduced by Huvos et al^{7,8}. In this carcinomatous epithelium is transformed to nonglandular growth pattern by a process referred to as metaplasia. There are four variants of metaplastic carcinoma:(1) matrix producing carcinoma, (2) carcinosarcoma, (3) squamous cell carcinoma and (4) spindle cell carcinoma. Metaplastic carcinoma with

chondroid differentiation (MCCD), a matrix producing carcinoma is distinctive form of metaplastic carcinoma consisting of overt carcinoma with transition to an abundant cartilaginous, osseous or both cartilaginous or osseous stromal matrix in the absence of intervening spindle cell component³.

CONCLUSION

Metaplastic carcinomas of the breast are rare but aggressive tumors. Early diagnosis is essential because they are triple negative .Current evidence-based medicine indicates that these patients should be treated the same as patients with the more common forms of breast cancer and followed up routinely.

REFERENCES

1. Rosen PP. Carcinoma with metaplasia. In :Rosen PP,editor.Rosens Breast Pathology. 2nd edition. Philadelphia: Lippincott Williams and Wilkins. 2001. pp 425-452
2. Tavassoli FA. Papillary lesions. In :Tavassoli FA,editor.Pathology of Breast. 2nd edition. Stanford (CT): Appleton and Lange. 1999. 481-504
3. Dunne B, Lee AH, Pinder SE et al. An immunohistochemical study of metaplastic spindle cell carcinoma, phyllodes tumour and fibromatosis of breast. *Hum Pathology*2003;34:1009-1015
4. Pollock JM, Green A, Donnell C, Dyess DL, Tucker JA. Metaplastic Breast Carcinoma with Osseous 2 Differentiation: A Case Report *Southern Medical Journal*February2006;99(2):168-170.
5. Ellios ID, Corneli ssc CJ, Schnitt SJ et al. Tumour of breast. Invasive Breast Carcinoma. In: Tavassoli FA, Devileep, editors. Pathology and Genetics of tumours of breast and female genital organs. Lyon; IARC Press. 2003. pp 37-41
6. Tavassoli FA. Classification of Metaplastic Carcinoma of breast. *Pathol Annu*1992;27:89-119.
7. Havos AG, Lucas JC, Forte FW. Metaplastic breast carcinoma: Rare form of mammary cancer. *NY State J Med*1973;73:1078-1082.
8. Al Sayed AD, Elweshi AM, Tulba AM et al. Metaplastic carcinoma of the breast clinical presentation treatment result and prognostic factors. *Acta Onchologica*.2006;45:188-195
9. Wargotz ES, Norris HJ. Metaplastic carcinoma of the breast. I. Matrix producing carcinoma. *Hum Pathol*1989;20:628-635