



## A HOSPITAL BASED STUDY OF DEMOGRAPHY AND RISK OF AGE RELATED MACULAR DEGENERATION

**Dr Bhup Singh\***

Ophthalmologist ZH MANDI Himachal Pradesh \*Corresponding Author

**Dr Umang Thakur**

Ophthalmologist ZH MANDI Himachal Pradesh

### ABSTRACT

The present study was aimed to study the demography and risk of age related macular degeneration. Age-related macular degeneration (AMD) is one of the main socioeconomic health issues worldwide. This is prospective study include all patients of age related macular degeneration above 50 years of age presenting in the Department of Ophthalmology at Dr.RPGMC Tanda. Total 86 patients were examined. There were 79(91.86%) who were from rural area while 7(8.14%) patients were from urban area. Finding showed that prevalence of ARMD was higher in rural patients when compared to urban patients.

**KEYWORDS :** Demography, Age-related Macular Degeneration.

### INTRODUCTION

Age related macular degeneration (ARMD) represents a spectrum of gradual ageing resulting in degenerative changes in the human macula. It is a major cause of blindness and severe visual loss in older people in developed countries<sup>1</sup>.

It is the third leading cause of blindness worldwide and accounts for 8.7% of blind persons globally. It is estimated that by the year 2020, at least 80 million will be affected by ARMD globally. In India, the prevalence of ARMD ranges between 1.4% to 1.8% in different epidemiological studies. It results in progressive and irreversible loss of central vision affecting the macula of the eye and involve the retinal pigment epithelium (RPE), Bruch's membrane (BM) and choriocapillaries<sup>2</sup>.

Macular degenerative changes have typically been classified into two clinical forms, dry or wet, both of which can lead to visual loss. In the dry form visual loss is usually gradual. Ophthalmoscopy reveals yellow subretinal deposits called drusen, or retinal pigment epithelial irregularities, including hyperpigmentation or hypopigmentary changes. Larger drusen may become confluent and evolve into drusenoid retinal pigment epithelial detachments (PEDs). These drusenoid RPE detachments often progress to geographic atrophy and less frequently to neovascular ARMD. Geographic atrophy involving the centre of the macula leads to visual loss. Each of these signs can be further subdivided according to the number and size of the lesions.<sup>3</sup>

In the wet (exudative) form, vision loss can occur suddenly, when a choroidal neovascular membrane leaks fluid or blood into the sub pigment epithelial or sub retinal space. Serous RPE detachments with or without coexisting choroidal neovascularization (CNV) are also classified as the wet form. According to international classification and grading system<sup>4</sup>, early age related maculopathy (ARM) is defined as the presence of drusen and RPE irregularities, and the terms late ARM and AMD are limited to the occurrence of geographic atrophy and neovascular disease.<sup>3</sup>

Prevalence, incidence, and progression of all forms of ARMD rise steeply with increasing age. There was a 17-fold increased risk of ARMD comparing the oldest to the youngest.<sup>5</sup>

ARMD is associated with elevated level of white blood cells, fibrinogen, low-density lipoproteins, cholesterol, homocystein and C-reactive protein<sup>6,7,8</sup>.

Pathogenesis of the ARMD is that lipids are deposited in Bruch's membrane possibly from failure of the retinal pigment epithelium to process cellular debris. These deposits are known as basal linear and basal laminar deposits. Only later in the disease process are drusen visible. Drusen that elevate

the RPE reveal that they contain lipid, amyloid, complement factors and additional cellular components. The appearance of drusen is preceded by thickening of Bruch's membrane, degeneration of elastin and collagen with in Bruch's membrane with calcification of Bruch's membrane with increased level of advanced glycation end products and accumulation of lipids and exogenous proteins. These changes lead to hydrophobic barrier to impede the passage of fluid and nutrients between the choroid and outer retina resulting in relative ischemia.<sup>9</sup>

Treatment strategies for ARMD includes various modalities like dietary supplementation of anti-oxidants, laser therapy (thermal photocoagulation, photodynamic therapy and surgery), anti-vascular endothelial growth factor (VEGF) and combination therapy (laser along with anti-VEGF treatment) are the current treatment modalities available in ARMD. These treatments are offered depending on the clinical phenotype to retard progression of the disease, as complete reversal is not possible. Majority of the treatment strategies are available for wet ARMD. Dry ARMD is currently managed with dietary supplementation of anti-oxidants that are primarily given to reduce the risk of ARMD development and progression.

### METHODS

#### Place of Study

Department of Ophthalmology, Dr.RPGMC, Tanda.

#### Study Population

All patients of age related macular degeneration above 50 years of age presenting in the Department of Ophthalmology at Dr.RPGMC Tanda.

#### Study Design

Prospective study.

#### Study Period

One year.

#### Inclusion Criteria

- All the patients of age related macular degeneration of age above 50 years presenting in Department of Ophthalmology, Dr.RPGMC Tanda.

#### Exclusion Criteria

- Patients with predominantly other types of retinopathies.
- Patients who refuse to give consent.
- Patients with dense corneal and lenticular opacities.

#### Study Procedure

All the patients of age-related degeneration attending the Out Patient Department of Ophthalmology at Dr. RPGMC Kangra

at Tanda whether symptomatic (i.e. complaining of diminished vision, scotoma, micropsia or macropsia) or asymptomatic (i.e. with ophthalmoscopic features suggestive of ARMD) were included in the study. Patients particulars like name, age, sex and address was recorded. A detailed ocular history from all the patients was recorded.

Family history along with personal history of smoking was taken. They were enquired about the number of packs/years he/she had been smoking.

Packs/years were calculated by multiplying the number of packs with years of smoking. The number of bidis taken by the patient per day were converted to cigarettes as four bidis are equal to one cigarette. One pack of cigarette is equal to twenty cigarettes. In India a packet has 10 cigarettes rather than 20 so the number of packs were divided by two.<sup>10</sup>

Social history, in which the occupation of the patient and educational status was noted. Serum CRP level of all patients was recorded. Any medical history, diabetes and hypertension was also recorded.

Complete systemic examination of the patients was done i.e. pulse rate, blood pressure, respiratory rate and cardiovascular system examination.

**Detailed Local Examination Of Both The Eyes Was Done, Which Included The Following:-**

- Visual acuity using Snellen's chart.
- Retinoscopy using Self-illuminated retinoscope was done after full dilatation of pupil using Tropicamide 1% eye drops.
- Detailed examination of anterior segment with slit lamp was performed.
- Amsler grid chart was used to detect micropsia, macropsia and metamorphosia. Type-1 Amsler grid chart was used to evaluate 10° of visual field surrounding fixation. Type-1 chart comprised of 10 cm square containing 400 small squares each of size 5 mm which when viewed at one-third of meter subtends an angle of 1°.
- Direct ophthalmoscopy with 90D and Indirect ophthalmoscopy was done after full dilatation of pupil with Tropicamide 1% eye drops.
- Intraocular pressure was recorded.

**Following criteria were used to define ARMD and Drusen size:**

**Small Drusen:**

Drusen which were less than 63um.

**Medium:**

Drusen which were of the size of 63um to 125um.

**Large:**

Drusen which were 125um in size or more i.e. the width of a retinal vein as it crosses the optic nerve head.<sup>11</sup>

**RESULTS:**

The present study was aimed to study risk factors for age related macular degeneration. All patients of age related macular degeneration above 50 years of age presenting in the Department of Ophthalmology Dr. RPGMC Tanda during the period of one year were included in the study. Total 86 patients were examined.

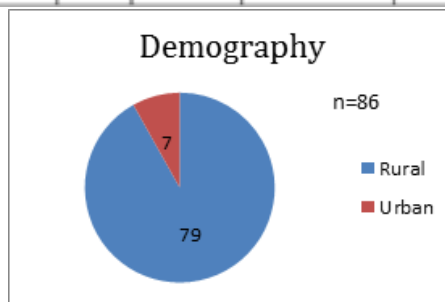
**Demography**

Our study showed that most of the 91.86% patients belonged to rural area (n=79) while only 7 (8.14%) patients belonged to urban area. Distribution of demography with early, intermediate and exudative ARMD is shown in table and fig. It

was found statistically insignificant (P=0.117).

**Table. Distribution of demography with Early, Intermediate and Exudative ARMD**

Diagnosis		Exudative	Total	P Value
Early	Intermediate			
51 (59.3%)	12 (13.95%)	16 (18.6%)	79 (91.86%)	0.117
4 (4.65%)	3 (3.49%)	0	7 (8.14%)	



**Fig . Distribution of demography with Early, Intermediate and Exudative ARMD**

There were 79(91.86%) patients who were from rural area, 51(59.3%) from them were in early ARMD followed by 16(18.6%) in exudative ARMD and 12(13.95%) in intermediate ARMD. Out of 7(8.14%) from urban area, 4(4.65%) patients were in early ARMD followed by 3(3.49%) patients in intermediate and there were no patient in exudative ARMD from urban area. Thus the study showed prevalence of ARMD was higher in rural area when compared to urban area.

**DISCUSSION:**

Our study showed prevalence of ARMD was higher in rural patients when compared to urban patients. Of the total 86 patients, 91.86% were from rural area. Among them 59.30% were in the early stage and 32.5% were in the intermediate/exudative stage of ARMD. 8% were from urban area. 4.65% of them were in the early stage of ARMD while 3.49% were in the intermediate stage of ARMD.

Xu et al<sup>12</sup> in a population-based prevalence study 'The Beijing Eye Study', studied 4439 subjects from a rural and an urban area and found an evidence that early ARMD was statistically associated in subjects who resided in rural region. So our study correlates with this study. This can be explained by the fact that in rural areas people are less aware and there are less medical facilities and they are more exposed to sun-light as compared to urban areas people.

**CONCLUSIONS:**

Conclusions This study further confirms the prevalence of ARMD higher in rural area when compared to urban area.

**REFERENCES**

1. Qureshi T, Nazir M, Abdullah N, Fazili A, Maqbool R, Ramazan R. Profile of age related macular degeneration in a Kashmiri population-a hospital based study in tertiary care hospital in Kashmir, India. Global J Med Public Health. 2013;2:1-7.
2. Katta S, Kaur I, Chakrabati S. The molecular genetic basis of age-related

- macular degeneration: an overview. *J Genetics*. 2009;88:425-6.
3. Seddon JM, Chen CA. Epidemiology of age-related macular degeneration. In: Ryan JS, editor. *Retina*. 4<sup>th</sup> ed. China: Elsevier Mosby; 2006. p.1018-24.
  4. Bird AC, Bressler NM, Bressler SB, Chisholm IH, Coscas G, Davis MD, et al. An international classification and grading system for age-related maculopathy and age-related macular degeneration. *Surv Ophthalmol*. 1995;39:367-74.
  5. Lebowitz HM, Krueger DE, Maunder LR, Milton RC, Kini MM, Kahn HA, et al. The Framingham Eye Study monograph. *Surv Ophthalmol*. 1980;24:335-610.
  6. Shanker A, Wang JJ, Rochtchina E, Yu MC, Kefford R, Mitchell P. Association between circulating white blood cell count and cancer mortality: a population-based cohort study. *Arch Intern Med*. 2006;166:188-94.
  7. Smith W, Mitchell P, Stephen R, Wang J. Plasma Fibrinogen levels, other cardiovascular risk factors, and age related maculopathy. *Arch Ophthalmol*. 1998;116:183-7.
  8. Seddon JM, Gensler G, Milton ROC, Klein MI, Rifai N. Association between C-Reactive protein and age-related macular degeneration. *Jama*. 2004;291:704-10.
  9. Nunes RP, Rosenfeld PJ, Filho CAG, Yehoshua Z, Martidis A, Tennant MTS. Age-related macular degeneration. In: Yanoff M, Duker JOS, Editors. *Ophthalmology*. 4<sup>th</sup> ed. China: Elsevier.
  10. Sharma SK. Chronic Obstructive Pulmonary Disease. In: Munjal YP, Sharma SK, Agarwal AK, Gupta P, Kamath SA, Nadkar MY, Editors. *API Text Book of Medicine*. 10<sup>th</sup> ed India: Jaypee Publications; 2015. p.2328-9.
  11. Bressler SB, Bressler MN, Sarks SH, Sarks JP. Age-related macular degeneration: Non neovascular early AMD, Intermediate AMD, and geographic atrophy. In: Ryan SJ, Editor. *Retina*. 4<sup>th</sup> ed. China: Elsevier Mosby; 2006. p.1052-60.
  12. Xu L, Wang Y, Li Y, Cui T, Li J, Jonas JB. Causes of blindness and visual impairment in urban and rural areas in Beijing. *The Beijing Eye Study*. *Ophthalmology*. 2006;113:1134-e1.