



ACUTE ISCHEMIC CEREBRAL STROKE IN A GIANT CERVICAL INTERNAL CEREBRAL ARTERY ANEURYSMAL SURGERY - A CASE REPORT

Dr. Venkatesan
Sanjeevi

Dr. Chandan Y S

Dr. Ashwathaman A

Dr. Archana
Subbaraj

ABSTRACT

Aneurysms of the cervical ICA are relatively rare. Giant aneurysms of this region present as parapharyngeal masses, and there are several etiologies. Management of cervical aneurysms either by the surgery or endovascular treatment depending upon the size, location and symptoms. Complications may occur either due to rupture or mass effect of the aneurysms. we report a case diagnosed with giant cervical aneurysm who developed acute cerebral infarct during parent vessel occlusion and managed effectively.

KEYWORDS : Giant cervical ICA aneurysm, STA-MCA bypass surgery, Ischemic stroke

INTRODUCTION

Aneurysms of the cervical portion of the internal carotid artery (ICA) are uncommon. They are considered to be of five distinct clinical types: pseudoaneurysm, fusiform, saccular, spontaneous dissecting, and mycotic.(1)The causes of these aneurysms include atherosclerosis, dysplasia, trauma, and infection.(2) They usually present either as a bulge in the lateral pharyngeal wall or a neck mass with or without pulsation. Treatments include surgical reconstruction, ligation or endovascular occlusion of the parent artery, and stenting to preserve the parent artery(3)(4).

CASE REPORT

A 83 years old female presented with neck pain and difficulty in swallowing, gradually progressing in nature. Patient underwent MRI neck and brain with MRA & MRV, which showed common carotid artery appears normal in calibre on both sides.

The internal carotid artery is tortuous on right side. Large fusiform aneurysm of the internal carotid artery is observed at the level of the skull base (C1 level). Aneurysm measures 2.5 x 2.5 cms, artifactual signal loss is observed in the aneurysm on MRA images, secondary to slow flow. The ICA distal to the aneurysm is visualised and is normal in calibre.

Left internal and external carotid arteries appear normal. Right vertebral artery is hypoplastic. Left vertebral artery appears normal suggestive of Large fusiform aneurysm in the right internal carotid artery at the level of the skull base (C1 level) with Internal carotid artery appears tortuous. CT brain and neck angiography was done which showed Right carotid saccular aneurysm seen in the right cervical ICA, measuring ~31x22mm. Retropharyngeal course of bilateral cervical ICA seen. Right cervical ICA appears tortuous and prominent. Variable mass effect is seen in the retropharyngeal soft tissue causing narrowing of the pharyngeal canal. DSA was done showed good cross flow across ACom after occluding ipsilateral CCA, hence planned for Right proximal ICA ligation with flow augmentation right STA-MCA bypass surgery under intra operative neuro monitoring (IONM). During surgery after ligation of right proximal ICA, there was a significant drop in SSEP and MEP on right side. Right STA-MCA bypass surgery was done along with clipping of right supraclinoid ICA. CT brain was done in POD 1 showed right MCA territory infarct and patient had dense weakness on left side. On POD 3 patient had drop in GCS and CT brain showed increase in infarct size with mass effect and midline shift.

patient underwent right FTP decompressive craniectomy. Patient's GCS improved gradually and after 3 weeks patient underwent autologous cranioplasty. patient was discharged in a stable condition and advised to continue physiotherapy.

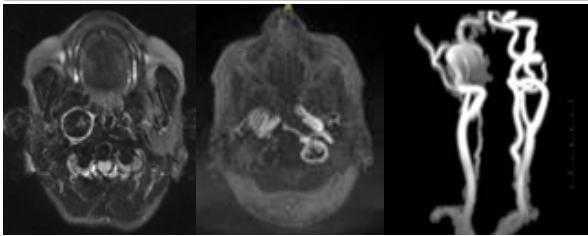
DISCUSSION

Aneurysms of the cervical ICA are relatively rare. Giant aneurysms of this region present as parapharyngeal masses (5), and there are several etiologies.(6) We could not rule out the possibility of it being a dissecting aneurysm, however, because cervical ICA dissections frequently occur without precipitating factors.(7) Unlike distal extracranial ICA aneurysms, cervical ICA aneurysms are resectable. The surgical complication rate may be high in reconstruction of giant cervical ICA aneurysms. Surgery is invasive, however, and there is also a cosmetic problem, especially for female patients. Endovascular stent placement also preserves parent vessel flow.

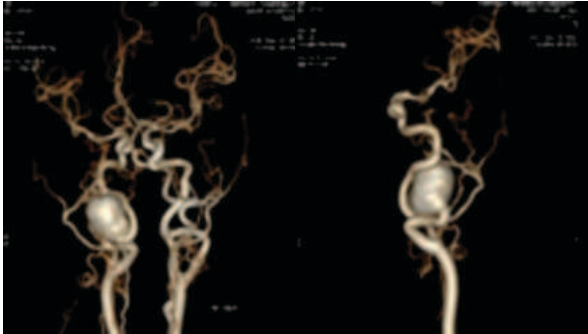
Traditionally, carotid ligations have been performed for the treatment of extra- and intracranial giant ICA aneurysms that are not treatable by direct surgery. Endovascular proximal occlusion methods are considered less invasive than carotid ligation, and the two methods are regarded as equally useful. Endovascular proximal occlusions were formerly performed with detachable balloons(8), but because of problems such as premature detachment, balloon rupture, early deflation, and distal migration, indications for the use of balloons are now limited. Singer et al reported the use of a covered stent in proximal occlusion.

Spaziante et Al reported an intracavernous giant fusiform aneurysm treated successfully by closing the ICA in the neck with Gianturco coils. During parent artery coil occlusion, both distal thromboembolic complications and distal migration of the coils can occur. In a case of unilateral ICA occlusion, hemodynamic stress to the circle of Willis is regarded to be high. This is a factor predisposing growth of aneurysms at the anterior communicating artery and the ipsilateral posterior communicating artery.

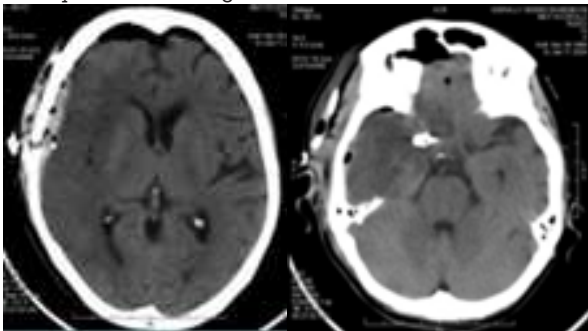
Therefore, periodic MR angiographic examination is indicated. In conclusion, if hemodynamically tolerable, giant aneurysms of the cervical ICA can be treated easily and without complication by proximal coil occlusion under proximal temporary balloon occlusion. MR imaging with post-contrast MR angiography is useful for follow-up evaluation of the treated aneurysm.



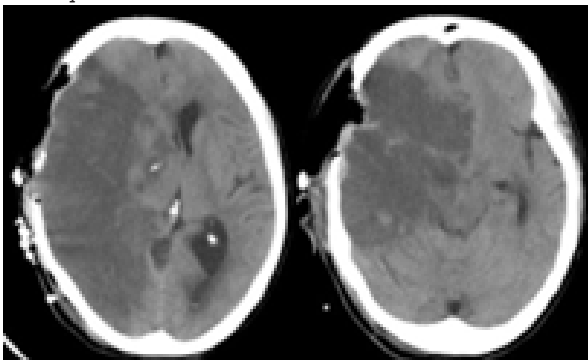
Pre op MRI Brain and neck with MRA & MRV (a)(b)(c) showing large fusiform aneurysm of the internal carotid artery is observed at the level of the skull base (C1 level). Aneurysm measures 2.5 x 2.5 cm. artifactual signal loss is observed in the aneurysm on MRA images, secondary to slow flow.



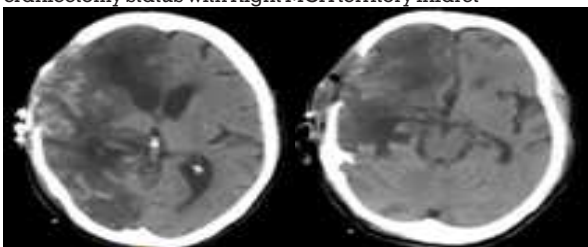
CT Angiogram of brain and neck (a)(b) showing saccular aneurysm seen in the right cervical ICA



POD- 1 CT brain showing Pterional craniotomy, clipping of supraclinoid ICA and STA - MCA anastomosis with acute infarct in right cerebral hemisphere involving the MCA territory.



POD- 3 CT brain showing post right FTP decompressive craniectomy status with Right MCA territory infarct



POD - 25 CT brain showing post right FTP autologous

cranioplasty status with resolving infarct mass effect

REFERENCES

1. Welling RE, Taha A, et al. Extracranial internal carotid artery. *Surgery.* 1983;93:319-323.
2. Rosset E, Albertini J-N, et al. Surgical treatment of extracranial internal carotid artery aneurysms. *J Vase Surg.* 2000;31:713-723. doi: 10.1067/mva.2000.104102.
3. Mase M, Banno T, et al. Endovascular stent placement for multiple aneurysms of the extracranial internal carotid artery: technical case report. *Neurosurgery.* 1995;37:832-835. doi: 10.1227/00006123-199510000-00032.
4. Hurst RW, Haskal ZJ, et al. Endovascular stent treatment of cervical internal carotid artery aneurysms with parent vessel preservation. *Surg Neurol.* 1998;50:313-317. doi: 10.1016/s0090-3019(97)00461-8.
5. Haynes DS, Schwaber MK, et al. Internal carotid artery aneurysms presenting as neck masses. *Otolaryngol Head Neck Surg.* 1992;107:787-791. doi: 10.1177/019459988910700614.1.
6. Munoz A, Campollo J, et al. Bilateral internal carotid aneurysms presenting as a nonpulsatile parapharyngeal mass: complementary diagnosis by CT, MR imaging, and digital subtraction angiography. *Am J Neuroradiol.* 2001;22:864-866.
7. Guillon B, Brunereau L, et al. Long-term follow-up of aneurysms developed during extracranial internal carotid artery dissection. *Neurology.* 1999;53:117-122. doi: 10.1212/wnl.53.1.117.
8. Serbinenko FA, Filatov JM, et al. Management of giant intracranial ICA aneurysms with combined extracranial-intracranial anastomosis and endovascular occlusion. *JNeurosurg.* 1990;73:57-63. doi: 10.3171/jns.1990.73.1.0057.