Original Research Paper

Volume-9 | Issue-7 | July - 2019 | PRINT ISSN No. 2249 - 555X

Gastroenterology

ACUTE ABDOMEN REVEALING PANCREATIC INVOLVEMENT IN GRANULOMATOSIS WITH POLYANGIITIS(GPA): A CASE REPORT

Naoual Oubelkacem*	Service de médecine interne, CHU hassan II Fès *Corresponding Author
Maha Ouazzani	Service de médecine interne, CHU hassan II Fès
Zineb Khammar	Service de médecine interne, CHU hassan II Fès
Rhizlane Berrady	Service de médecine interne, CHU hassan II Fès

ABSTRACT **Background:** Granulomatosis with polyangiitis (Wegener) is a necrotizing vasculitis. He is more often characterized by ear, nose and throat symtomes, lung and kidney damages. However, pancreatic involment in GPA remains very rare.

Case presentation: male aged 33 years old, was hospitalized for nephrotic syndrome. Lab results showed elevated inflammation markers, Anti-neutrophil cytoplasm antibodies (ANCA) tested negative. Sinus CT scan showed a diffuse thickening of the sinuses with an almost complete filled right maxillary sinus and ethmoid cells. Renal biopsy found an extra capillary glomerulonephritis with vasculitis and a focal segmental glomerulosclerosis. Our therapeutic approach consisted in a bolus administration of methyl prednisolone and cyclophosphamide. The patient was rehospitalized a week after the 5th cyclophosphamide bolus administration, for upper abdominal pain, Lab and Abdominal CT scan assessment a Balthazar B pancreatitis.

Conclusions: GPA with pancreatic involvement is rarely found in the literature.

KEYWORDS : Granulomatosis with polyangiitis, pancreatitis.

INTRODUCTION:

Granulomatosis with polyangiitis(GPA) is a form of vasculitis that often affects the ear, upper and lower respiratory tracts and the kidneys.Its typical histopathological feature includes a necrotizing granulomatous vasculitis. This vasculitis is biologically characterized by the presence of proteinase 3(PR3)-specific anti-neutrophil cytoplasmic antibody (ANCA) which significantly helps in its diagnosis,although its absence does not elimicate the possibility of GPA in any case. Pancreatic damage during the GPA is rare and probably unknown.Hence,it is interesting to characterize this disease better based on this case report and review the literature.

Case report:

Mr AM: 33 years old, ex-smoker , with a medical history of asthmatic bronchitis diagnosed in the year 2000 undergoing symptomatic medical treatment, was hospitalized for nephrotic syndrome revealed by edema of the eyelids, lower back and the lower limbs. The patient reported gross hematuria with no upper or lower respiratory tract symptoms.

Physical exams found a normotensive patient with a pitting edema on both lower limbs, and bilateral pulmonary crackles. Initial abdominal exams was unremarkable.

Lab results showed elevated inflammation markers: sedimentation rate (150 mm in the first hour), C-reactive protein (79 mg / l), serum protein electrophoresis (polyclonal profile), proteinuria (3.68g / 24h), leucocyturia (20800 / mm3), hematuria (11020 / mm3), and cylindruria (27260 / mm3). Anti-neutrophil cytoplasm antibodies (ANCA) tested negative.

Radiological assessment performed included a chest X-ray which was complemented with a CT scan that objectified no parenchymal abnormalities. Sinus CT scan showed a diffuse thickening of the sinuses with an almost complete filled right maxillary sinus and ethmoid cells associated with a deviated septum to the right. Renal biopsy found an extra capillary glomerulonephritis with vasculitis and a focal segmental glomerulosclerosis suggestive of GPA.

Once this diagnosis was retained, our therapeutic approach consisted in a bolus administration of methyl prednisolone at 15mg / kg / day for 3 days followed by a bolus administration of cyclophosphamide at 375 mg / m2 according to the french vasculitis study group (FVSG) recommendations associated with gradual degression of oral corticosteroids .

An improved clinical status of the patient was observed around the 4th bolus administration which constituted total disappearance of edema, negativie proteinuria with decreased leukocyturia (3300 / mm3), cylindruria (550 / mm3) and hematuria (4620 / mm3). Therapeutic relay was done by using azathioprine at a dose of 2 mg / kg / day. The patient was rehospitalized a week after the 5th cyclophosphamide bolus administration, for upper abdominal pain irradiating to his back , aggravated by eating and relieved after trunk anteflexion . Physical examinination found a generalised jaundice, edema of both lower limbs, an epigastric pain with no palpable mass nor organomegaly.Chest examination revealed bilateral pulmonary crackles.

We looked for an infection that could be responsible for these symptoms: no bacteriological findings was made. Lab assessment found the following results: AST :181 IU / L (10-40), ALT :379 IU / l (10-50), GGT : 1819 IU / l (10-50), alkaline phosphatase: 268 IU / l (30- 120), conjugated bilirubin : 135 mg / dL (0-5), normal blood glucose, C-reactive protein : 16 mg / l (<8), lipase: 160 IU / l (0- 60) and amylase : 139 U / l (0-125). Abdominal CT scan objectified a Balthazar B pancreatitis (Figures 1 and 2) which could be related to a relapse of his disease.

The immediate action taken involved oral food restriction,parenteral nutrition and administration of antispasmodics and proton pump inhibitors for gastric protection.

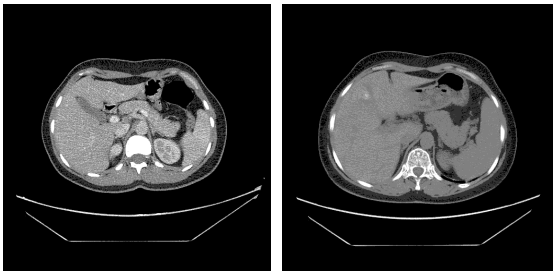

Figures 1 et 2 : enlarged pancreas compatible with Balthazar B pancreatitis.

DISCUSSION:

Digestive tract involvement during GPA is rarely found, it may be essentially an esophageal, gastric or colonic [1]. The frequency of pancreatic damage during GPA is difficult to determine. This is a rare location, and sporadic cases are reported in the literature.

Walton et al : in his Autopsy series in which 54 patients were followed for GPA and who never showed clinical signs of pancreatic involvement concluded that 9.3% of cases had necrosis with no granuloma was found in the pancreatic parenchyma in a CT scan study [2].

Our review of the literature found 7 reported cases of pancreatic damage ,3 of which were described as pseudotumors, 3 cases of acute pancreatitis as in the case of our patient, and only one case in the form of pancreatic insufficiency [3].

The different forms of acute pancreatitis typically manifests as abdominal pain localised in the epigastric region, relieved after trunk anteflexion and are often associated with elevated pancreatic enzymes. Iatrogenic causes such as corticosteroids, azathioprine or cyclophosphamide should be considered in cases where no histopathological findings are made[4] as it could be in our case , given the improvement of symptoms after administering steroids.

The pseudotumor form is very rare, three cases are described in the literature, the most classic locations during a GPA are the kidneys, lungs, or retro-orbital. [5]

It is a differential diagnosis with other inflammatory diseases responsible for pancreatic masses, as in the case of sarcoidosis, nodosa or Crohn's disease. In such situations, the clinical context and the patient's medical history are essential elements for a positive diagnosis.

In our patient, typical symptoms of pancreatitis prompted us to explore this region, while taking into consideration his history of the GPA. Upper gastrointestinal endoscopie has a sensitivity between 91 and 98% for the diagnosis of pancreatic mass. It is significantly higher than that of the CT scan and the standard ultrasound (between 64 and 88% for each technique) [6].

The treatment of pancreatic affections in a patient with GPA is not codified. it seems to favorably evolve with immunosuppressive therapy when the latter is given quickly. It includes corticosteroids and cyclophosphamide, an association which remains the reference treatment for severe forms. Our patient had pancreatic disease while being treated with cyclophosphamide.His treatment at home consisted of a 3 day methylprednisolone bolus administration followed by oral corticosteroids. This treatment is not usually used as first line therapy but it is a therapeutic option in mild forms or used to replace immunosuppressants during pregnancy. [7]

CONCLUSION:

GPA with pancreatic involvement is rarely found in the literature.This can be a severe gastrointestinal involvement in patients with GPA that requires immediate immunosuppressive drugs.Thus,the need to systematically search for any pancreatic involvement even in cases with no clinical signs .

REFERENCES:

[1] Pagnoux C, Mahr A, Cohen P, Guillevin L. Presentation and outcome of gastrointestinal involvement in systemic necrotizing vasculitides: analysis of 62 patients with polyarteritis nodosa, microscopic polyangiitis, Wegener granulomatosis, Churg-Strauss syndrome, or rheumatoid arthritisassociated vasculitis. Medicine (Baltimore) 2005; 84:115–128.

[2] Walton EW. Giant-cell granuloma of the respiratory tract (Wegener's granulomatosis). BMJ 1958;34:265–70.

[3] I. Marroun, I. Delèvaux, M. André, F. Gavet, A.M. Beaufrere, K. Slim, O. Aumaître, Les atteintes pancréatiques au cours de la granulomatose de Wegener : une localisation rare et un diagnostic difficile, La Revue de médecine interne 27 (2006) 144–147.

[4] Biour M, Daoud H, Ben Salem C. Drug-induced pancreatitis. Second of the bibliographic database of pancreatitis related to drugs. Gastroenterol Clin Biol 2005; 29:353–9.

[5] Kariv R, Sidi Y, Gur H. Systemic vasculitis presenting as a tumorlike lesion. Four case reports and an analysis of 79 reported cases. Medicine (Baltimore) 2000;79:349–59.

[6] Brugge WR. Endoscopic ultrasonography: the current status. Gastroenterology 1998; 115:1577–83.

[7] Bellisai F, Morozzi G, Marcolongo R, Galeazzi M. Pregnancy in Wegener's granulomatosis: successful treatment with intravenous immunoglobulin. Clin Rheumatol 2004; 23:533–5.