RESEARCH PAPER | Medical Science | Volume : 5 | Issue : 6 | June 2015 | ISSN - 2249-555X



Analysis of Hard Palate in South Indian Skulls

KEYWORDS: Hard palate, Greater Palatine formamen, Incisive foramen, lesser palatine foramen, middle maxillary suture

Ashwini Shenai

saveetha Dental College

ABSTRACT *AIM: To analyse morphometry of hard palate in South Indian skulls*

OBJECTIVE: To determine (i) Palatine Index; (ii) position of Greater Palatine Foramen with respect to Maxillary Molars, Incisive Focca, and Middle Maxillary Suture ; (iii) number of Lesser Palatine Foramen on the hard palate.

BACKGROUND : Palate forms roof of mouth and floor of nasal cavity. Hard palate contains bony palate, formed by palatine processes of Maxillae and horizontal plates of palatine bones. Skeletal deformities on this region can affect articulation of speech, variations on articulation of speech, variations in upper respiratory system, and cause conditions like cleft palate and sleep apnea syndrome. the Greater Palatine Foramen(GPF) contains Greater palatine nerve innervating Hard Palate. Anatomical knowledge is required to locate the foramen to inject local anaesthesia in surgical procedures.

MATERIALS AND METHODS: 30 dried human skulls will be observed from Department of Anatomy, Saveetha Dental College, and analysed morphometrically with Vernier Calliper.

Palatine index is determined by the formula: Breadth/ length X 100

REASON FOR THIS STUDY : The various anatomical parameters used in the study will be a useful reference clinically in speech therapy, and help in increasing accuracy of location of GPF for anaesthesia in different maxillo facial surgical procedures.

INTRODUCTION:

The palate seperates the oral cavity and nasal cavity. The hard palate contains bony palate which are formed by palatine process of maxillae and horizontal plates of palatine process. The bones are linked by a cruciform suture at their junction. [1] Morphometric and anatomical knowledge of the hard palate is required as guidelines for medical practitioners. Hard palate contains the Greater Palatine formina, Lesser palatine foramena and Incisive foramen. Greater and lesser palatine foramen transmit the greater and lesser palatine nerves and vessels respectively. Nasopalatine nerves and vessels exit through the incisive foramen. The three nerves are branches of Maxillary nerve and the vessels are branches of maxillary artery(Moore et al, 2013). Dentists, anaesthatists and Maxillofacial surgeons need to know the location of the foramina inorder to carry out accurate nerve block of the Maxillary nerve during procedures such as upper tooth extraction, maxillary dental implants, orthognathic surgery and cleft palate surgery(Das et al, 2006). The middle maxillary suture divides the hard palate into left and right regions. The incisive fossa represents the junction between primitive and permanent palate[1]. Skeletal deformities of the hardpalate can affect speech articulation or cause variations of upper respiratory syndrome resulting in conditions such as sleep apnea syndrome[2].

The aim of this study is to morphometrically analyse the hard palate and come to a conclusion on statistical analysis with regards to location of Greater Palatine Foramen(GPF) and number of lesser palatine foramina(LPF).

MATERIALS AND METHODS:

30 dried unsexed human skulls, with fully intact maxillary first molar, were observed from department of anatomy, Saveetha Dental college. The following measurements were made using digital vernier calliper

i) Palatal length , breadth
ii) Distance from middle maxillary suture to GPF
iii) Distance from incisive fossa to GPF
iv) Distance from 1st maxillary molar to GPF

The palatal lenghth is the maximum distance on hard palate from anterior margin of incisive focca to posterior nasal spine. The palatal breadth is the maximum distance between the two first maxillary molars.

The palatine index was measured by the formula breadth/ lenghth x 100.

The number of lesser palatine foramina on each side were also observed.



Volume : 5 | Issue : 6 | June 2015 | ISSN - 2249-555X

Measurment of palatal breadth



measurment of palatal lenghth

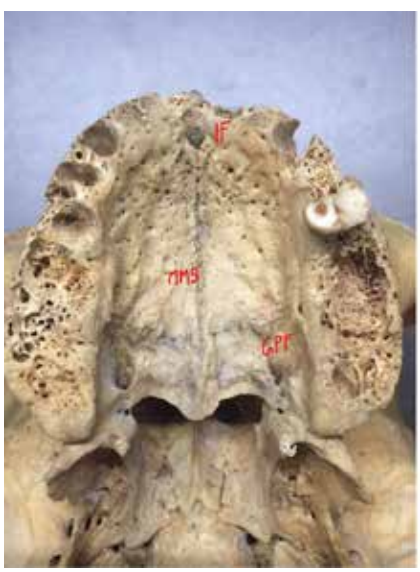

Hard palate showing the Incisive Foramen(IF), Middle maxillary suture(MMS) and the greater palatine foramen (GPF)

RESULTS:

Palatine index= breadth/length x100

Mean palatine index= 94.69

POSITION OF GREATER PALATINE FORAMEN WITH RESPECT TO-	LEFT GREATER PALATINE FORAMEN		RIGHT GREATER PALATNE FORMAMEN	
	MEAN	ST. DEVIATION	MEAN	ST. DEV
1ST MAXILLARY MOLAR	18.105	2.15	19.08	2.77
INCISIVE FOSSA	38.50	3.32	38.42	2.76
MIDDLE MAXILLARY SUTURE	14.586	1.69	14.44	1.36

NO. OF LESSER PALATINE FORAMINA(LPF)

NUMBER OF LPF	NUMBER OF SKULLS HAVING LPF	
	LEFT	RIGHT
0	1	2
1	15	14
2	12	11
3	2	3

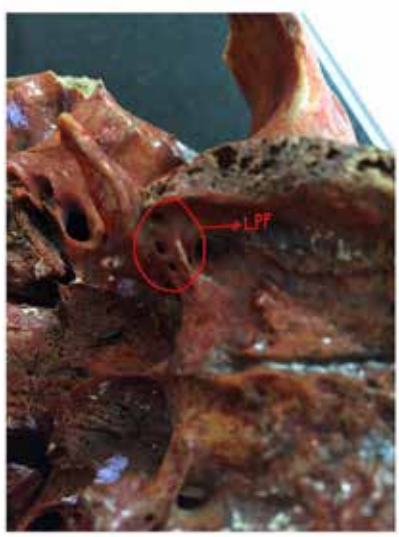

Hard palate showing 3 lesser palatine foramina on one side

The results of this study show that the greater palatine foramina on either side is located almost at the same distance from the middle maxillary suture, the distances being 14.58+_1.69 mm and 14.44+_1.36mm , from the left and right resepctively. The mean distances of the left and right GPF to incisive focca were 38.50+_3.32 mm and 38.42+_2.76 mm respectively. The right GPF was located a little further away from 1st maxillary molar at a distance of 19.08mm compared to the left GPF, 18.05mm away.

2 skulls out of 30 contained LPF on the left. 3 skulls out of 30 contained LPF on the right. This is of statistical significance.

DISCUSSION:

The hard palate has been of special interest in many disciplines of science, the primary reason being that it is an important cranio-facial structure necessary for feeding and speech articulation. Defect in formation is associated with a number of syndromes such as Apert Syndrome, Turner's syndrome, Franceschetti-treacher collin's syndrome, Marfan's syndrome, and Trisomy syndrome among others[3].

Volume : 5 | Issue : 6 | June 2015 | ISSN - 2249-555X

Ikuta et al, 2013 , states that distance between MMS and GPF can be used as a reference in maxillary tooth anaesthesia.Westmore and Blanton[4] have reported the distance from GPF to MMS to be a mean of 14.8mm on the right and 15mm on the left. Sarala and Nayak[5] have reported a distance of 14.77 mm on both sides. Bruno R Chrcanovic [6] reported 14.68mm on right side and 14.44mm on left side. Ajmani [7] has reported a mean distance of 14.7 mm on right and 14.6 mm on the left in Indian skulls. The results in the present study – 14.58 mm on the left and 14.44mm on the right, do not have significant variation from above reported values.

Saralaya et al(2007) has reported distance from GPF to IF to be 37.3mm on the left and 37.2 mm on the right. This present study has reported mean distance from GPF to IF to be 38.5mm on left and 38.4mm on the right. Hence the mean distance here is slightly more than that reported by Saralaya et al(2007)

The palatine index as reported in Gray's Anatomy(39th edition) is 74.2mm. in the present study, a much higher value of 94.69mm has been reported.

Saralaya and Nayak[5] have reported bilateral symmetry of LPF in 40% of skulls. Hassani[8] has reported multiple LPF to be the norm. This study agrees with Hasssan's findings and reports 3 foramina on the right in 10% of skulls which is a significant finding.

CONCLUSION:

The present study has evaluated the hard palate in skulls of Indian Origin.Knowledge on exact location of foramina on hard palate is crucial for correct administration of local aneasthesia for surgical procedures such as orthignathic surgery and cleft palate correction. This study can provide clarity on the same.

REFERENCE 1) Williams PL, warwick R, dayson M, Bannster H: Grey's Anatomy, 37th edition, London 1989:354 | 2)Adam Lammert, Michael proctor: Morphological variation in adult hard palate and posterior pharyngeal wall. Journal of speech, language and hearing research, apr 2013, vol 56:521-530 | 3) Dr. Manmohan patel: A study of hard palate in the skulls of cenral indian population. Int.Journal of pharma and biosciences, vol3, issue 2, apr-june 2012:B527-533 | 4)westmoreland EE, Blanton PL: An analysis of variation in position of greater palatine foramen in the adult human skull. Anat Rec, 1982; 204:383-388 | 5)Sarala V, Nayak SR: the relative position of the greater palatine foramenin dry indian skulls. Singapore Med J 2007;48:1143-1146 | 6)Bruno R Chrcanovic, Antonio LN: Anatomical variation in position of greater palatine foramen.Journal of oral science 2010; 52(1): 109-113 | 7) Ajmani ML: Anatomical variation in position of greater palatine foramen in adult human skulls. J anat 1994,184:635-637