Original Research Paper

Volume-9 | Issue-7 | July - 2019 | PRINT ISSN No. 2249 - 555X

Surgery

CURRENT SCENARIO OF MINIMAL ACCESS SURGERY IN PEDIATRIC SURGERY IN A TERTIARY CARE CENTRE

Jayaswal Shalika Aeron	MCh Paediatric Surgery Fellow in Minimal Access Surgery, Seth G. S. Medical College and K.E.M. Hospital Parel, Mumbai.
Parelkar Sandesh V*	Mch Paediatric surgery, Professor and Head, Department of Pediatric Surgery, Seth G. S. Medical College and K.E.M. Hospital,Parel, Mumbai - 400012, India. *Corresponding Author
Mudkhedkar Kedar P	Mch Paediatric surgery- co-author. Associate Prof. Pediatric surgery, KEM Hospital.
Shah Rujuta	Mch Paediatric Surgery- co-author, Assistant Prof. Pediatric Surgery, KEM Hospital.
Makhija Deepa	Mch Paediatic Surgery- co-author, Assistant Prof. Pediatric Surgery, KEM Hospital.

ABSTRACT **AIM** of this study is to evaluate the result of minimal access surgery in pediatric age group.
METHODS: It is a retrospective analysis of patients in the year 2017. Parameters of the patients studied were, age of presentation, male : female ratio, type of cases subjected to Minimal access Surgery, operative time, hospital stay and conversion to open were noted.
RESULTS: During the study total of 202 cases were subjected to minimal access surgery in the year 2017. The median age of presentation was 5.5 year. Male :Female ratio was 3.48:1. Total number of cases subjected to: Laparoscopic procedures 84.15% and Thoracoscopic procedures were 15.8% . Mean operative Time was 1.20 minutes. Mean post operative Hospital stay: 2.15 days. Conversion to open: 4.45 % .
CONCLUSION: Minimal Access Surgery is safe, in pediatric patients.

KEYWORDS : Current role, Minimal access, Children.

INTRODUCTION

Pediatric minimal Access surgery is all about operating with small holes, in small babies amounting to small space, with smaller instruments and no tactile perception, requiring a different skill set as opposed to conventional open surgery.[1]Worldwide numerous studies have been conducted to assess the safety of use of minimal access surgery in pediatric age group and Indian evidence of the same is also available.

The purpose of study is to determine the current role of pediatric minimal access surgery. We highlight the technical and other relevant aspects in various operative procedures, to reduce the postoperative complications and morbidity.

The study involves the kind of cases subjected to minimal access surgery, preoperative diagnosis, and relevant physiological changes involving flow rate and pressure variations, various procedures to treat them, to deal with intraoperative technical difficulties involved, conversion to open surgical procedure in case the need arises and the immediate postoperative outcome and follow up.

PATIENTS AND METHODS:

This study is a retrospective analysis of patients operated in the year 2017, from 1st January to 31st December as to determine the current role of pediatric minimal access surgery, in a tertiary care hospital in Western India.

Inclusion Criteria:

- All cases subjected to laparoscopic procedures
- All cases subjected to Thoracoscopic procedures

Exclusion Criteria:

- Cases subjected to open conventional surgical procedures.

PATIENTS AND METHODS

The commonest procedure was inguinal hernia repair which are 65 in number. A 30 degree 5 mm telescope was used with insufflating pressures varying between 4-8 mmHg in infantile age group, between 8-12 mm Hg in age group of 1 to 6 years of age and insufflating pressures between 10-12mm Hg in age group of 6 years to 12 year of age. Carbon Dioxide insufflating flow rate varied from of 1 lt/min, in infantile age group, 1-2 lt/min in age group between 1 to 6 years of age, 2 lt/min in age group 6 to 12 years of age. Our case series, in that particular year, we had zero recurrence.

Second most commonly performed procedure, was appendectomy which were 48 in number, of which 25 cases presented to us as acute appendicitis, rest all were cases of interval appendectomy. Classical 3 port appendectomy, with use of endoloops, was done in all cases. One case had pyoperitoneum and was converted to open laparotomy hence conversion rate in our case series came as 1/48. Two cases of ours had minor port site infection, which were treated by giving antibiotics and drainage procedure.

Fifteen cases of empyema were subjected to Video-assisted Thoracoscopic Surgery[VATS]. All cases subjected to VATS were within 14 days of onset of symptoms, in the fibrinopurulent stage. All cases were operated using two port technique. No insufflation was used, and zero degree scope was used in all cases. Pathological specimen collected were all sent for culture and sensitivity and for histopathological examination. Out of 13/15(86.66%) cases came out to be pyogenic with Staphlococcus, streptococcus, and E. coli as the organism grown. 2/15 (13.3%) cases were positive for tuberculosis, with raised ESR, MGIT and gene expert as positive and were given 4 drug AKT for a period of 9 months.

Total of 13 children under went Thoracoscopy for repair of Congenital Diaphragmatic Hernia. These were repaired using non absorbable, Polyester sutures extracorporeally, and on a mean follow up period of 3 months had zero recurrence rate. Four cases of neonatal congenital Diaphragmatic hernia expired after 4 days of postoperative period because of comorbid conditions like associated pulmonary hypertension and sepsis. Hence mortality was 30.76% (4/13).

In our series of 11 cases of undescended testes [UDT], we have used a relatively newer technique to deal with high abdominal testis known as Shehata's Traction Technique which was done in 5 cases. This is a two stage laparoscopic traction orchiopexy, in which the testis after mobilizing are anchored one inch above and medial to opposite side anterior superior iliac spine, for elongation of the testicular vessels without division (first stage) and subdartos orchiopexy is done in stage two. Three cases were subjected to Fowler Stephens stage 1 and 2. Two cases subjected to single stage orchiopexy and one turned out to be a case of atrophic/vanishing testis. All cases were followed up for 6

months.

In our case series, 8 cases of laparoscopic Cholecystectomy, were done for gall stones. In one of our cases we incidentally discovered Tubercular nodules present on the omentum, for which biopsy was taken which turned out to be tubercular, and was given anti tubercular treatment for 9 month.

Rest of the procedures are as shown in the Table 1.

Total of 6 cases of endoanal pull through for Hirschsprung's Disease was done, of which 2 were primary, needless to say we could avoid stoma related complications.

Total of 6 cases of Infantile Hypertrophic pyloric stenosis were dealt, without any complications as related to operative procedure.

Table 1: Different Operations performed by Minimal Access Surgery

Name of Surgery	No. of cases	Mean Age of Patient (range)	Male: female Ratio	Operative Technique used	Intraoperative findings Technical Issues	Mean Duration of Surgery ± SD	Conversion to Open	Post Operative Complication	Mean Hospital stay ± SD
Inguinal hernia	65	3 years (3m-12 yr)	52:13	Intra Corporeal Knot. (ethilon)	PPV + in 12 males/3females	45min.±20 min	Zero	Port site Inf. 3/65	12 hours +- 2hrs.
Appendicitis	48	5 years (3m - 12yr	41:7	Endoloop	-	1 hr.± 10 min	One	Port site Inf.2/48	2 days +-6 hrs
VATS	15	5 years (11m-10 yr)	8:7	No insufflation / two ports	Blood loss (100-250)mean 200 ml	1.30hr.±15 min.	Two	Air leak 2/15	3 days+- 1day
CDH	13	1 month (neon.to 8 month)	8:5	Extra corporeal knot (ethibond 2-0)	-	2 hr.±30 min.	Zero	On ventillatory support 9/13 Expired 4/13	5 days+- 1days
NP UDT	11	5 years (8months to 8 yrs)	All male	Stephen fowler/shehata	Traction orchiopexy done for taught testic.vessels	1hr±15min.	Zero	Inflammation at site of fixation1 Stich granuloma 2/11	2 days+-1day
Cholelithiasis	8	8.5 years (4 yr. to 10yr.)	All males	Three port with callots first	CBD perforation sutured/	1 hr.±15 min.	zero	-	2 days± 6hrs
Endo anal pull th. for H.D.	6	2.6 years (13 m to 7 yr).	All males	Endo anal with mark 4 sphicterotomy	Blood loss 250+-100 ml.	3hr. ± 30 min.	zero	Incontinence : 2 Constipation : 1	7 days +-1 day
IHPS	6	1 month	All males	3 port, use of endoknife	Shoeshine maneuver done to check completeness of myotomy	1hr. ± 15 min.	Zero		2 days±6hrs
Abdominal. Cysts	6	5 years (4 to 10)	4:2	St. 3 port	Enteric dupl. adh to illeum	2.20 hr. ±40 min.	One		2 days +_6hrs
Ovarian cyst	4	10 yr(9 to 11)	All female	Complete cystectomy	Oophoropexy	1.30 hr. ±30 min.	Zero	_	2 days+_6hrs
Nephroureterectomy	3	6.6 yr(3to 11yrs)	All males		Transperitoneal	2 hr. ± 20 min.	Zero		3 days+-1 day
DSD	2	2.2 yr(2- 2.4).	1m/1f	46 xy/ uterus + Streak gonads B/l	B/ lgonadectomy	1.30hr.	Zero		2 days
Hydatid cyst lung	2	7.5 (5-10)	2 male	capitonage and deroofing	Palaniveluhydatidsystem/Fibrillar used	2.30 hr.	Zero	Air leak +	6 days
Malrotation.	2	7.5(7-8)	2 male	Ladds pro.		2.30 hr.	One.		4 days
Diagnostic Laparoscopy	2	7.5 (5-10 year)	2 males	Meckles diverticulum excision	Excision of Meckels with resection anast.	1.30 hour	One	Nil	3 day
Ovarian mass	1	4 yr.	female	oophorectomy	torsion	1.30 hr	One		3 days
Bronchogenic cyst	1	2.5 yr	male	Excision of cyst	Ad. to arch of aorta Mucosectomy,	3 hrs	zero	Nil	12 days
Sacrococcygeal Teratoma	1	4 month	female	Lap.ass. Mobilization		3.30 hr.	One		4 days
Pyeloplasty	1	11 yrs	male	Lap.Pyeloplasty	Trans peritoneal	3.30 hr.	zero	Nil	5 days
Choledochal cyst	1	12 yr.	female	Lap hepaticodeudenostomy	Choledochal cyst excision	4 hr.	zero	Nil	6 days
Interstitial lung Disease	1	5 yr.	female	Lung Biopsy	Single port technique	1 hr.	zero		2 day
Splenomegaly with Thalesimia	1	4 yr	Female	Lap splenectomy	Too big spleen.	2.30 hr.	One	Nil	3 days
Ano Rectal malformatiom	1	6m	male	Lap. Pull through	High ARM	3 hr.	zero	Retension urine , on CIC and bethanecol	5 days
Hydatid Cyst left lobe liver	1	8y	female	Lap. Excision Hydatid	Omentoplasty done	2 hr.	Zero		5 days

* No.:Number,†SD: Standard Deviation, ǂ ppv: patent processes Vaginalis, § inf.: infection,¦:VATS: VideoAssisted Thoracoscopic Surgery, ** CDH: congenital diaphragmatic hernia, †† NP UDT: Non palpable Undescended Testis,ǂǂH.D.: Hirschsprungs Disease,§§ IHPS: Infantile Hypertrophic Pyloric Stenosis,¦¦ DSD: Disorderof sexual Development.

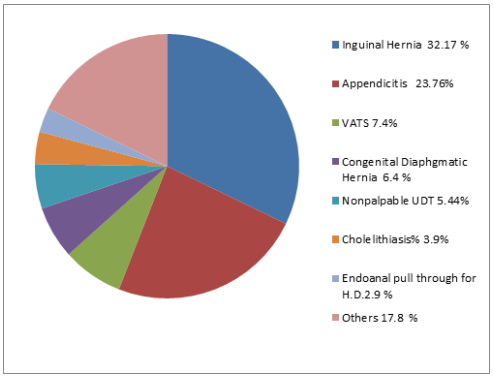

Figure 1: The common operations performed by Minimal Access Surgery

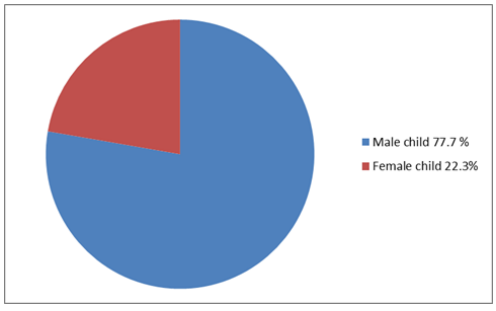

Figure 2: Depicting the Male :Female ratio

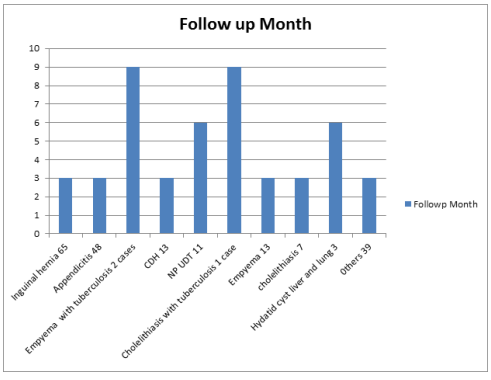

Figure 3: Depicting the mean duration of follow up

RESULTS:

During the study total of 202 cases were subjected to minimal access surgery in the year 2017. The mean age of presentation was 5.5 years (range neonates to 12 years).Male:Female ratio was 3.48:1 (157:45). 77.7% were males and 22.3% were females. Total number of cases subjected to:Laparoscopic procedures 84.15%(170/202) and Thoracoscopic procedures were 15.8% (32/202). Different operative procedures done have been depicted in Figure 1. There were no major intra operative complication, like Gas embolism or bleeding from major vessels. Mean operative Time was 1.20 minutes. (range-40min.-3.3hrs). Mean post operative Hospital stay: 2.15 days (range 1 day- 6 days). Conversion to open:4.45 %(9/202). All patients were followed up in our routine OPD for mean period of 3 months, except cases of empyema with tuberculosis,Cholelithiasis with tuberculosis, Hydatid Cyst, and undescended testis which required longer follow up. Our postoperative complications included, stitch granuloma, port site infections, and air leak in immediate postoperative period.

DISCUSSION:

Inguinal Hernia repair is the most commonly performed operation in Pediatric Surgery.[2] The advantage of laparoscopic hernia repair being, precise detection of patent processes vaginalis on the contralateral sidewith sensitivity of 99.4% and specificity of 99.5% and repair in the same sitting and hence an added advantage to conventional repair.[3].Besidesanother advantage being no touch technique to the vas and the vessels while repairing hernia.The reported recurrence rate in different studies investigating Minimal Access Surgery in Pediatric Inguinal Hernia has been 0-5%[3],ourrecurrence rate is zero% in the repairs done in that particular year with mean follow up of 3 months. This is attributed to the following reasons : 1. Use of nonabsorbable sutures in a purse string fashion. 2.Technical modification of an air tight closure of the ring taking the sub peritoneal tissue along with the peritoneum except at areas on vas and spermatic cord where only peritoneum was taken, by lifting it with the help of grasper, to protect the underlying structures. Before tying the knot, the scrotum was squeezed, to expel the gas and fluid present in the sac. Deflating the abdomen, before tightening the first knot to prevent loosening of the knot and reinflating the abdomen before the last knot is tied, and confirming air/ water tight ring closure.The average operative time for repair of unilateral hernia is 20-25 minutes and for bilateral hernias it is 30-35min[3], this value is slightly longer in our series which it is found to be 40- 45 min. in unilateral hernia.

Laparoscopic appendectomy is a commonly performed pediatric surgical procedure.[4] Our study had the number of cases of laparoscopic appendectomy next only to laparoscopic hernia. Also Laparoscopic appendectomy is one of the earliest done operations, as per the literature review.[4] Minimal Access Surgery is the standard of care for simple reason of smaller incisions, shorter hospital stays, and early return to preoperative activities.[1]All our cases average hospitalization stay was 2day+_6 hours.

Early intervention in cases of Empyema, by subjecting the patients to VATS, while the patient is still in the fibrinopulent stage, before it sets into organized state, have shown to decrease morbidity and hospital stay.[1] In our study also 9/15 cases were subjected to VATS within 7 to 10 days of onset of symptoms and were discharged with average time of hospitalization of 3 days.

Both laparoscopic and thoracoscopic approaches have been described in literature, for repair of Congenital Diaphragmatic Hernia,[5] the advantages of thoracoscopic approach being, better working space, easier reduction of abdominal contents, hence we have done all our cases using thoracoscopic approach. The only disadvantage being the risk of injuring the abdominal viscera while suturing. In literature review we found,Tsao, in his series of cases found, higher recurrence rate, in cases done using thoracoscopic approach which is contradictory to our finding.[6]

In nonpalpable undescended Testis, laparoscopy has stood the test of time both in diagnosis and management.[7] For cases which cannot be dealt by primary orchiopexy, a viable option to two staged Fowler Stephens is known as Shehata Technique, which is a two stage laparoscopic traction orchiopexy, in which the testis are anchored to opposite side anterior superior iliac spine, one inch above and medial for elongation of the testicular vessels without division. Hence division of Testicular vessels is avoided. SubdartosOrchiopexy is then done at the second stage. Both stages are laparoscopically assisted.[8] In our series we have done both Fowler Stephens and Shehata, with good postoperative results.

We have finally witnessed the disappearance of open cholecystectomy, with laparoscopic cholecystectomy becoming the gold standard of management for gall stones in children.[9]

Colostomy can be avoided in cases of Hirschsprung's disease by doing single stage Laparoscopic endorectal pull through.[10] We have done in 2/6 cases where primary endorectal pull through was done.Inanorectal malformation also minimal access surgery is a boon considering the fact that sphincter muscle complex is not cut.[10]

Laparoscopic Ramsted's Pyloromyotomy is a standard procedure, all cases were done laparoscopically in our study and had significantly reduced post operative hospital stay. This corraborates with the study done by Hall et. al.[11]Laparoscopic excision of the ovarian cyst with ovarian sparing surgery is the standard of care.[4]

Thus we see that almost all cases of Pediatric surgery are done by Minimal Access Surgery, the only disadvantage of being a very long learning curve, which involves observing, assisting, being assisted and

finally doing independently.The age old dictum; first do no harm,still holds true. Besides complex surgical procedures, like laparoscopic Pyeloplasty, laparoscopic Choledochal cyst excision, are too difficult and requires years of experience and surgical skill before one can venture into these. Years of hard earned reputation, can come to stake by a single hasty decision

CONCLUSION

As shown in the table, we have done almost all pediatric surgical procedures using MAS, and day is not far when all procedures would be totally replaced by MAS.The advantages being, smaller incisions, shorter hospital stay,lesser requirement for analgesics, decreased morbidity and early return to preoperative activities.

Ethics:
Ethics permission taken

Financial support and sponsorship:
Nil

Conflicts of interest:
There are no conflict of interest

REFERENCES

1. Zitsman, J.L.(2006). Pediatric Minimal-Access Surgery Update 2006. PEDIATRICS, 118, 304-308.
2. Parelkar, S.V., Oak, S., Gupta, R., Sanghvi, B., Shimoga. P.H.,Kaltari, D.(2010). Laparoscopic inguinal hernia repair in the pediatric age group—experience with 437 children. J Pediatr Surg, 45, 789–792.
3. Bharathi, R.S., Arora, M., Baskaran, V.(2008). Minimal access surgery of pediatric inguinal hernias: a review. Surg Endosc., 22,1751–1762.
4. Rai, R., Jacobsen, A.S.,(2014). Recent Advances in Minimal Invasive Surgery of Children. JIMSA, 27, 2.
5. Gomes, F.C., Reinberg, O., Becmeur, F.(2009). Neonatal minimally invasive surgery for congenital diaphragmatic hernias: a multicenter study using thoracoscopy or laparoscopy. Surg Endosc., 23,1650-1659.
6. Tsao, K., Lally, P.A., Lally, K.P.(2011). Congenital Diaphragmatic Hernia Study Group. Minimally invasive repair of congenital diaphragmatic hernia. 46, 1158-1164.
7. Francisco, T. D., Fernando, J. S,,Frederico, A. S., Amilcar, M. G., Marcos, M., Miguel, S.(2008). Laparoscopic diagnosis and treatment of nonpalpable testis. Int. Braz J. Uro. 34, 329-335.
8. Shehata,S., Shalaby,R ., Ismail, M., Abouheba, M., Elrouby,A (2016) Staged laparoscopic traction orchiopexy for intraabdominal testis (Shehata technique): Stretching the limits for preservation of testicular vasculature. J Pediatr Surg. 51(2),211-215.
9. Parelkar, S.V.(2014). Minimal access surgery in Pediatric Surgery. J Indian Assoc Pediatr Surg. 19(2), 59–60.
10. Shah,A.(2008) . A decade of minimal access pediatric surgery in India. JIAPS, J Indian Assoc Pediatr Surg. 13(4), 123–124.
11. Hall, N.J., Vanderzee, J., Tan, H.L., Pierro, A.(2004). Meta-analysis of laparoscopic versus open pyloromyotomy. Ann Surgery. 240,774–778.