RESEARCH PAPER | Engineering | Volume : 5 | Issue : 7 | July 2015 | ISSN - 2249-555X



Early Detection of Down Syndrome Marker Using Fetal Nasal Bone Length During First and Second Trimester

KEYWORDS: Down syndrome, nasal bone, morphological operation, erosion, dilation, thresholding.

*R.Sonia
Research Scholar, Sathyabama University, Chennai, India. * Corresponding Author

Dr.V.Shanthi
St. Joseph's College of Engineering, Chennai, India.

ABSTRACT *Down syndrome (DS) causes mild to moderate psychological retardation among fetus and it occurs 1/1000 live births. Even various approaches has been implemented for DS detection, still it is a challenging task in prenatal medicine. The main aim of this study is to provide an early DS detection system by measuring Nasal Bone Length (NBL) of a fetus in 13 to 19 weeks gestation period. In order to measure NBL, various sequential operations such as Region Of Interest (ROI), Nasal Bone (NB) segmentation using morphological, Otsu thresholding and logical operations are performed. From the detected NB image, NBL is computed by Euclidean distance measure. Based on the NBL measurement, ultrasound fetus images are classified into normal/abnormal. The experiments are carried out using 50 ultrasound fetus images. Results shows that NBL for a normal fetus is from 2.27 0.11 in the 13th week to a maximum of 5.24 0.12mm at the 19th week.*

INTRODUCTION

DS is a genetic disorder caused by the chromosome 21. If DS is not predicted or observed during gestation periods, it may tend to increase series health issues such as congenital heart disease, cognitive disability and thyroid disorders. Among various DS screening strategies, the identification of fetus nasal bone and its length is a reliable sonographic marker using ultrasound fetus images. Generally, persons with DS have a distinct craniofacial phenotype with a prominent forehead, small overall size of the craniofacial complex and underdevelopment of the fronto-naso maxillary region with missing or small nasal bones [1]. It also causes Alzheimer's disease and 15–20 times higher risk of leukemia [2].

A comparative study of NBL measurement of normal fetus between two different race; African-American and Caucasian is described in [3]. To obtain normal nasal bone length prenatal measurements, a standardized technique is applied on 3537 ultrasound fetus images. Maternal ethnic influence of NBL among Brazilian people is illustrated in [4]. According to maternal ethnicity, patients are separated into three groups: black, white, and Asian. The analysis of variance test is used to compare three ethnic groups NBL values. In order to calculate deviation among three measurements intra observer correlation coefficient, interclass correlation coefficient and Bland–Altman plots are used.

Measurements of fetal NBL and Nasal Bone Angle (NBA) during the second trimester are presented among normal Indian pregnancies in [5]. Fetus images of 17 weeks to 22 weeks gestation periods are used. NBL is measured in millimetres by strict sagittal view of the fetal head and NBA is measured in mid-sagittal profile. The results showed that NBL appears to be marginally longer in Indian fetus than other Asian fetus. First trimester fetal profile is analysed in [6]. It is stated that the abnormal fetus NBL has only a few millimeters in length. Sonographic studies described that the abnormalities of NBL in prenatal screening is strongly associated with trisomy 21. These abnormalities include both absence and hypoplastic of the nasal bone [7].

Chromosomal aberrations biometric parameters such as NBL and nuchal translucency thickness (NT) are considered as useful markers to detect fetal abnormalities [8]. DS is predicted by measuring three parameters such as crown-rump length, NT and NBL in two equal sub studies. These parameters are measured using 90 singleton pregnancies between 11 and 14 weeks of pregnancy. NBL measurement based DS detection approach is illustrated in [9]. Assessment of the NB may reduce the false-positive rate of a first-trimester genetic screen. In order to segment out NB region mean shift analysis is adopted and canny edge detector is utilized for NB edge detection [10].

DS detection in second trimester between 15 to 20 weeks of gestation is evaluated in [11]. Absence of nasal bone and short nose for DS is predicted using linear regression analysis. Mean maternal age and mean gestational age are compared by t-tests. Analysis is performed by using a Pearson correlation coefficient on the whites. Fetal NBL measurement is performed in [12] by two sonographers when the nasal bone line is completely missing. The assessment is completely based on Crown-rump length and maternal age with mean of 64.1 and 30.5 years respectively. A likelihood ratio for absence and presence of nasal bone are determined. The absence of nasal none is a powerful marker for DS with 90 percent detection rate and its determined using a fixed 1 in 250 risk cut-off, with the maternal age of 35 years [13].

In this study, an efficient NBL measurement approach for early detection of DS is presented using ultrasound fetus images. The experimental work of the proposed system is discussed in section 2. Section 3 describes the simulation results of the proposed system and conclusion is made in the last section.

METHODS AND MATERIALS:

The main aim of the proposed approach is the early detection of DS using ultrasound images by measuring the NBL of a fetus. In order to measure NBL effectively, three sequential approaches; ROI selection, NB segmentation and NBL measurement are followed in the proposed system. Figure 1 shows the computational modules of the pro-

Volume : 5 | Issue : 7 | July 2015 | ISSN - 2249-555X

posed NBL measurement system.

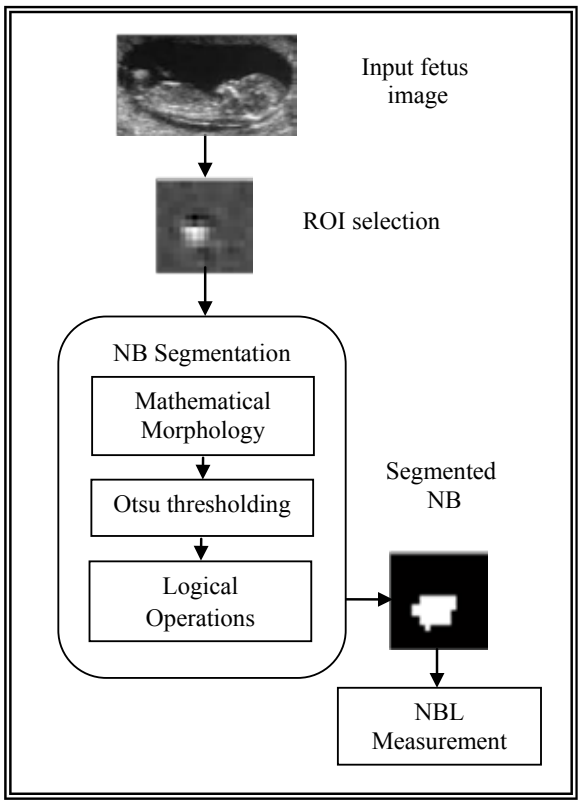


Figure 1: Proposed NBL measurement approach

ROI Selection:
The main purpose of ROI selection is to avoid the interferences from irrelevant organs or tissues while segmenting NB and also to reduce the computational time. Generally skin over the nasal bridge, nasal bone and nasal tip are appeared as three distinct lines in fetus ultrasound images. Two of them are similar to an "equal sign". The upper one indicated the skin and the bottom one represented the nasal bone. The third one, at a higher level of the skin, represented the tip of nose [14].

In order to obtain ROI from fetus ultrasound image, an approximate region around the NB is extracted. Figure 2 shows the NB region of the fetus image. After the selection of ROI, gray scale conversion is performed before NB segmentation process

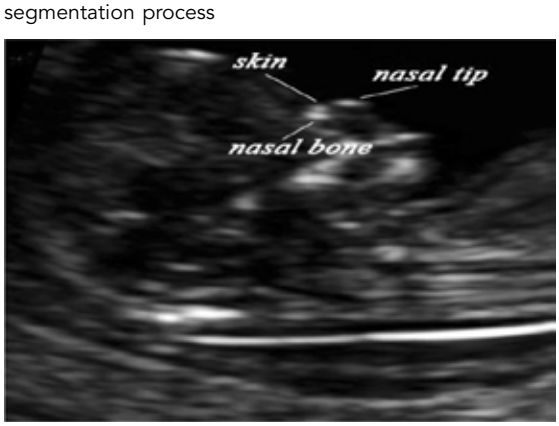


Figure 2: Ultrasound image in the midsagittal view showing NB, nasal skin and tip of nose

NB Segmentation:
To segment NB from the ROI image, the following three sequential operations: mathematical morphological operations, thresholding and logical operations on binary images are performed.

Morphological Operation:
Mathematical morphology is a frequently used tool in the field of image analysis for pre as well as post processing of image data. Among the various morphological operators, dilation and erosion are often used nonlinear transformations, which modify the geometric features of images. In order to point out the NB region, the proposed approach starts with erosion followed by dilation. Erosion shrinks the object as smaller and dilation expands the object as larger based upon certain reference images known as structuring element (SE). The erosion and dilation operations are performed using following eqn.

$$A\Theta B = \left\{i, j \,|\, B_{i,j} \subseteq A\right\} \qquad (1)$$

$$A \oplus B = \{i, j \,|\, B_{i,j} \cap A \neq \phi\} \qquad (2)$$

where A represents the binary or gray scale image and B denotes the structuring element and (i,j) indicates the current pixel element. Structuring element is a binary image of any size or mask having 0's and 1's, which defines an arbitrary neighbourhood structure for morphological process.

As NB looks like a line structure with orientation, SE of line shape is adopted for dilation and erosion with various angle of degree. The proposed approach uses line shape SE with the following orientations; 0, 30, 60 and 90 to effectively identify the NB region. Figure 3 shows the line shaped SE used in the proposed system.

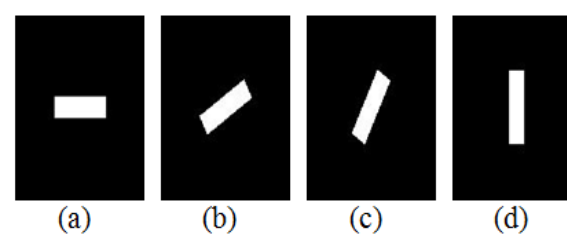


Figure 3: structuring elements used in morphological operations (a) 0 degree (b) 30 degree (c) 60 degree (e) 90 degree

Thresholding:
As morphological operations are applied on gray scale image, the output of the process is also a gray scale image. Hence in order to obtain the NB from the ROI very accurately, thresholding is applied. The ROI image contains NB and minimum background information. It requires a threshold value that separates the NB from its background.

Otsu's thresholding [15] is one of the superior and effective threshold selection methods for general real world images in association with consistency and shape measures. Otsu's segmentation performed on both gray level thresholds of each pixel as well as its Spatial correlation information within the neighborhood. Given an image X, made up of pixels, $(x_j,\ j=1,\ldots,N)$ with intensity values from $R=(1,2,\ldots,L)\subset Z$. It can say that the probability distribution of intensity value $i\in R$ in X is:

Volume : 5 | Issue : 7 | July 2015 | ISSN - 2249-555X

$$p_i = \frac{n_i}{N}, \quad p_i \geq 0, \quad \sum_{i=1}^{L} p_i = 1 \qquad (3)$$

That is, the number of pixels with intensity value i divided by the total number of pixels. Then, given that the image is to be divided into two classes c_0 and c_1 with a threshold at level k such that c_0 denotes pixels with levels [1, ... , k] and c_1 denotes pixels with levels [k+1,..., L], the probabilities of class occurrence (the odds that a randomly chosen pixel will be of a particular class) and the class mean levels, respectively, are given by:

$$\omega_0 = \Pr(c_0) = \sum_{i=1}^{k} p_i = \omega(k) \qquad (4)$$

$$\omega_1 = \Pr(c_1) = \sum_{i=k+1}^{L} p_i = 1 - \omega(k) \qquad (5)$$

And

$$\mu_0 = \sum_{i=1}^{k} i \Pr(i \mid c_0) = \sum_{i=1}^{k} \frac{i p_i}{\omega_0} = \frac{\mu(k)}{\omega(k)} \qquad (6)$$

$$\mu_1 = \sum_{i=k+1}^{L} i \Pr(i \mid c_1) = \sum_{i=k+1}^{L} \frac{i p_i}{\omega_1} = \frac{\mu T - \mu(k)}{1 - \omega(k)} \qquad (7)$$

where

$$\mu_T = \mu(L) = \sum_{i=1}^{L} i p_i \qquad (8)$$

is the overall mean level of the original image.

The class variances are given by:

$$\sigma_0^2 = \sum_{i=1}^{k} (i - \mu_0)^2 \Pr(i \mid c_0) = \sum_{i=1}^{k} (i - \mu_0)^2 p_i / \omega_0 \qquad (9)$$

$$\sigma_1^2 = \sum_{i=k+1}^{L} (i - \mu_1)^2 \Pr(i \mid c_1) = \sum_{i=k+1}^{L} (i - \mu_1)^2 p_i / \omega_1 \qquad (10)$$

which require the calculation of second-order cumulative moments. The proposed measure of optimality uses the following discriminant criterion measures or measures of class separability:

$$\lambda = \sigma_B^2 / \sigma_W^2; \quad k = \sigma_T^2 / \sigma_W^2; \quad \eta = \sigma_B^2 / \sigma_T^2 \qquad (11)$$

Where

$$\sigma_W^2 = \omega_0 \sigma_0^2 + \omega_1 \sigma_1^2 \qquad (12)$$

$$\sigma_B^2 = \omega_0 (\mu_0 - \mu_T)^2 + \omega_1 (\mu_1 - \mu_T)^2 \qquad (11)$$

$$\sigma_T^2 = \sum_{i=1}^{L} (i - \mu_T)^2 p_i \qquad (13)$$

are the within-class variance, the between-class variance, and the total variance of levels, respectively. As σ_T^2 is constant over the whole image, the expense of its calculation can be disregarded. Since σ_W^2 requires first and second order statistics, but σ_B^2 requires only first-order statistics, η is the simplest criterion to calculate.

The optimal threshold k^* that maximizes, or equivalently maximizes the between-class variance σ_B^2 is selected by sequential search using the following derivations of the previous formulae:

$$\eta(k) = \sigma_B^2(k) / \sigma_T^2 \qquad (14)$$

$$\sigma_B^2(k) = \frac{[\mu T \omega(K) - \mu(k)]^2}{\omega(k)[1 - \omega(k)]} \qquad (15)$$

As σ_T^2 is constant, the solution can be given as:

$$k^* \leftarrow \max_{1 \leq k < L} \sigma_B^2(k) \qquad (16)$$

This solution provides a crisp threshold value which gives the best distinction between foreground and background pixels according to statistical analysis [15]

Logical AND Operation:

As the proposed system uses four different SE in the morphological operation, 4 different outputs are obtained. All these outputs are processed in the thresholding stage that uses Otsu thresholding. Hence, 4 different binary outputs are obtained. In order to provide optimal NB segmented region, logical (Boolean) AND operator is applied on all binary output which produces a binary image wherein the pixels in the background values are equal to 0 and the nasal bone region are 1.

NBL Measurement:

Finally, NBL is measured from the binary output obtained from the logical AND operation. It is computed by calculating the euclidean distance between the NB start and end location. These locations are obtained by searching the true pixels by column wise from left to right and right to left as the true pixels are NB. If the identified start position is ($start_x$, $start_y$) and end position is (end_x, end_y), then the euclidean distance is computed using the following formula

$$D = \sqrt{(end_y - start_y)^2 + (end_x - start_x)^2} \qquad (17)$$

RESULTS AND DISCUSSIONS:

The performance of the proposed system is evaluated using 50 ultrasound fetus images (35 normal and 15 abnormal images). The gestational age of the acquired images are from 13 to 19 weeks. There are 5 images in each gestational week are available for evaluation. The NBL is measured using the proposed approach. Figure

Volume : 5 | Issue : 7 | July 2015 | ISSN - 2249-555X

4 shows ultrasound normal fetus image and its extracted ROI. Figure 5 shows the output images at each stage of the proposed system for normal fetus image. Figure 6 and 7 shows the sample abnormal fetus and its corresponding sequential process to detect the NB region

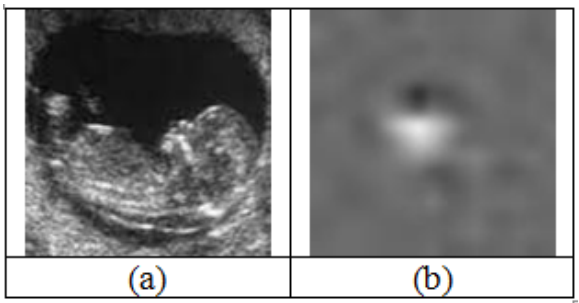


Figure 4: (a) sample normal fetus image (b) corresponding ROI image

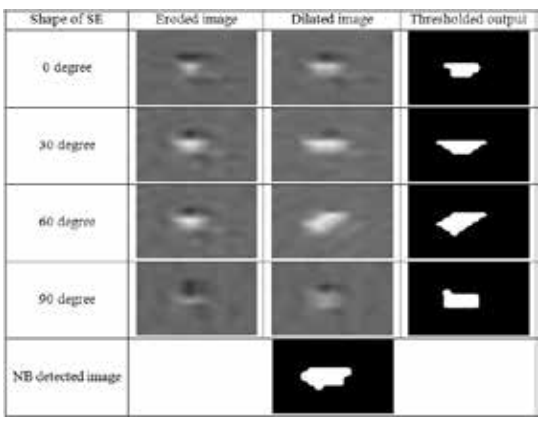


Figure 5: Output images at each stage of the proposed system and final NB image for normal fetus

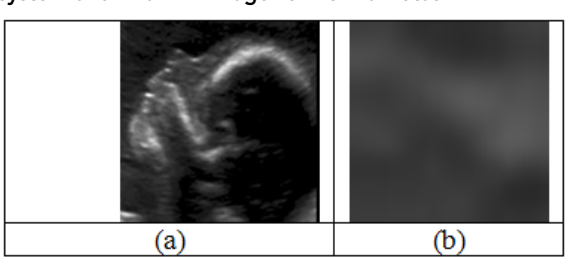


Figure 6: (a) sample abnormal fetus image (b) corresponding ROI image




Figure 7: Output images corresponding with NB image for abnormal fetus

The non existence of NB region clearly shows the abnormality of fetus. The proposed NBL measurement approach is applied to all the images in the database and their NBL is shown in table 1.

TABLE – 1
NASAL BONE LENGTH IN SECOND TRIMESTER MEASURED FOR NORMAL FETUS

Gestation Weeks	Avg.	SD.
13	2.27	0.11
14	2.92	0.04
15	3.25	0.11
16	3.92	0.13
17	4.33	0.02
18	4.61	0.09
19	5.24	0.12

From the table 1, it is observed that NBL is estimated from 2.27 0.11 in the 13th week to a maximum of 5.24 $\pm$ 0.12mm at the 19th week. Based on the obtained results, the abnormal images can be easily distinguishable at the earliest. Figure 8 shows the graphical representation of NB development of 13 to 19 week gestation period fetus. It is observed that NBL gradually increases in proportion with gestation weeks.

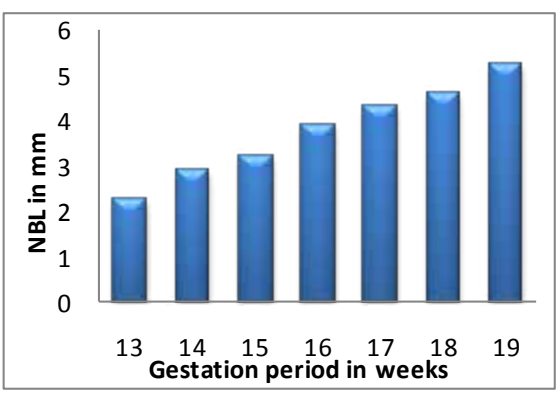


Figure 8: NBL of normal fetus vs. Gestation period

CONCLUSIONS

In this paper, an efficient approach for early detection of DS is proposed by measuring NBL for normal and abnormal fetus ultrasound images in second trimester. The proposed system uses image processing approaches such as morphological and Otsu thresholding to segment NB very accurately. The assessment of NBL in second trimester gives better result in the nasal bone detection. As the gestational age increases the visibility of nasal bone is clear in the normal fetus. The experimental results show that the proposed approach yields maximum NBL of 5.24 $\pm$ 0.12mm for 19 week normal fetus. The proposed NBL estimation technique can help the physicians to detect DS at the earliest.

Volume : 5 | Issue : 7 | July 2015 | ISSN - 2249-555X

REFERENCE

[1]Larose, C., Massoc, P., Hillion, Y., Bernard, J. P., and Ville, Y. (2003), "Comparison of fetal nasal bone assessment by ultrasound at 11–14 weeks and by postmortem X-ray in trisomy 21: a prospective observational study", Ultrasound in obstetrics & gynecology, 22(1), 27-30. | [2] Khalil, A and Pandya, P. (2006), "Screening for Down syndrome", The Journal of Obstetrics and Gynecology of India , 56(3), 205–211. | [3]Sonek, J. D., McKenna, D., Webb, D., Croom, C., and Nicolaides, K. (2003), "Nasal bone length throughout gestation: normal ranges based on 3537 fetal ultrasound measurements", Ultrasound in obstetrics & gynecology, 21(2), 152-155. | [4]Cossi, P. S., Bussamra, L. C. S., Júnior, E. A., Nardozza, L. M. M., and Moron, A. F. (2008), " Ethnic variation and variability of fetal nasal bone length at 11–15 weeks of gestation in a Brazilian population: preliminary results", Archives of gynecology and obstetrics, 278(5), 431-435. | [5]Kashikar, S. V., and Lakhkar, B. N. (2015), "Assessment of Fetal Nasal Bone Length and Nasofrontal Angle in the Second Trimester in Normal Indian Pregnancies.", Journal of Fetal Medicine, 1(3), 137-141. | [6]Cicero, S., Bindra, R., Rembouskos, G., Tripsanas, C., and Nicolaides,K.H. (2002), "Fetal nasal bone length in chromosomally normal and abnormal fetuses at 11-14 weeks of gestation", The Journal of Maternal–Fetal and Neonatal Medicine, 11, 400–402 . | [7] Sonek, J.D., Cicero, S and Neiger, R. (2006), "Nasal bone assessment in prenatal screening for trisomy 21", American Journal of Obstetrics and Gynecology. 195, 1219–1230. | [8]Sieroszewski, P., Perenc, M., Bas-Budecka, E and Suzin, J. (2006), "Ultrasound diagnostic schema for determination of increased risk for chromosomal fetal aneuploidies in the first half of pregnancy", Journal of Applied Genetics 47(2), 177–185. | [9]Stevenson, S. (2008), "Nasal Bone Measurement to Diagnose Down syndrome", Newborn and Infant Nursing Reviews, 8(1), 7-10. | [10]Nirmala, S., and Palanisamy, V. (2011), "Clinical decision support system for early prediction of Down syndrome fetus using sonogram images. Signal, Image and Video Processing, 5(2), 245-255. | [11]Bromley B, Lieberman E, Shipp TD and Benacerraf BR. (2002), "Fetal nose bone length: a marker for Down syndrome in the second trimester", Journal of Ultrasound in Medicine, 21, pp 1387–1394. | [12]Bekker, M.N., Twisk, J.W.R and van vugt, J.M.G, (2004), "Reproducibility of the fetal nasal bone length measurement. Journal of Ultrasound in Medicine", 3, 1613–1618 . | [13]Orlandi,C.M.Bilardo,M. Campogrande,D.Krantz,T.Hallahan,C.Rossi and E.Viora, "Measurement of nasal bone length at 11–14 weeks of pregnancy and its potential role in Down syndrome risk assessment", Ultrasound Obstet Gynecol 2003. | [14]Suwanrath, C., Pruksanusak, N., Kor-anantakul, O., Suntharasaj, T., Hanprasertpong, T., and Pranpanus, S. (2013), "Reliability of fetal nasal bone length measurement at 11–14 weeks of gestation", BMC pregnancy and childbirth, 13(1), 7. | [15]Otsu, N. (1979), "A Threshold Selection Method from Gray-Level Histograms", IEEE Transactions on Systems, Man, and Cybernetics. 9 (1), pp. 62-69. |