Original Research Paper

Volume-9 | Issue-7 | July - 2019 | PRINT ISSN No. 2249 - 555X

Zoology

EFFECT OF GENETICALLY MODIFIED DIET ON STOMACH OF ALBINO FEMALE RATS

Dr. Varsha V. Andhare Department of Zoology, The Institute of Science, 15, Madam Cama Road, Mumbai 400032

Prachi S. Dandge* Department of Zoology, The Institute of Science, 15, Madam Cama Road, Mumbai 400032 *Corresponding Author

ABSTRACT The present study was performed to investigate the histological effects of genetically modified diet on stomach of female albino rats. Bt cotton seeds were incorporated into the diet of female albino rats as Bt cotton is the only GM crop available in India. The study was conducted on 18 female albino rats; the animals were divided into 3 equal groups. The first group was given normal diet with wheat, casein and groundnut powder and used as control group. The second and third groups were given 2 g /kg of body weight of Bt and non Bt cotton seed powder along with wheat and casein respectively for 60 days. The animals were anesthetized; stomachs were removed for histological studies. Histological changes which observed in the stomach were hemorrhages with degenerative changes, congestion.

KEYWORDS : Histological study, Bt cotton, albino rat, stomach

INTRODUCTION

In the last 15 yrs., modern technology enables to insert the target genes and obtain specific traits; this provides opportunities for more rapid developments in animal and plant genetic improvements (Beever and Phipps, 2001). Currently, most genetically modified plants in the marketplace provide insect protection or herbicide tolerance and used as feed for livestock (Clark and Ipharraguerre, 2001). These crops offer producers an alternative strategy for managing weed pressure and insect pests. Soybean, maize, cotton and canola are the major crops that have got approved as GM foods while eggplant, papaya, potato, rice, sugar beet, sunflower, sugarcane, and tomato are also in production around the world, GM crops can fulfill the food demand of increasing population so it is beneficial to the developing country to overcome the problem of food crisis. As it contains more nutrias ingredients of vitamins or proteins, so hunger and starvation problem can be reduced up to some extent.

Cotton has been modified by the introduction of specific DNA sequences containing either the cry1Ac gene (Bollgard cotton) or both the cry1Ac and cry2Ab genes to produce Bollgard II cotton; the production of the CP4 EPSPS protein by the plant provides tolerance to glyphosate which is active ingredient in Roundup (Harrison et al., 1996). However there is concern about genetically modified foods as more amount of vitamins and proteins leads to major health issues. So present study was conducted to observe the effect of GM diet (*Bt* cotton) in stomach of female albino rats.

2. Collection and Preparation of powder:

The *Bt* and non Bt cotton seeds were collected from Mahyco, Maharashtra which is easily available in market. The specimens were washed, dried and powdered coarsely.

2.1. Experimental animals:

Albino Wister rats of female sex, weighing 100-110g, were kept in separated cages under standard environmental conditions of temperature 20 to 30ºC and humidity were provided with standard rat chow and water ad libitum. The experimental procedures were carried out in strict compliance with the institutional animal ethical committee regulations.

2.2. Treatment protocol: The animals were divided into 3 groups of 6 animals each and treated as per the protocol given below:

Control Group (G1): The animals were given normal diet of wheat, casein and groundnut powder for 60 days.

Treatment Group (G2): The animals were given 2g of *Bt* cotton seed powder with wheat and casein.

Treatment Group (G3): The animals were given 2g of non *Bt* cotton seed powder with wheat and casein.

Fresh feed was given daily at 09:00 h in an excess of 10% of previous days intake after discarding the residue.

2.3. Schedule of sacrification and collection of organs: On completion of experiments, the animals were anesthetized by exposure to amount of diethyl ether. The stomachs from different groups were dissected out, blotted free of blood and preserved for histological studies.

2.4. Histological studies: Stomach sections were preserved in 10% formalin. They were dehydrated in ascending series of alcohol, cleared in xylene and embedded in paraffin wax. 5µm thick sections were obtained by rotary microtome. They were stained with haematoxylin and eosin, observed under the microscope to estimate the effect of *Bt* cotton.

3. RESULT

Fig. (1) The sections from G1 showed normal histology of the stomach. The stomach wall consists of four layers i.e. a mucosa, submucosa, muscularis externa, and a serosa. The innermost layer is the mucosa which reveals three distinctive regions. The superficial regions contain the gastric pits, the middle region contains the necks of the glands, which stains with eosin. The deepest part of the mucosa stains blue. . The luminal surface of the stomach with numerous tiny openings, called gastric pits. These are formed by the luminal epithelium that invaginates the underlying connective tissue, lamina propria of the mucosa. The luminal surface with small openings called as gastric pits formed by the luminal epithelium underlying connective tissue, lamina propria of the mucosa. The tubular gastric glands are located below the luminal epithelium, open directly into the gastric pits to deliver their secretions into the stomach lumen. The gastric glands descend through the lamina propria to the muscularis mucosae. The gastric pits, eptithelial cells, stratified squamous, muscosyl and submucosyl layers are observed. No marked changes are observed in G1 i.e. control female rats stomach. The fig. (2) Showing significant histological changes which were noted in stomach of female rat fed with *Bt* cotton i.e. multifocal congestion, Focal MNC infiltration with multifocal degenerative changes. In some tissue multifocal hemorrhage was observed as compared to G1 and G3 group.

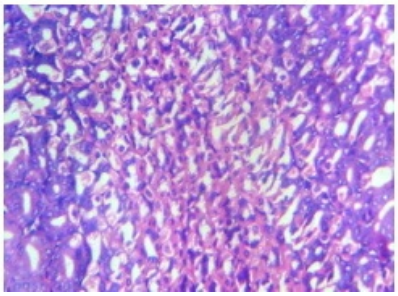

Fig. (1): Microphotograph of stomach showing normal histoarchitecture from control group (G1) female rat treated with (normal) diet (H&E 100X).

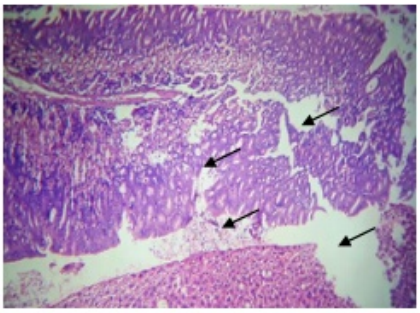

Fig. (2): Microphotograph of stomach showing changes in histoarchitecture from Treatment Group (G2) with 2 g/ kg BW Bt cotton seed diet (H&E100X).

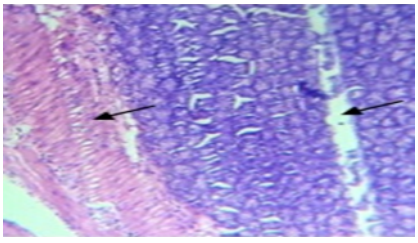

Fig. (3): Microphotograph showing mild changes in structure of stomach from Treatment Group (G3) with 2g/ kg BW non *Bt* cotton seed diet.

4. DISCUSSION AND CONCLUSION

There is necessity to develop comprehensive toxicological or nutritional methods to screen for the unintended potentially deleterious effects for human and animal health due to genetic manipulation and the problems occurred due to the incorporation of the GM food stuff into the food chain (Ewen and Pusztai). Stomach , part of the digestive tract, which is the first and largest point of contact with foods, can reveal various reactions to toxins and should be the first target of GM food risk assessment. In the present work, significant structural abnormalities observed in the stomachs of experimental group (Bt cotton seed) animals which is an agreement of GM foods having effect on balancing of gut bacteria (Steinbracher 2002). When *Bt* corn diet given to pigs, there were no significant difference observed in overall health. Female rats fed with GM tomato there was development of stomach lesions with endangering hemorrhage. There was severe mortality seen in sheep due to toxicity after grazing on GM cotton fields (Ho 2006). However feeding of Bollgard II cottonseed did not have adverse effect on dairy cattle (Singhal et al., 2011), *Bt* cotton seed feeding did not have any histopathological changes in growing lamb (Tripathi et al 2011). According to Romeis et al (2004) In Philippines Bt maize caused symptoms like severe stomach pain and vomiting in people living near the GM maize field. GM foods caused hepatorenal toxicity, digestive problems, damaged in internal organs (Seralini et al 2007). Mice when fed with GM maize for four generations abnormal structural changes occurred in major organs mainly in the pattern of gene functioning in gut. Roundup ready soya diet showed significant changes in alpha amylase enzyme which could inhibit digestion (Malatesta et al 2002). While chronic study of GM glyphosate soybean feeding in rats showed different pattern of growth, organ and histopathological finding than the rats fed with non GM soybeans. GM soybean of 30% showed no apparent adverse effects in rats in long term intake (Sakamoto et al 2008). There was an increased in organ injury observed in sheep treated with *Bt* cotton in comparison with normal cotton seed fed sheep group (Ramdas 2009). In 3 years study on the effects of GM diet containing *Bt* 176 maize showed no changes in performance of sheep and organs but cytochemical analyses showed proliferation of basal cells in GM maize fed sheep (Malatesta et al 2008). GM potatoes caused adverse effects on body of the rats in ten days while mice fed on GM soy over 24 months duration showed liver aging effects (Malatesta et al 2008). The potatoes engineered to produce the Bt-toxin developed abnormal and damaged cells, proliferative cell growth in the lower part of their small intestine (ileum) and stomach in mice .

The GM diet *(Bt* cotton) caused deteriorate effects in Stomach as compared to non *Bt* cotton seeds and control diet.

REFERENCES:

[1] Beever, D. E., and R. H. Phipps. 2001. The fate of plant DNA and proteins in novel feeds for farm animals. Pages 67–75 in Proc. 24th Congr. Argen. Assoc. Anim. Prod., AAPA. Rafaela, Argentina.

[2] Clark, J. H., and I. R. Ipharraguerre. 2001. Livestock performance: Feeding biotech crops. J. Dairy Sci. 84(E. Suppl.):E9–E18.

[3] T.A. Mitsky, M.L. Taylor, Harrison, L. A., R. L. Fuchs and S.R. Padgette, M.R. Bailey, M. W. Naylor, J.E. Ream, B.G. Hammond, D.L. Nida, B.L. Burnette, T.E. Nickson (1996) the expressed protein in glyphosate- tolerant soybean 5- enolypyruvylshikimate-3-phosphate synthase from Agrobacterium sp. Strain CP4 rapidly digested in vitro which is not toxic to acutely gavaged mice.J. Nutr.126:728-740.

[4] Singhal KK, Tyagi AK, Rajput YS, Singh M, Kaur H, Perez T, Hartnell G (2011) Feed intake, milk production and composition of crossbred cows fed with insect production and composition of crossbred fed with insect BGII protein Ani. 5:1769-1773.

[5] Tripathi M K, Mondal D, Somvanshi R, Karim S A (2011) Hematology, blood biochemistry and tissue histopathology of lambs maintained on diet containing an insect controlling protein (Cry 1 Ac) in Bt- cottonseed. J. Animal Phy. Ani. Nutri. 95: 545.

[6] Steinbracher R (2002) Risk associated with ingestion of Chardon LL maize, The reversal of N- acetyl-L- glucofosinate to the active herbicide L- glufosinate in the gut of animals Chardon LL Hearing, May 2002, London.

[7] Ho M W (2006) Mass death in sheep grazing on Bt cotton. Sci in Society30: 12-3.

[8] Romeis J, Dutton A and Bigler F (2004) Bacillus thuriengiensis toxin (Cry 1 Ab) has no direct effect on larvae of the green lacewing Chrysoperla carnea (Stephens) (Neuroptera: Chrysopidae).J Insect Phy.50:175-82.

[9] Seralini G E, Cellier D, de Vendomois S J (2007) New analysis of a rat feeding study with a genetically modified maize reveals signs of hepatiorenal toxicity. Arch Env. Cont. Toxi. 52: 592-602.

[10] Malatesta M, Caporaloni C, Rocchi M BL, Tiberi C and Gazzanelli G (2002) Ultrastructural morpho metrical and immunocytochemical analyses of hepatocyte nuclei from mice fed on genetically modified soybean. Cell Struc. Fun27: 173-80.

[11] Sakamoto Y, Tada Y, Fukumori N, Tayama K, Yuzawa K, Nagasawa A, Takahashi H, Yano N, ogata A (2008) A 104- week feeding study of Genetically modified soybeans in F344 rats. Jour. Food Hyg. soc Japan 49: 272-82.

[12] Impacts, Bio-safety concern and the Legitimacy of Public Scientific Research Institutions. Paper presented at National workshop on genetically modified crops/foods & Health impact. Greenpeace India and Sust on July 8-9 at India International Centre , New Delhi.

[13] Serafina B, Marco B and Daniela Q,(2008) A long- term study on female mice fed on a genetically modified soybean, effects on liver aging. Histochem 49: 237-42.

[14] Amagliani G Brandi G, Rondini C, Giammarini C, Costarelli S, Acuti G, Orlandi C, Filippini G, Malatesta M, Crotti S, Manuali E, Mastrogiacomo AR, Moscati L, Haouet MN, Gaiti A (2008). A three year longitudinal study on the effects of diet containing genetically modified Bt 176 maize variety on health status and performance of sheep. Live. Sci. 113:178-190.

[15] Castillo AR, Gallardo MR, Maciel M, Giordano JM, Conti GA, Quaino O, Gianni C, Hartnell GF (2004) Effects of feeding rations with genetically modified whole cottonseed to lactating Holstein cows. J. Dairy Sci. 87: