RESEARCH PAPER | Medical Science | Volume : 5 | Issue : 6 | June 2015 | ISSN - 2249-555X



# First Trimester Vaginal Bleeding – Evaluation by Ultrasound

KEYWORDS: first trimester vaginal bleeding ;Ultrasonography ;abortions; molar pregnancy ; ectopic pregnancy

Savitri Somashekar

**ABSTRACT** *INTRODUCTION : Early & correct diagnosis of first trimister vaginal bleeding by sonography has helped to institute appropriate timely management in cases of various types of abortion, ectopic & molar pregnancies.*

*MATERIAL & METHODS: One hundred cases of first trimister vaginal bleeding underwent either Transabdominal or transvaginal ultrasound.*

*Clinical evaluation was combined with ultrasound diagnosis. Treatment was instituted accordingly. Supportive therapy for threatened abortion; evaccuation in inevitable / incomplete abortion ,molar pregnancy ; laporatomy in ectopic pregnancy.*

*OBSERVATIONS AND RESULTS: This presentation was common in younger age group (16 to 25 yrs ) more so in primi and second gravid..*

*Various types of abortions were the commonest cause for first trimester vaginal bleeding .Early institution of treatment after proper diagnosis has decreased morbidity , at times ,mortality for the women .*

*DISCUSSION: Ultrasound has not only clinched the diagnosis but also helped timely management in cases of 1st trimester vaginal bleeding*

*CONCLUSION: Ultrasound is a simple , non invasive diagnostic modality available in current day practice to diagnose and manage first trimester vaginal bleeding*

## INTRODUCTION

Obstetric ultrasound has evolved as primary diagnostic modality in first trimester vaginal bleeding. The latter is a fairly common occurrence & estimated to occur approximately in 25% of all pregnancies ( clinically diagnosed).

Differential diagnosis includes all types of abortions ( missed, incomplete, inevitable, complete) , ectopic pregnancy, molar pregnancy,implantation bleeding & subchorionic haematoma.

Ultrasound plays a key role in accurately clinching the diagnosis ( more so with a transvaginal probe ). It helps to institute timely management ; at times even averting fatality as in ectopic pregnancy.

Clinical examination complements the ultrasound diagnosis.

**Differential Diagnosis**

| Diagnosis | Ultrasound finding |
|---|---|
| Implantation bleeing | Intrauterine GS with a Fetal pole |
| Inevitable/Incoplete abortion | Products in process of expulsion |
| Threatened abortion | Live fetus with cardiac Activity |
| Complete abortion | Empty cavity |
| Ectopic pregnancy | Extra uterine Gestational sac or Significant free fluid in POD |
| Molar pregnancy | Absent GS |

Incidentally we may also diagnose multiple pregnancy & adnexal pathology.

## REVIEW OF LITERATURE

Ultrasonography in first trimester of normal pregnancy : Gestational sac representing the chorionic activity is the first definitive sonographic sign of early pregnancy which is seen by 5 weeks of menstrual age .This is also characterized by a double echogenic ring appearance (Nyberg et al ) produced by decidua parietalis .

In normal pregnancy the sac increases by almost 1.2 mm / day.No growth or growth less than 0.7mm/ day is a poor prognostic sign.

Yolk sac is the earliest embryonic land mark (5 weeks). It's a regular, circular structure within the sac and has a very bright echogenic ring around a sonoluscent centre. It grow upto 9$^{th}$ week and later regresses and disappears.

Fetal pole can be imaged as an echo producing structure between 6 & 7 weeks in 50% of pregnancies . By 8 weeks , its seen in all. Fetal cardiac activity is seen as a tiny fluttering structure within the fetal body . Appearance of amnion is described as ' double bleb sign ' which is identified by 7 weeks . placenta gets delineated by 9 th week . Embryonic movements are seen by 8 to 8 ½ weeks.

**For abnormal getational sac.**
**Major criteria:**
1) A large sac size ( > or equal to 25 mm MSD without embryo or equal to 20 mm MSD without yolksac )

Volume : 5 | Issue : 6 | June 2015 | ISSN - 2249-555X

2) A distorted gestational sac shape .

**Minor criteria :**
1) A thin (< or equal to 2 mm ) decidual reaction .

2) Weak decidual amplitude

3) Irregular contour

4) Absent double decidual sign

5) Low position

3 minor criteria or 1 major criterion is needed to make the diagnosis of embryonic demise.

• First trimester vaginal bleed in presence of ultrasonic evidence of healthy GS of size corresponding to the period of amenorrhea (upto 8 weeks) with a closed internal OS and a measurable CRL with a definite fetal heart motion & a normal fetus to sac ratio (9-12 weeks ) could be termed as threatened abortion .

Presence of large subchorionic haematoma indicate a poor outcome for the fetus .

• **Blighted ovum – Sonographic criteria**
a) The presence of a GS with a diameter of 3cm or more or a volume of 2.5ml or more with no fetal pole .

b) Failure of GS to increase in size by atleast 75% over a period of one week

c) Failure to identify fetal pole by 8 completed weeks from LMP.

d) Appearance of sac which is quite irregular in shape and thin walled ( reduced echogenicity of wall )

e) Seperation of sac from uterine wall (subchorionic haematoma )

• **Missed abortion or intrauterine fetal demise ( fetus dies and retained with the uterus )**
Sonographic demonstration of a fetus with no evidence of fetal life ( cardiac activity or fetal movement ). Amniotic fluid volume may be diminished.

• **Incomplete abortion**
Products of conception are expelled partly from uterine cavity or gestational sac may lie at the level of cervix & may be in the process of being aborted.

• **Hydatidiform mole**
Classified as complete or partial mole depending on the presence or absence of fetal pole.In classic pattern the uterus is typically filled with echoes of weak to moderate strength (snow storm pattern or snow flake appearance) Atypical pattern results from presence of bloodclots within the mole which are seen as echofree spaces. 40% of moles are associated with thecalutein cysts in the ovaries.

• **Ectopic Pregnancy - There is no evidence of intrauterine pregnancy.**
**Extrauterine findings**
- Evidence of intact ectopic gestational sac is uncommon

- Evidence of haemoperitoneum may be seen as cresentic echo free area in the culdesac..

- Evidence of complex adnexal mass predominantly cystic.

AIMS

1 . Ultrasound diagnosis of all cases of first trimester bleeding per vagina.

2 . To evaluate abnormal & normal on going pregnancies.

**MATERIAL & METHODS**
This study was done in Department of Obstetrics & Gynaecology , GGH , Kurnool from Jan 2008 to July 2008.

One hundred pregnant women presenting with bleeding per vagina were included in the study.

Other criteria for inclusion were 3 months of amenorrhoea & positive pregnancy test (urine sample) ; All gravidae were included

Bleeding PV ranged from scanty to heavy flow.

Ultrasound examination ( transabdominal / transvaginal ) was done to note the gestational sac ( intrauterine or otherwise ), fetal pole,

Cardiac activity & CRL of fetus ; also Coexisting uterine &/ adnexal pathology if any noted.

Clinical examination was done in suspected cases of inevitable , incomplete , complete abortions to asses the cervical status & managed accordingly.

Diagnosed cases of ectopic pregnancy underwent salphingectomy by laporatomy.

**OBSERVATION & RESULTS**
One hundred pregnant women in first trimester presenting with bleeding per vagina formed the Study group

Age wise : 49% of cases in 16 to 20 yrs

31% of cases in 21 to 25 yrs

15% of cases in 26 to 30 yrs

5% of cases in 31 to 40 yrs

**Gravid Status**
This clinical condition was most common in Primi & second gravid ( 37% & 38%).Less common in third & fourth gravidae.

Distribution of cases by ultrasound & clinical diagnosis

Various abortions constituted 74%

13% of cases were diagnosed as ectopic pregnancy. 6% of cases found to be molar pregnancy.

Out of 100 cases, 30 cases of threatened abortion continued pregnancy and 12 cases of threatened abortion went in for complete abortion. 39 cases of nonviable pregnancy were evacuated.

13 cases of ectopic pregnancy underwent salphingectomy by laparotomy.

Volume : 5 | Issue : 6 | June 2015 | ISSN - 2249-555X

6 cases of complete abortion needed no intervention

| S NO | Sonar Diagnosis | No of cases | Percentage |
|---|---|---|---|
| 1 | Threatened abortions | 42 | 42% |
| 2 | Incomplete abortions | 16 | 16% |
| 3 | Missed abortions | 10 | 10% |
| 4 | Complete abortions | 06 | 6% |
| 5 | Inevitable abortions | 01 | 1% |
| 6 | Ectopic gestation | 13 | 13% |
| 7 | Molar pregnancy | 06 | 6% |
| 8 | Blighted ovum | 05 | 5% |
| 9 | Normal pregnancy | 01 | 1% |
| | Total | 100 | 100% |

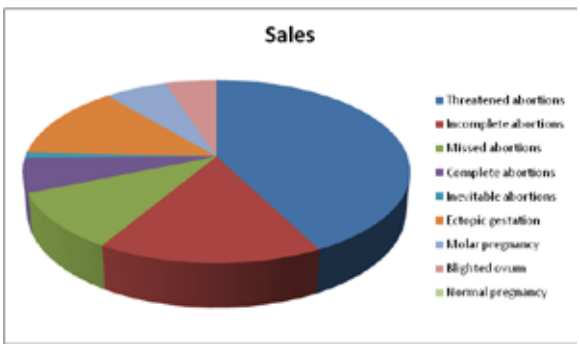


## DISCUSSION

Ultrasound has revolutionized the diagnosis and management of first trimester vaginal bleeding.

Accurate diagnosis by sonography has helped timely treatment of ectopic pregnancy, threatened abortion,missed abortions,molar pregnancy; at times averting catastrophies.

Accuracy of clinical diagnosis in threatened abortion cases were 75.47%, in incomplete abortion cases 64.705 and in ectopic and molar pregnancy 100%

Out of 42 cases of threatened abortion , 3 cases had subchorionic heamatoma which terminated in miscarriage.

One case of incomplete abortion showed a septate uterus and in rest cause for pregnancy failure was not made out .

Missed abortion (bligtful ovum ,intrauterine fetal demise ) & inevitable abortion were confirmed quickly by Ultra Sound and this facilitated early decision for termination .

Complete abortion was easily diagnosed by Ultra Sound looking at the linear endometrial echo and empty uterus . this helped in preventing unnecessary intervention and fecilitated early discharge from hospital .

Ectopic and molar pregnancies were diagnosed accurately by Ultra Sound and managed appropriately, reducing patient morbidity & mortality

**Ultrasound diagnosis in first trimester vaginal bleeding – Various studies**

| Sl no | Sonar diagnosis | R.Rajan & V.Rajan | Raj Cheema | N.Malhotra Jaideep Malhotra | J.E.Drum's study | Neelam Bharadwaj study | Present Study |
|---|---|---|---|---|---|---|---|
| 1 | Threatend abortions | 54.05% | 58.3% | 45% | 32.5% | 57% | 42% |
| 2 | Incomplet abortions | - | 2% | - | 28.1% | 26% | 16% |
| 3 | Missed abortions | 5.41% | 12.5% | 9% | 10.8% | 8% | 10% |
| 4 | Complete abortions | - | - | - | 17.1% | - | 5% |
| 5 | Blighted ovum | 18.92% | 22.9% | 11% | 11.1% | - | 6% |
| 6 | Inevitable abortions | - | - | 3% | - | - | 1% |
| 7 | Ectopic pregnacy | 5.41% | 4% | 8% | - | - | 13% |
| 8 | Molar pregnacy | 16.22% | 1.6% | 5% | 0.1% | 4% | 6% |

**Correlation of Clinical diagnosis with Ultrasound Diagnosis**

| Sl no | Clinical diagnosis | No of cases | Ultrasound diagnosis | No of cases | Clinical accuracy |
|---|---|---|---|---|---|
| 1 | Threatened abortions | 53 | Threatened abortion<br>Missed abortions<br>Incomplete-abortion<br>Blighted ovum | 40<br>60<br>05<br>02 | 75.47% |
| 2 | Incomplete abortions | 17 | Incomplete abortion<br>Complete abortions<br>No pregnancy | 11<br>05<br>01 | 64.70% |
| 3 | Missed abortions | 11 | Missed abortions<br>Blighted ovum<br>Threatened abortion<br>Inevitable abortions<br>Normal pregnancy | 04<br>03<br>02<br>01<br>01 | 36.4% |
| 4 | Ectopic gestation | 12 | Rupture Ectopic<br>Tubal abortion | 10<br>02 | 100% |
| 5 | Molar pregnancy | 06 | Complete mole | 06 | 100% |
| 6 | Acue PID | 01 | Ectopic gestation | 01 | |

Volume : 5 | Issue : 6 | June 2015 | ISSN - 2249-555X

**SUMMARY & CONCLUSIONS**

First trimester vaginal bleeding is fairly a common complaint encountered in clinical practice. Ultrasonography is a safe , valuable non invasive tool to clinch the diagnosis . It also complements the clinical evaluation.

In the present study, various types of abortions constituted the commonest cause for vaginal bleed. Confirmation of abnormal & nonviable pregnancies by ultrasound fecilitated early institution of appropriate treatment thereby lessening the physical & psychological morbidity for the patient. Complications like infection & future infertility could be avoided by suitable early effective treatment










