Original Research Paper

Volume-9 | Issue-7 | July - 2019 | PRINT ISSN No. 2249 - 555X

Pathology

IDIOPATHIC SCROTAL CALCINOSIS IN A NINETEEN YEAR MALE PATIENT: A CASE REPORT

Dr. Kanwardeep Kaur	Professor, Department of Pathology, GGSMC Faridkot
Dr. Manmeet Kaur*	Associate Professor, Department of Pathology, GGSMC Faridkot *Corresponding Author
Dr. Heena	Senior Resident, Department of Pathology, GGSMC Faridkot
Dr. Parul	Junior Resident, Department of Pathology, GGSMC Faridkot

ABSTRACT Idiopathic calcinosis of the scrotum is a rare and benign disease of the scrotal skin. It is defined as the existence of multiple calcified and asymptomatic nodules of the scrotum skin wall that begin in childhood or adolescence and tend to increase in size and number. This disease was first described by Lewisnky as a subtype of calcinosis cutis. We present a case of 19 year old male presented to the OPD with complaint of scrotal swelling of five months duration. The disease presents as slow-growing yellowish nodules in the scrotum, single to multiple in numbers, with varying sizes. Hicheri et al. reported rapidly evolving variant which occurred within 3 months.

KEYWORDS : Idiopathic scrotal calcinosis, scrotal swelling

INTRODUCTION

Idiopathic calcinosis of the scrotum is a rare and benign disease of the scrotal skin. It is defined as the existence of multiple calcified and asymptomatic nodules of the scrotum skin wall that begin in childhood or adolescence and tend to increase in size and number. It is more common in dark coloured race.[1] This disease was first described by Lewisnky as a subtype of calcinosis cutis.[2] The pathogenesis of scrotal calcinosis is still controversial. It could be truly idiopathic as suggested by Shapiro et al[3] or it could be due to dystrophic calcification following calcium deposition on epidermal cysts according to Karabulut et al.[4]

CASE REPORT

A 19 year old male presented to the OPD with complaint of scrotal swelling of five months duration. There was no history suggestive of trauma or inflammation to the scrotum. Biopsy was done and sent to the pathology department for histopathological examination. Gross appearance showed a nodular mass with the cut section revealing chalky white areas. Microscopic examination revealed presence of calcium deposits within the dermis surrounded by foreign body type granulomatous reaction.(Figure 1 & 2)



Figure 1

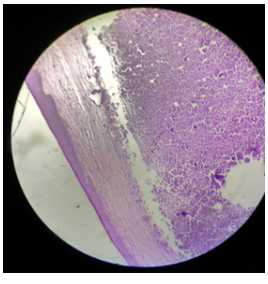

Figure 2

Figure 1 (40X) & 2 (100X) Microscopic examination revealed presence of calcium deposits within the dermis surrounded by foreign body type granulomatous reaction.

DISCUSSION

The disease presents as slow-growing yellowish nodules in the scrotum, single to multiple in numbers, with varying sizes. Hicheri et al. reported rapidly evolving variant which occurred within 3 months[5], the disease usually takes an indolent course, developing over several years. Most patients are asymptomatic and present because of cosmetic concern. Few patients may present with pruritis, ulcerations, and discharge of chalky material with occasional sumperimposed secondary bacterial infection.

ISC is a clinical and histological diagnosis. Clinical diagnostic confusion may arise from other scrotal calcified onchocercoma[6], solitary neurofibromas, ancient schwannomas, steatomas, lipoma and fibroma. The size, number, skin surface, and age of onset hint toward ISC, while confirmation is always done on histopathology.

Pathogenesis still remains elusive and continues to be debated. Carson highlighted the possible role of nonbacteria in extraskeletal calcifications.[7] Pabuccuglu et al speculated that the degeneration and necrosis of dartos muscle played a prominent primary role in the etiopathogenesis of ISC following which dystrophic calcification occurred.[8] Ito and colleagues proposed that scrotal calcinosis originates from eccrine epithelial cysts and the pathogenic mechanism seems to be the excessive discharge and accumulation of material debris in the lumina.[9]

Although there is no consensus about the pathogenesis of this condition, the only treatment recommended is surgical. Indeed, surgical management cures the aesthetic disorder and enables the confirmation of the diagnosis of ISC on histologic examination. Therefore, surgical excision must be limited to the scrotal skin because the calcified nodules are localized in the dermis.[10]

The risk of recurrence is also controversial, and some authors insist on the high probability of recurrence after primary excision.[10] The surgical approach must be perfect and the extent of excision must include the whole lesion, even the smallest ones to avoid rapid recurrence.

CONCLUSION

Although, the pathogenesis and basic origin of SC remains controversial, surgical management is the gold standard treatment for this disease and it also enables the confirmation of diagnosis on histopathology as it is both clinical and histologic diagnosis.

REFERENCES

1. B.Noel, C. Bron, N. Kunzle, M. De Heller, R. G. Panizzon. Multiple nodules of the scrotum: histopathological findings and surgical procedure. A study of five cases. Journal of the European Academy of Dermatology and Venereology. 2006;20(6): 707-10.
2. Lewinski HM. Lymphangiome der Haut mit Verkalklem Inhalt. Arch Pathol Anat. 1883;91:371–4.
3. Shapiro L, Platt N, Torres-Rodriguez VM. Idiopathic calcinosis of the scrotum. Arch Dermatol. 1970;102(2):199-204.

4. Karabulut YY, Kankaya D, Senel E, Dolek Y, Uslu A, Sertcelik A. Idiopathic scrotal calcinosis: the incorrect terminology of scrotal calcinosis. G Ital Dermatol Venerol. 2015; 150(5):495-9.
5. J. Hicheri, T. Badri, B. Fazaa et al. Scrotal calcinosis: Dystrophic calcification of epidermoid cyst. Archives of Dermatology. 2005;14(2):53-6.
6. S.G. Browne. Calcinosis circumscripta of the scrotal wall, the etiologic role of onchocerca vulvulus. British Journal of Dermatology. 1962;74:136-40.
7. D. A. Carson. An infectious origin of extraskeletal calcification, Proceedings of the National Academy of Sciences of the United States of America. 1998; 95(14): 7846–7.
8. Yusuf SM, Uloko AE, Sani MU, Mijinyawa SM, Mohammed AZ. Idiopathic scrotal calcinosis; a rare scrotal tumor: a case report and review of literature. Niger J Med. 2010;19(4):482-4.
9. Ito A, Sakamoto F, Ito M. Dystrophic scrotal calcinosis originating from benign eccrine epithelial cysts. Br J Dermatol. 2001;144:146-50.
10. Ruiz-Genao DP, Rios-Buceta L, Herrero L, et al. Massive scrotal calcinosis. Dermatol Surg.2002;28:745-47.