Original Research Paper

Volume-9 | Issue-7 | July - 2019 | PRINT ISSN No. 2249 - 555X

Gastroenterology

MEDIAN ARCUATE LIGAMENT SYNDROME: TREATMENT AND OUTCOME

Dr Sharvari Pujari	Assistant Professor Department of Surgical Gastroenterology, Seth GS Medical College & KEM Hospital, Parel, Mumbai-12
Dr Kishor Jain	Senior Resident. Department of Surgical Gastroenterology, Seth GS Medical College & KEM Hospital, Parel, Mumbai-12
Dr Rahul Raghavapuram	Senior Resident Department of Surgical Gastroenterology, Seth GS Medical College & KEM Hospital, Parel, Mumbai-12
Dr Ramkrishna Prabhu	Associate Professor Department of Surgical Gastroenterology, Seth GS Medical College & KEM Hospital, Parel, Mumbai-12
Dr Chetan Kantharia*	Professor and Head Department of Surgical Gastroenterology, Seth GS Medical College & KEM Hospital, Parel, Mumbai-12 *Corresponding Author

ABSTRACT **Introduction:** Median arcuate ligament syndrome is a symptom complex occurring following compression of celiac artery (CA) by a fibrous arch. This fibrous arch originates from the diaphragmatic crura on either side of the aortic hiatus and passes superior to the origin of the celiac axis. The symptom complex comprises of chronic postprandial abdominal pain, weight loss, nausea and vomiting. The diagnosis is essentially clinical, confirmed on CECT Scan which showing focal narrowing at the proximal celiac axis. Surgical release of the compression (laparoscopic or open) is the treatment of choice. However a select group of patients respond well to conservative treatment as well. Although there are several case reports and series in literature, very few studies outline the management strategy. The present study outlines the management protocol and also the follow-up of the outcome of treatment.

Material and Methods: A retrospective analysis of a prospectively maintained database at the Surgical Gastroenterology Department of a tertiary referral Public Hospital was performed for the period January 2010 until December 2017. Patients with celiac artery compression syndrome were identified and their records analyzed. The parameters studied were their demographics, clinical presentation, diagnostic investigations, the treatment offered, its outcome and the follow-up progress.

Results: Eight patients (5 males) were identified during the study period. The mean age was 26 years. Six patients were treated surgically (5 Laparoscopic and 1 open). Surgery comprised of division of median arcuate ligament division and celiac ganglion neurolysis.2 patients who did not consent for surgery were treated symptomatically. Mean follow-up was 39.2 months. Patients treated surgically improved symptomatically with no patient having recurrence of symptoms. Conclusion: Surgery is an effective treatment for celiac artery compression syndrome. Both open and laparoscopic approaches are safe with same outcome

KEYWORDS : Median arcuate ligament syndrome, coeliac artery, release of compression

INTRODUCTION:

Median arcuate ligament syndrome is a symptom complex characterized by a triad of symptoms comprising of chronic postprandial abdominal pain, weight loss and epigastric bruit. The syndrome occurs due to a low insertion of the median arcuate ligament (MAL) of the diaphragm, which forms a fibrous arch, and crosses the aorta cephalad to the proximal portion of the celiac artery. This results in extrinsic compression and narrowing of the celiac artery. Various treatment modalities including arterial bypass surgery and percutaneous transluminal angioplasty (PTA) [(1)] and stenting of the Celiac artery have been described. However surgical decompression by the division, of the anomalous fibrous diaphragmatic bands overlying the Celiac artery, along with the celiac plexus and lymphatic tissues is the treatment of choice.[(2)]The present study underlines the management protocol and the outcome of the surgical treatment.

MATERIAL AND METHODS:

The present study is a retrospective analysis of a prospectively maintained database at the Surgical Gastroenterology Department of a tertiary referral Public Hospital. Patients presenting with a diagnosis of celiac artery compression syndrome from January 2010 until December 2017 were identified and their records analyzed. The parameters studied were their demographics, BMI, clinical presentation, diagnostic investigations, the treatment offered, its outcome and the follow-up progress.

Surgery comprised of division of median arcuate ligament division and celiac ganglion neurolysis Conservative treatment was given in form of Proton Pump Inhibitor, with analgesic as and when required.

Outcome was assessed in terms of pain relief and weight gain. Pain relief was assessed as per Liekarts pain score [(3)] pre and post treatment.

Weight gain was considered significant if the gain was more than 5 kg.

Statistical analysis of the data obtained was done using Microsoft Excel 2007® and SPSS 16®.

RESULTS:

A total of eight patients were identified to have presented with celiac artery compression syndrome. Of these five were male. The age of these patients ranged from 16-32 years with mean of 26 years of age. Their BMI ranged from 17-25 kg/m^2 with median of 19.5 kgm^2 Pain and weight loss were the common presenting complaints with pain being present in all patients and weight loss being in 62.5% (5/8 patients).

CECT Scan confirmed the clinical diagnosis in all the patients.

6 patients were subjected to surgery. This was done laparoscopically in 5 patients while open surgery was performed in one patient.

Conservative treatment was instituted in two patients All patients managed surgically had good pain relief, and weight gain as compared to those treated conservatively, who had episodes of pain off and on and inconsequential gain in weight. The results of the patients are as given in Table I.

Follow Up period ranged from 8 months to 93 months with median of 36 months.

DISCUSSION:

Lipshutz[4] in 1917 first described an anatomic fibrous structure causing compression of coeliac axis.Harjola[5] in 1963, and Dunbar et al in 1963[6] ascribed its symptoms of postprandial pain, nausea, vomiting and

weight loss, and described it as a clinical syndrome. Hence it is also called as celiac axis compression syndrome or Dunbar syndrome.

A fibrous arch originating from the diaphragmatic crura on either side of the aortic hiatus is found to be passing superior to the origin of the celiac axis, causing compression of celiac artery. A debate persists, as to whether chronic ischemia following compression of the coeliac artery is the only cause of pain, or there are other factors also playing a role. There are two theories postulated explaining the cause of pain. One is the steal phenomenon, in which pain is attributed to the mesenteric ischemia following postprandial steal via collaterals from the superior mesenteric artery.[7]The second implicates pain to be neurogenic in origin, occurring following compression and intermittent ischemia of splanchnic nerve plexus [8]. The pain may be due to chronic irritation of the celiac plexus leading to splanchnic vasoconstriction and ischemia[2]. Besides Splanchnic nerve plexus is an autonomic nerve plexus which innervates upper abdominal organs. This is located in front of diaphragmatic crura around the origin of CA and SMA [9] giving rise to pain.

Though the clinical features of this syndrome may vary[10, 11] the symptoms essentially comprises of chronic postprandial abdominal pain, nausea, vomiting and weight loss. The pain is classically aggravated on full expiration. Presence of an audible epigastric bruit is pathognomic. In the present study too, post prandial abdominal pain is the presenting complaint in all patients, and weight loss in 62.5%

Diagnosis of this syndrome poses a great challenge[4] .It is essentially clinical and is diagnosed through exclusion.3 It is very important to correlate the patient's clinical history and the findings of imaging to make an accurate diagnosis [12]. There has been a paradigm shift in the modality of imaging being used to make diagnosis of this syndrome. From Invasive conventional angiography [2] being done until recent past, Duplex Ultrasound [13], CT[14] and MR angiography with 3-D reconstruction are being used in recent times with success. In our present study CT Scan was done in all the eight patients to confirm the clinical diagnosis of the Median arcuate ligament syndrome.

Treatment varies from conservative treatment, to balloon angioplasty and Surgery. Conservative treatment comprises of dietary restrictions and pharmacological therapy to improve gastric motility. There have been conflicting reports with regards to the success of conservative treatment. While studies from Taiwan by Jen-Wei et al[10] reported poor results with conservative treatment, Kusunoki et al [15] and Kiichiro et al [16] have in two separate case reports shared their successful experience with conservative reports. In our study the two patients treated conservatively, though they did get temporary symptomatic relief, they experienced repeated episodes of abdominal pain. Besides none of the patients gained weight.

Balloon angioplasty, as a modality of treatment for MAL syndrome, has been practiced by some. However literature evidence does not support the use of balloon expendable stents[17]. This is due to the fact that MAL syndrome occurs following external compression, and it cannot be tackled by intraluminal dilatation. However balloon angioplasty does have some role in patients with recurrence of symptoms post surgery [18].

Surgery remains the mainstay treatment of MAL syndrome. It not only offers long term pain relief but also results in weight gain. There have been various case reports and case series in literature reporting successful outcome following surgery [19,20,21]. The principle of surgery is to relieve external compression to the celiac axis, by dividing the anomalous fibrous diaphragmatic bands overlying the celiac axis. Though traditionally done by an open method, of late a laparoscopic approach is being practiced and advocated by many [21]. Laparoscopy is associated with no morbidity and mortality and has decreased in hospital stay. Although the reported conversion rate to open surgery is 20%, the rate of symptom recurrence between laparoscopic and open surgical decompression remain the same [22]. In the present study too, of the 6 patients operated, 5 were managed laparoscopically. All patients had pain relief and significant weight gain, with the longest follow up being 93 months and no patient having episode of recurrence.

CONCLUSION:

Surgery in form of relieving of external compression to the celiac axis, by dividing the anomalous fibrous diaphragmatic bands overlying the celiac axis is an effective treatment for Median Arcuate Ligament syndrome. Both open and laparoscopic approach is effective and safe offering long term relief of abdominal pain and weight gain.

TABLE: 1 Characteristics and Outcome of Treatment of patients with Median Arcuate Ligament Syndrome.

Parameters	P1	P2	P3	P4	P5	P6	P7	P8
Sex	M	F	F	M	M	F	M	M
Age	32	16	27	25	18	28	30	22
BMI	23	17	18	25	20	19	21	18
Pain	Y	Y	Y	Y	Y	Y	Y	Y
Weight Loss	N	Y	Y	N	Y	Y	N	Y
CECT Scan	Y	Y	Y	Y	Y	Y	Y	Y
Treatment	Open Surgery	Lap Surgery	Lap Surgery	Lap Surgery	Conservative	Conservative	Lap Surgery	Lap Surgery
Pain score before treatment	8	9	8	8	6	5	9	8
Pain score after treatment	0	0	1	0	4	4	0	1
Weight Gain	NA	+++++ >5Kg	+++++ >5Kg	+++++ >5Kg	+/- 1kg	+/- 3 kg	+++++ >5Kg	+++++ >5 Kg
Follow Up period in months	93	78	56	41	31	24	19	8

Pre-operative CECT Scan of a patient of MAL Syndrome subjected to Surgery

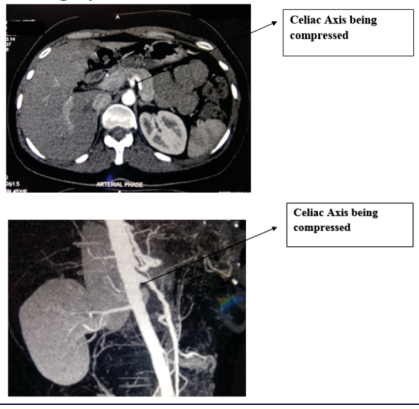

Post Operative CECT Scan at end of three months of a patient following Laparoscopic decompression of MAL

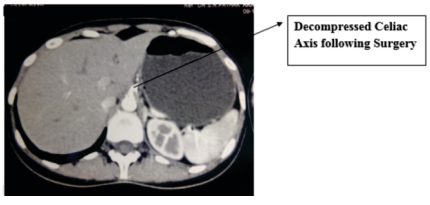

REFERENCES

1. Saddekni S, Sniderman KW, Hilton S, Sos TA. Percutaneous transluminal angioplasty of nonatherosclerotic lesions. AJR Am J Roentgenol. 1980;135:975–982
2. Duffy AJ, Panait L, Eisenberg D, Bell RL, Roberts KE, Sumpio B. Management of median arcuate ligament syndrome: a new paradigm. Ann Vasc Surg. 2009; 23:778–784.
3. Kremer E, Atkinson JH, Ignelzi RJ. Measurement of pain: patient preference does not confound pain measurement. Pain.1981 Apr; 10(2):241-8.
4. Lipshutz B. A composite study of the coeliac axis artery. Ann Surg. 1917;65:159–169
5. Harjola PT. A rare obstruction of the coeliac artery: report of a case. Ann Chir Gynaecol Fenn. 1963;52:547–550

6. Dunbar JD, Molnar W, Beman FF, Marable SA. Compression of the celiac trunk and abdominal angina. Am J Roentgenol Radium TherNucl Med. 1965;95:731–744
7. Chou J−W, Lin C−M, Feng C−L, et al. Celiac artery compression syndrome: an experience in a single institution in Taiwan. Gastroenterol Res Pract. 2012;2012:1–6.
8. Skeik N, Cooper LT, Duncan AA, Jabr FI. Median arcuate ligament syndrome: a nonvascular, vascular diagnosis. Vasc Endovascular Surg. 2011;45:433–437
9. Petrella S, Prates JC. Celiac trunk compression syndrome: a review. Int J Morphol. 2006;24:429–436.
10. Chou J−W, Lin C−M, Feng C−L, et al. Celiac artery compression syndrome: an experience in a single institution in Taiwan. Gastroenterol Res Pract. 2012;2012:1–6
11. Scholbach T. Celiac artery compression syndrome in children, adolescents, and young adults: clinical and color duplex Sonographic features in a series of 59 cases. J Ultras Med. 2006;25:299–305.
12. Kazan V, Qu W, Al−Natour M, et al. Celiac artery compression syndrome: a radiological finding without clinical symptoms?Vascular. 2013;21:293–9
13. A. Erden, M. Yurdakul, T. Cumhur. Marked increase in flow velocities during deep expiration: a duplex Doppler sign of celiac artery compression syndrome. Cardiovasc Intervent Radiol, 22 (1999), pp. 331-332
14. Paolo Baccari, Efrem Civilini, Laura Dordoni, Germano Meliissano, Robert Nicole, Robert Chiesea. Celiac artery compression syndrome managed by laparoscopy. Journal of Vascular Surgery. Volume 50, Issue 1, July 2009, Pages 134-139.
15. Kusunoki H, Tsutsui T, Tsukamoto M, et al. A case of celiac artery Compression Syndrome in which gastro−duodenal motility was sequentially assessed over the follow−up period. Kawasaki Med J. 2013;39:169–76.
16. Kiichiro Yoshida, Keiichiro Kita, and Seiji Yamashiro. A 56−year−old female with celiac artery compression syndrome recovering through dietary changes and weight gain. J Gen Fam Med. 2017 Aug; 18(4): 165–167.
17. Gloviczki P, Duncan AA. Treatment of celiac artery compression syndrome: does it really exist? Perspect Vasc Surg Endovasc Ther. 2007; 19: 259-263.
18. Cinà CS, Safar H. Successful treatment of recurrent celiac axis compression syndrome: a case report. Panminerva Med. 2002;44:69–72.
19. Sang Jin Kim,Yang Jin Park, Shin-Seok Yang and Young-Wook Kim. Open surgical decompression of celiac axis compression by division of the median arcuate ligament. J Korean Surg Soc. 2013 Aug; 85(2): 93–95.
20. Kohn, G. P., Bitar, R. S., Farber, M. A., Marston, W. A., Overby, D. W., & Farrell, T. M. (2011). Treatment options and outcomes for celiac artery compression syndrome. Surgical Innovation, 18(4), 338-343.
21. Paolo Baccari, Efrem Civilini, Laura Dordoni, Germano Melissano, Roberto Nicoletti and Roberto Chiesa. Celiac artery compression syndrome managed by laparoscopy. Journal of Vascular Surgery. Volume 50, Issue 1, July 2009, Pages 134-139.
22. Tulloch AW, Jimenez JC, Lawrence PF, Dutson EP, Moore WS, Rigberg DA, et al. Laparoscopic versus open celiac ganglionectomy in patients with median arcuate ligament syndrome. J Vasc Surg. 2010;52:1283–1289.