Original Research Paper

Volume-9 | Issue-7 | July - 2019 | PRINT ISSN No. 2249 - 555X

ENT

NASOPHARYNGEAL CYST OF BRANCHIOGENIC ORIGIN: A CASE REPORT

Dr Harjitpal Singh* Asstt Prof (ENT), Dr RadhakrishnanGovt Medical College, Hamirpur(HP)
*Corresponding Author

Prof N K Mohindroo HOD (ENT) SLBS Govt Medical College,Mandi(HP)

ABSTRACT Nasopharyngeal cysts are not completely understood. They are classified according to their localization and pathogenesis in congenital or acquired and medial or lateral. We present a rare branchial cyst of the nasopharynx in a 21-year-old man. The cyst was located on the left lateral wall of the nasopharynx, and was removed by transoral approach.

KEYWORDS : Nasopharyngeal cyst, Branchiogenic, Transoral.

INTRODUCTION

Branchial cleft cysts of the nasopharynx are rare[1]. Derived from the first and dorsal portions of the second branchial pouches are located on the lateral walls of the nasopharynx. These cysts are usually paired. Embryogenic cysts of the pharyngeal bursa and Rathke's pouch are usually located in the midline. What differentiates these internal branchial cysts from other cysts of the first, second, third, and fourth branchial arches is the fact that they form only in the pharynx and they do not produce any neck swelling.

In this article, we present a case of branchial cyst of the nasopharynx that was located at the lateral wall of nasopharynx and was successfully treated surgically via the transoral route.

Case report

A 21-year-old man complained of difficulty in nasal breathing and mass in throat of one & half months' duration. There was history of frontal headache on and off. There was no other significant relevant history. Examination revealed a well-circumscribed whitish mass in the nasopharynx (Fig.1). The mass was covered with mucous membrane and dilated blood vessels and was attached to the poster lateral aspect of the nasopharynx on the left side. It extended from the roof of the nasopharynx superiorly to below the tip of uvula on its left side. Medially, the mass crossed the midline; laterally, it was attached to the lateral nasopharyngeal wall at the lateral pterygoid plate region. No signs or symptoms of Eustachian tube blockage were there. On palpation, the mass was cystic in its consistency. It was mobile.



Fig.1

CT scan (Fig 2) revealed an oval mass of size 3.05x2.07 cm arising from left lateral wall of nasopharynx and protruding into nasopharyngeal cavity. Wall of cystic mass was thin and smooth. No calcification was noticed. There was no bony erosion or intra cranial extension. After I/V contrast, wall showed enhancement but there was no enhancement of central contents.

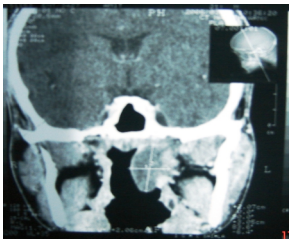

Fig 2

In our patient, we were able to excise the cyst transorally under direct vision. We believe that this cyst was branchiogenic in origin and that it arose from the second branchial arch at the lower level. Histopathological findings revealed a branchial cyst lined with stratified squamous epithelium. A sub mucosal layer contained lymphoid follicles, mono-nuclear inflammatory cells, and goblet cells. There was no recurrence even after 2 years of follow up.

DISCUSSION

Nasopharyngeal cysts of branchial origin can develop at any point along an imaginary line drawn from the upper pole of the tonsil and behind the eustachian tube orifice (the so-called lower-level cysts) and along Rosenmuller's s fossa and medially and slightly forward of the midline of the nasopharyngeal vault (upper-level cysts).

Because the cyst in our patient was attached to the lateral nasopharyngeal wall and extended from the roof of the nasopharynx to the tip of uvula, it was classified as a lower-level lesion.

The precise embryologic pathogenesis of pharyngeal cysts of branchial origin is not well understood. The difference in epithelial linings (respiratory or squamous) and the presence of lymphoid tissue in the subepithelial plane make it difficult to determine whether these cysts are endo- or ectodermal. According to the branchial apparatus theory, type IV cysts arise from a remnant of an internal pharyngeal duct, which would indicate that they are endodermal[2]. However Wild et al[3] postulated that these cysts are derived from ectopic epithelial cells in the regional lymph nodes and are therefore ectodermal.

In their study of 22 cases of nasopharyngeal cysts of branchial origin, Verma A[4] et al has observed that all cysts but one were located in relation with the upper part of the posterior pillar of the tonsil. In light of this finding, it is presumed that these cysts usually arise from the second branchial arch.

Plaza Mayor G[5] et al have classified nasopharyngeal cysts according to their localization and pathogenesis in congenital or acquired and medial or lateral. They postulated that all but the asymptomatic one should be operated transorally, by grasping the cyst and its implantation site.

Tamagawa Y et al[6] have done endonasal resection of the cyst which was located at the higher level between the roof and the left lateral band of the nasopharynx. This was preceded by a preparatory septoplasty. They recommend this procedure over the transpalatal approach because it is less invasive and maintains the normal anatomy of the palate

Alarcos Tamayo E et al[7] have done excision nasopharyngeal cyst using a transpalatine approach. Shidara K[8] also used transpalatal approach and observed that it is better for cysts at the upper level. According to Dilkes MG[9] et al the transoral surgical approach provides better access to cysts at the lower level.

More recently, Tsai T Y[10] has described transoral marsupialization as an effective method of managing nasopharyngeal branchial cysts. In the case series of three patients, with a follow-up ranging from 8 to 40

months, no recurrences were reported. When compared with complete excision, the authors considered this technique to offer benefits of being less invasive, offering less functional loss and cosmetic deformity to the patients, and being associated with a shorter hospitalization.

Verma A[4] et al has reported various treatment modalities : of the 22 patients, 18 underwent surgical excision. Two patients underwent aspiration only, and two others were treated with aspiration plus injection of 1 ml of a 5% aqueous solution of ethanolamine oleate as a sclerosing agent. There were no reports of any recurrence.

REFERENCES:

1. Paparella: Volume III: Head and Neck Section 2: Disorders of the Head and Neck
2. Maran AG. Benign diseases of the neck. In: Kerr AG, ed. Scott-Brown's Otolaryngology. Vol. 5, 5th ed. London: Butterworths, 1987:287.
3. Wild G, Mischkc D, Lobeck H, Kastenbauer E. The lateral cyst of the neck: Congenital or acquired? Acta Otolaryngol 1987;103:546-50.
4. Nasopharyngeal cyst of branchiogenic origin: Report of a case and review of the literature. Ear Nose Throat J. 2000 Sep;79(9):722-4, 726, 730-1. Verma A, Sohail MA, al-Khabori M, Moosa M.
5. Nasopharyngeal cysts. Report of four cases and literature review. An Otorrinolaringol Ibero Am. 1999;26(6):607-19. Plaza Mayor G, Martinez San Millan J, Barbera Duran R, Perez Martinez C, Folgue Calvo L, Denia Lafuente A.
6. Branchial cyst of the nasopharynx: resection via the endonasal approach.J Laryngol Otol. 1995 Feb;109(2):139-41.Tamagawa Y, Kitamura K, Miyata M.
7. Congenital cysts of the nasopharynx. Report of a case. Acta Otorrinolaringol Esp. 1997 Jun-Jul;48(5):409-12. Alarcos Tamayo E, Morais Perez D, Alarcos Llorach A, Sierra Roman JM, Perez Gonzalez R.
8. Shidara K, Uruma T, Yasuoka Y, Kamei T. Two cases of nasopharyngeal branchial cyst. J Laryngol Otol 1993;107:453-5.
9. Dilkes MG, Chapman J, Stafford ND. Per-oral excision of a branchial cyst. J Laryngol Otol 1990;104:143-4.
10. Tsai T Y, Su C Y. Surgical technique of transoral marsupialization for the treatment of nasopharyngeal branchial cysts. Ann Otol Rhinol Laryngol. 2010;119:336–341.