Original Research Paper

Volume-9 | Issue-7 | July - 2019 | PRINT ISSN No. 2249 - 555X

Paediatrics

PAEDIATRIC OVARIAN TORSION

Dr. Mohan Professor of Paediatric surgery, Department Of Paediatric Shri Sathya Sai Medical College & Research Institute, Ammapettai 603108

Dr. Paramanantham. P* Professor of Paediatrics, Department Of Paediatric Shri Sathya Sai Medical College & Research Institute, Ammapettai 603108 *Corresponding Author

ABSTRACT

BACKGROUND: Abdominal pain in children is very challenging.
PATIENT CHARACTERISTIC: 11 years old girl presented with abdominal pain. Clinical examination and abdominal ultrasound we diagnosed as ovarian torsion.
INTERVENTION: As the patient presented late, we could not salvage her ovary.
MESSAGE: Presentation is to highlight the early diagnosis and emergency management.

KEYWORDS : Torsion ovary; Appendicitis; Abdominal pain

CASE REPORT:
11 years old Female came for pain in the abdomen 3 days, Vomiting 8 times a day, Came to Paediatric OP

History of presenting illness: Abdominal pain is sudden in onset, in the right lateral quadrant, intermittent, colicky type, non-radiating and relieved on sitting position. H/o pain during & after micturition. Vomiting is non-projectile & greenish in color. No H/O fever, change in color of stool or bowel habits. The patient had a similar complaint previously and they visited 3 times earlier for doctor's opinion outside. No previous H/O admission in the hospital or any previous surgery.

Not a known case of seizure, Bronchial asthma, drug or food allergy. 11 year old female, not attained menarche.

Patient was referred to paediatric surgeon for opinion Patient was referred to Gynecology to rule out any pelvic pathology, but they felt there is no gynecological cause for abdominal pain and to rule out appendicitis.

On Examination: Severe pain of abdomen, a febrile, No pallor

Vitals: HR: 99/min RR: 22/min BP: 90/60 mmhg

Systemic Examination: Per Abdomen: Tenderness & Guarding present in the Right lower quadrant & also in the supra pubic region.

Investigations done
1. Abdominal USG: Enlarged, left ovary with multiple follicles and minimal peripheral vascularity suggestive of left ovarian torsion. Minimal free fluid in the Cul De Sac.
2. Urine routine, culture and all other hematological parameters were normal, Blood group B positive.

In view of the clinical picture and ultrasound finding, a diagnosis of ovarian torsion was thought of. Hence patient was posted for emergency laparotomy Pfannistiel incision is made .Layers opened one by one.

Peritoneum was opened. Bowels are safely guarded. Intra-abdominal inspection done. Left-sided torsion ovary identified and it was found to be black in color and non-viable. Right side ovary is normal. Left sided salpingo-oophorectomy performed after ligating ligaments with free silk 2.0. Infundipubo pelvic ligament transfixed with Silk 2.0. Thorough saline wash given. Abdomen inspected once more. No bowel or bladder pathology seen. Abdomen closed in layers after achieving thorough haemostasis. Dressing applied. Regular post-operative feed is given along with I.V antibiotics.

Post Surgical recovery: Uncomplicated child discharged on 3rd post operative day with advice to follow up

Etiology & Risk factors: Adnexal torsion involves ovary, fallopian tube or both. Isolated fallopian tube torsion is uncommon in any age group. Venous blood flow is the first to be impaired followed by compromised arterial blood flow. The duration of ischemia required to cause and irreversible damage is not known, adnexal torsion involves right adnexa more often (66%) than the left adnexa[2]

Clinical Presentation: The diagnosis of adnexal torsion is challenging.

Adnexal torsion presents with acute, unilateral, lower abdominal pain[4]. Pain is most frequently stabbing (70%), sharp (60%)[5]. The pain can be intermittent possibly related to partial torsion with spontaneous reversal. Nausea and vomiting are common and reported in 60%-70% of patients. Fever may be present in 10% of patients, usually a late finding resulting from the presence of necrotic tissue[6]. A palpable mass on physical examination is reported in 60% of adults 20%-36% in children.

Peritoneal signs are rare, findings 3%-27%.[7]

Investigations:
Imaging: B mode USG is the imaging modality of choice for patient suspected of adnexal torsion. USG, more sensitive and specific investigation. Ovarian Enlargement & the absence of Doppler flow[10] is diagnostic Significant adnexal asymmetry is specific. Adnexal volume ratio of > 20ml (volume of affected ovary/volume of unaffected ovary) is associated with adnexal torsion. CThas low sensitivity & is not recommended for the work up of suspected adnexal torsion. MRI may prove useful in ruling out the other causes of lower abdominal pain

Management: Diagnosis of ovarian torsion require clinical awareness and high degree suspicion, conservative surgery, in the form of ovarian detortion can be tried in case of ischemic ovary before ovarian necrosis occur. Salpingo-oophorectomy as a last resort. The risk of thrombo embolic event following detorsion is unfounded.

Laparoscopy is preferred for surgical approach. Intravenous fluorescent can be used to confirm adequate perfusion.

A prompt diagnosis and referral to a paediatric surgeon to minimize trauma and ischemia to the ovary. When torsion is suspected surgeries to be preferred as soon as possible. Oopheroprexy can be considered in situations when ovarian ligaments are congenitally long. Prophylactic fixation of the opposite normal ovary is controversial.

Figure of a patient, normal ovary gone to Torsion

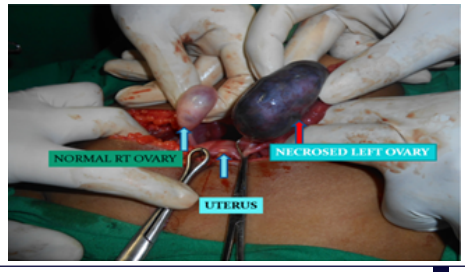

DISCUSSION:

Ovarian torsion & adnexal torsion is one of the acute paediatric surgical emergencies. Incidence of ovarian neoplasia is low in this age group. With advances in laparoscopic examination and routine use of fetal ultrasonography during pregnancy improved ante-natal diagnosis of several conditions including neonatal ovarian cysts are made.

Association of ovarian torsion is secondary to either neoplastic or benign cystic masses is a constant concern Adnexal torsion is likely to occur in children, adolescent, reproductive age women (average age 26 years) leading to potential detrimental effects on ovarian function and fertility.[11]

CONTRIBUTORS: PM helped in the revision of the manuscript and provided the photomicrograph PP collection of data, drafting of the manuscript and will act as the guarantor

Funding: None
Competing Interests: None stated

REFERENCES:

1. Anders JF et al, Urgency of evaluation and outcome of acute ovarian torsion in pediatric patients, Arch Pediatr Adolesc Med 2005;159:532-5
2. White M et al, Ovarian torsion, 10 year perspective. Emerg med Australas 2005;17:2317
3. Houry D, Abbott JT, Ovarian torsion: a fifteen year review, Ann emerg Med 2001;38:156-9
4. Kokosk ER et al, Acute ovarian torsion in children. Am J Surg 2000;180:462-5
5. Tsafrir et al, Risk factors, symptoms, and treatment of ovarian torsion in children: the twelve year experience of a center, J minim invasive gynecol 2012;19(1):83-6
6. Reed JL et al, Biomarkers to distinguish surgical etiologies in females with lower quadrant abdominal pain, Acad Emerg Med 2011;18:686-91
7. Fleischer AC, Brader KR, sonographic depiction of ovarian vascularity and flow, current improvements and future applications. J Ultrasound Med 2001;20:241-50
8. Shadinger LL et al, Preoperative sonographic and clinical characteristics as predictors of ovarian torsion, J Ultrasound Med 2008; 27(1); 7-13.
9. P.Anthony Decker et al, Laparoscopic Diagnosis and Management of Ovarian Torsion in the Newborn, Division of pediatric surgery, children's hospital of Wisconsin, JSLS 1999;3:
10. Vineet Mishra, Shaheen Hokabaj, Priyankur Roy et al. a case series of paediatric adnersal torsion: rare yet urgent entity., International Journal of Reproduction, Contraception, Obstetrics and Gynecology 2017 Jan; 6(1):315-319